

# HISTOPATHOLOGICAL ASPECTS OF GIANT FIBRES IN SELECTED MUSCLES OF THE PIG

Makovický, P<sup>1\*</sup>, Makovický, Pa<sup>2</sup> and Chrenková, M<sup>3</sup>.

<sup>1</sup>Czech University of Life Sciences, Department of Veterinary Sciences, Kamýcká 129, 165 21 Prague 6 – Suchdol, Czech Republic.

<sup>2</sup>Slovak Agricultural University in Nitra, Department of Animal Husbandry, Tr. A. Hlinku 2, 949 76 Nitra, Slovak Republic.

<sup>3</sup>Research Institute for Animal Production, Institution of Nutrition, Hlohovská 2, 949 92 Nitra, Slovak Republic.

\*Corresponding author: Ing. Peter Makovický, PhD., Czech University of Life Sciences, Department of Veterinary Sciences, Kamýcká 129, 165 21 Prague 6 – Suchdol, Czech Republic. E-mail: pmakovicky@email.cz

## ABSTRACT

Different sizes and structural changes of muscle fibres occur as morphological changes in skeletal muscles. We describe here histopathological aspects of giant fibres in selected porcine muscles using light microscopy. Four stages are described for the histological grading of muscular fibre splitting, grades G1 to G4. We define four grades and describe the individual stages of splitting. This gradation is applicable in histopathology, and includes the initial to the final stage. Localisation of giant fibres, nuclei and changes in the quantity of *endomysium* during splitting are described. The average thickness of both normal and giant muscular fibres, and three muscles: *m. triceps brachii* (MTB), *m. longissimus dorsi* (MLD) and *m. rectus femoris* (MRF), are compared morphometrically. In conclusion the presentation of histopathological aspects obtained subjectively of giant muscle fibres is summarized and classified. On the basis of these results, we conclude that the average thickness of normal muscle fibres is lower than the average thickness of giant fibres.

**Keywords:** centronuclear myopathy, giant fibres, interstitial tissue, lipid cells, muscular fibres, pigs, skeletal muscle.

## INTRODUCTION

Skeletal muscle consists morphologically and functionally of muscular tissue, and comprises neural, connective tissue and vascular elements. Skeletal muscle is covered externally with *epimysium* or *perimysium externum*. Septa of interstitial connective tissue, or *perimysium internum* penetrate from this structure. The interstitial connective tissue septa divide the muscle into primary, secondary and tertiary bundles. The *endomysium* penetrates from the surface of the smallest primary bundles in the form of a fine network of reticular fibres which connect with the sarcoplasm of individual fibres and creates fine cases around them. The muscle fibre is the basic building unit of striated skeletal muscles, and can be characterised as parallel-ordered multinucleated cytoplasmatic structures (1,2). Part of the morphological changes of skeletal muscles includes differences in size and structure. From the functional and causal pathological aspect, the structural changes are multifocal in character and are regardless of class, but they may be used to define the type of fibre. Wohlfart (3,4) first described microscopically, “giant” hypertrophic fibres in muscle dystrophy of

newborns. The morphological changes of giant fibres as related to muscle function correspond to disorders in metabolism and primary degeneration of skeletal muscles (5). Giant fibres figure in a large group of nervous and muscular diseases (6,7). A recent study of giant fibres includes a wide spectrum of changes in the progression of some muscular diseases. Together with clinical symptomatology there are also related to biochemical, physiological and pathological changes (8,9). These works describe differences between normal and giant fibres and the the four phases in splitting of giant fibres. These classifications are not described elsewhere, but are necessary for histological studies. In order to study the manifestations of giant fibres, the domestic pig was selected, while other works have described giant fibres within a definitive pathological process. To compare our study with others, we describe four histological grades (G1 to G4), which can be applied histopathologically. The objective of this study is to describe the individual stages of muscular fibre splitting in pigs and to illustrate them by light microscopy.

## MATERIALS AND METHODS

### Animals

Thirty pigs of meat hybrids of both sexes were examined clinically. All pigs (n=30) were healthy. None was lame or had other signs of orthopaedic or muscular diseases. A standard feed mixture was fed ad libitum. At the end of the experiment, the animals were killed at an average live weight of  $100 \pm 5$  kg, aged  $162 \pm 11$  days.

### Sampling

Sections for histological examination were taken post mortem from the geometrical centre of the middle head *musculus triceps brachii* (MTB) laterocranially from the central tendon, from the middle of the *musculus longissimus dorsi* (MLD) at the position of the last rib, and from the geometrical centre of the *musculus rectus femoris* (MRF). All samples were taken from the right limb. Samples of 1 cm<sup>3</sup> were taken within 30 minutes of slaughter. They were identified, pinned to a cork plate by cross section side, wrapped in aluminium foil and were immediately frozen in liquid nitrogen. One sample was taken from each muscle, totalling 90 samples. The samples were fixed in liquid nitrogen and transported to a histochemical laboratory, where they were stored at  $-30^{\circ}\text{C}$ .

### Processing and evaluation of samples

Sections 10  $\mu\text{m}$  thick were cut in a freezing microtome at a temperature of  $-19^{\circ}\text{C}$  to  $-21^{\circ}\text{C}$ . All samples were cut on the cross-section of muscle fibres. The first series of samples was stained with translucent haematoxylin-eosin and the second series with toluidine blue. The preparations were evaluated subjectively in a light-microscopic picture. The average thickness of normal and giant muscular fibres in individual muscles was measured. The thickness of fibres was measured as the diameter length of fibres on the cross-sections. The criteria for distinguishing between normal and giant muscular fibres for measurement are presented in the subjective evaluation of the microscopic picture of the preparations. Ten fields in each section were randomly selected. All possible fibres in the samples were evaluated, and all measurements were performed using special laboratory microscope imaging with the software NIS-Elements. Subjective and objective evaluations were performed with the light microscope Nikon Eclipse E600. Distinctions among panels were tested using the SAS program with binary-test at the limit  $\alpha = 0.05$ .

## RESULTS

### Subjective description of fissuring of giant fibres

At the initial stage, the giant muscular fibres are located in individual muscle bundles near the *perimysium internum*; they are often centrally located, but they are mostly visible singly among other, normal ones, and never in groups. In

cross-section they are always spherical sarcoplasmically, characteristically dense with a homogeneous structure, without visible myofibrils, and are often vacuolated. *Endomysium* is quantitatively represented more around the giant muscular fibres (Fig. 1). This is stage G1. A shift of the nuclei of giant muscular fibres is characteristic of the stage of splitting; they migrate from under the sarcolemma in a central direction, either directly from the periphery to the centre or spiral-like, the latter being arranged in a catenulate way, and creating a splitting line of muscular fibre. It is possible to see the splitting line at the place of nuclei aggregation; in muscular fibres fissures arise at the place of splitting either in the centre of the fibre, or where they penetrate vertically from the periphery to their centre (Fig. 2, 3). This is stage G2. The terminal stage is accompanied by decomposition of giant muscular fibres into a number of smaller muscular fibres (Fig. 4). This is stage G3.

A newly created mass of tissue is characteristic of the final stage, where small muscular fibres arise that markedly resemble myocytes or myoid elements. Giant muscular fibres always appear larger in diameter than normal ones; however, the splitting of muscular fibres reaches in places an identical or smaller average size than that of normal muscular fibres (Fig. 5). This is stage G4.

### Objective evaluation of microscopic appearance of preparations

The average thickness of normal and giant muscular fibres in muscles MTB, MLD, MRF was assessed morphometrically in the preparations (Table 1). It was confirmed that the average thickness of normal muscular fibres is less than that of giant muscular fibres. The total average thickness of normal muscular fibres in pigs was  $95.79 \mu\text{m}$ . From similar measurement, it followed that the total average thickness of giant muscular fibres was  $140.36 \mu\text{m}$ . The difference equals  $44.57 \mu\text{m}$ . The average thickness of normal muscular fibres in MTB was  $90.44 \mu\text{m}$  and that of giant muscular fibres in MTB was  $130.79 \mu\text{m}$ , the difference was statistically highly significant ( $P < 0.001$ ). The average thickness of normal muscular fibres in MLD was  $88.11 \mu\text{m}$ , and of giant muscular fibres in MLD was  $143.50 \mu\text{m}$ ; this was statistically highly significant ( $P < 0.001$ ). The average thickness of normal muscular fibres in MRF was  $108.81 \mu\text{m}$ , and that of giant muscular fibres was  $146.77 \mu\text{m}$ , which was statistically highly significant ( $P < 0.001$ ). The results demonstrate that there is a statistically significant difference between the normal fibres of MLD and MRF ( $P < 0.01$ ).

**Table: Average thickness of muscle fibres.**

Muscle	No. of animals	Average thickness of normal fibres (µm).	Average thickness of giant fibres (µm).	Standard deviation
MTB	30	90,44	130,79	14,56
MLD	30	88,11	143,50	19,42
MRF	30	108,81	146,77	9,63
Sum	30	95,79	140,36	14,53

**MTB** – *m. triceps brachii*.

**MLD** – *m. longissimus dorsi*.

**MRF** – *m. rectus femoris*.

## DISCUSSION

The comparison of normal and giant muscular fibres shows a disproportion in their thickness when observed in light microscopy. This finding agrees with previous data (10,11). The light microscope image of the muscular fibre is characteristically disorganized and often vacuolized (12). Sosnicki (13) mentioned that giant muscular fibres are non-striated on a longitudinal section, some of them are without cytoplasmic organelles but have an increasing number of dark-coloured nuclei, which appear larger than in normal muscular fibres. Ferrer et al. (14) and Handel and Strickland (15) stated that these changes represent firstly hypertrophic, dense fibres of homogeneous structure and without visible myofibrils. According to Adams et al. (16), it is seen that they are oval in shape, and have a dense homogeneous sarcoplasm. Their thickness markedly exceeds that of normal muscular fibres. We demonstrate that they are mostly located in individual muscle bundles near the *perimysium internum*. However, they can also be localized more centrally (17,18). Sosnicki, (15) and Stephan et al., (19) state they are most often visible individually among other normal muscular fibres but almost never in groups.

Handel and Strickland (13) observed that giant fibres in pig muscles are present without pathological changes. According to Dubowitz (7), it is possible to encounter splitting of muscular fibres quite often in classical myopathology, such as in primary muscle disease and neurogenic atrophies. According to Carpenter and Karpathi (5), splitting of muscular fibres of larger diameters occurs in the cases of trophic disorders, for example as a result of the occurrence of primary myogenic or neurogenic lesions. We show that giant fibres are also present in healthy pigs, and demonstrate, there are some states in splitting fibres that have some common characteristics. According to Adams et al. (16),

the presence of giant fibres in combination with internal nuclei is connected with the splitting. Our observations show that muscle nuclei aggregate inside the sarcoplasm of giant fibres, and it is possible to observe them microscopically creating centrally catenulate band formations (20). According to Remignon et al. (21) and Fiedler et al. (22), fissures arise in muscular fibres at the place of splitting; they are localized either in the centre of the fibres or they penetrate vertically from the periphery to the centre. In preparations with longitudinal sections of muscular fibres, uneven, centrally localized fissures in giant muscular fibres maybe seen (23). However, in some places it can be seen that individual giant muscular fibres have already split into a number of smaller muscular fibres. Muscle nuclei are localized immediately under the sarcolemma in normal muscular fibres. In giant muscular fibres, they may be observed as sporadic or mass migration towards the centre of the muscular fibres (24,7). Taverna et al. (25) and Fazarinc et al. (8) mentioned not only the increasing number of internal nuclei but also an increase in the number of nuclei overall. In order to explain this phenomenon, authors started from the hypothesis that there exist biochemical disorders at the cytoplasmic level of the muscular fibre membrane (24). According to Ohlendieck (26) this complex stabilizes the sarcolemma during the contraction and relaxation of muscle. Mutations in one of the genes for dystrophin glycoprotein can cause partial or complete deficiency of the remaining sarcoglycans (9). A deficiency in the protein dystrophin can therefore be accompanied by the process of necrosis or apoptosis, the result of which is the splitting of muscular fibres (27,28).

## ACKNOWLEDGEMENTS

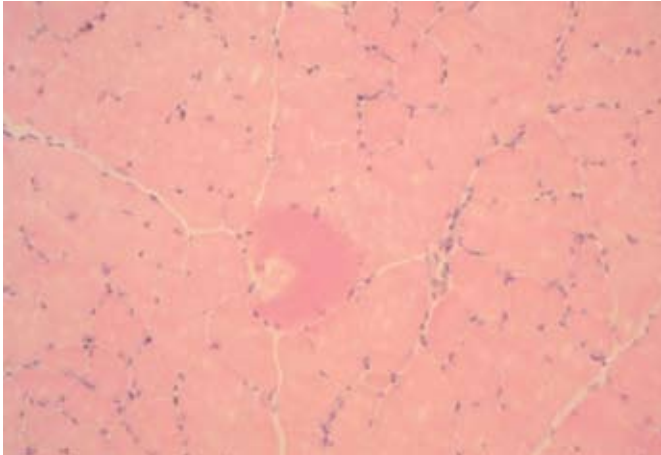
We thank Mrs. Lois Russell for her editorial help with this manuscript. This work was supported by grant MSM 6046070901.

## REFERENCES

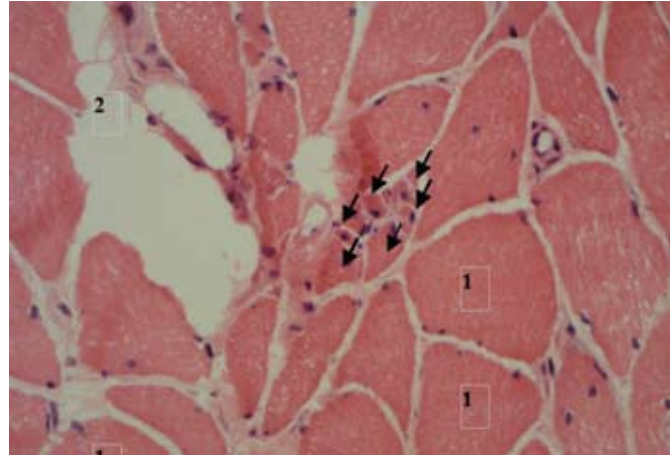
- Hoppeler, H. and Fluck, M.: Plasticity of skeletal muscle mitochondria: structure and function. *Med. Sci. Sports. Exerc.* 35, 95-104, 2003.
- Goldspink, G.: Muscle growth and muscle function: a molecular biological perspective. *Res. Vet. Sci.* 60, 193-204, 1996.
- Wohlfart, G.: Über das Vorkommen verschiedener Arten von Muskelfasern in der Skelettmuskulatur des Menschen und einiger Säugetiere. *Acta psychiat.* 13, 1-19, 1937.
- Wohlfart, G.: Muscular trophy in diseases of the lower motor neuron; contribution to the anatomy of the motor units. *Arch. Neurol. Psychiat.* 61, 599-620, 1949.
- Carpenter, S. and Karpati, G.: Pathology of skeletal muscle. Churchill and Livingstone, New York, 1984.
- Weiler, U., Appell, H. J., Kremser, M., Hofacker, S.

- and Glaus, R.: Consequences of selection on muscle composition – a comparative-study on gracilis muscle in wild and domestic pigs. *Anat. Histol. Embryol.* 24, 77-80, 1995.
7. Dubowitz, V.: *Muscle biopsy. A practical approach.* 2nd ed. Bailliere Tindall, London, 1985.
8. Fazarinc, G., Candek-Potokar, M., Ursic, M., Vrecl, M. and Pogacnik, A.: Giant muscle fibres in pigs with different Ryr1 genotype. *Anat. Histol. Embryol.* 31, 367-371, 2002.
9. Durbeej, M., Cohn, R. D., Hrstka, R. F., Moore, S. A., Allamand, V., Davidson, B. L., Williamson, R. A. and Campbell, K. P.: Disruption of the beta sarcoglycan gene reveals pathogenetic complexity of limb-girdle muscular dystrophy type 2E. *Moll. Cell.* 5, 141-151, 2000.
10. Schubert-Schoppmeyer, A., Fiedler, I., Nurnberg, G., Jonas, L., Ender, K., Maak, S. and Rehfeldt, C.: Simulation of giant fibre development in biopsy samples from pig longissimus muscle. *Meat Sci.* 80, 1297-1303, 2008.
11. Rahelič, S. and Puac, S.: Fiber types in longissimus-dorsi from wild and highly selected pig breeds. *Meat Sci.* 5, 439-450, 1981.
12. Dutson, T. R., Merkel, R. A., Pearson, A. M. and Gann, G. L.: Structural characteristics of porcine skeletal muscle giant myofibers as observed by light and electron microscopy. *J. Anim. Sci.* 46, 1212-1220, 1978.
13. Sosnicki, A.: Histopathological observation of stress myopathy in m. longissimus in the pig and relationships with meat quality, fattening and slaughter traits. *J. Anim. Sci.* 65, 584-596, 1987.
14. Ferrer, X., Vital, C., Coquet, M., Deleplanque, B., Ellie, E., Lagueny, A. and Julien, J.: Autosomal dominant centronuclear myopathy. *Revue neurologique.* 148, 622-630, 1992.
15. Handel, S. E. and Stickland, N. C.: "Giant" muscle fibres in skeletal muscle of normal pigs. *J. Comp. Pathol.* 96, 447-457, 1986.
16. Adams, R. D., Denny-Brown, D. and CM. Pearson, C. M.: *Diseases of Muscle. A Study in Pathology.* Harper and Brothers, New York, 1962.
17. Makovický, Pe.: The development and histogenesis of striated skeletal muscles of pigs. PhD. Thesis. 2005.
18. Makovický, Pe., Makovický, Pa., Kulíšek, V., Debreceni, O. and Haščík, P.: Histological analysis of size, structure and appearance of giant fibres in skeletal muscles of pigs. *Folia Veterinaria.* 51, 5-8, 2007.
19. Stephan, E., Krogmeier, D., Dzapo, V., Tuller, R. and Velten, H.: Morphological – changes in the fibers of broilers breast – muscles and their relationship to the carcass quality. *Arch. Geflug.* 54, 230-236, 1990.
20. Jeannet, P. Y., Bassez, G., Eymard, B., Laforet, P., Urtizbera, J. A., Rouche, A., Guicheney, P., Fardeau, M. and Romero, N. B.: Clinical and histologic findings in autosomal centronuclear myopathy. *Neurology* 62, 1484-1490, 2004.
21. Remignon, H., Zanusso, J., Albert, G. and Babile, R.: Occurrence of giant myofibres according to muscle type, pre- or post rigor state and genetic background in turkeys. *Meat Sci.* 56, 337-343, 2000.
22. Fiedler, I., Kuhn, G., Hartung, M., Kuchenmeister, U., Nurnberg, K., Rehfeldt, C., Huber, K., and Klosowska, D.: Effects of the malignant hyperthermia syndrome (MHS) on meat quality, muscle fibre characteristics and metabolic traits of the Longissimus muscle in Pietrian pigs. *Arch. Tier. Archives Anim. Breed.* 44, 203-217, 2001.
23. Weyermann, F. and Dzapo, V.: Study on histological traits of equine muscle tissue. *Zuchtingkunde.* 70, 1-12, 1998.
24. Campbell, K. P. and Kahl, S. D.: Association of dystrophin and an integral membrane glycoprotein. *Nature.* 338, 259-262, 1989.
25. Taverna, D., Disatnik, M. H., Rayburn, H., Bronson, R. T., Yang, J., Rando, T. A. and Hynes, R. O.: Dystrophic muscle in mice chimeric for expression of alpha 5 integrin. *J. Cell Biol.* 143, 849-859, 1998.
26. Ohlendieck, K.: Towards an understanding of the dystrophin-glycoprotein complex: linkage between the extracellular matrix and the membrane cytoskeleton in muscle fiber. *Eur. J. Cell. Biol.* 69, 1-10, 1996.
27. Grounds, M. D. and Torrisi, J.: Anti-TNF alpha (Remicade (R)) therapy protects dystrophic skeletal muscle from necrosis. *Faseb J.* 18, 676-682, 2004.
28. Bertoni, C., Morris, G. E. and Rando, T. A.: Strand bias in oligonucleotide-mediated dystrophin gene editing. *Hum. Mol. Genet.* 2, 221-233, 2005.

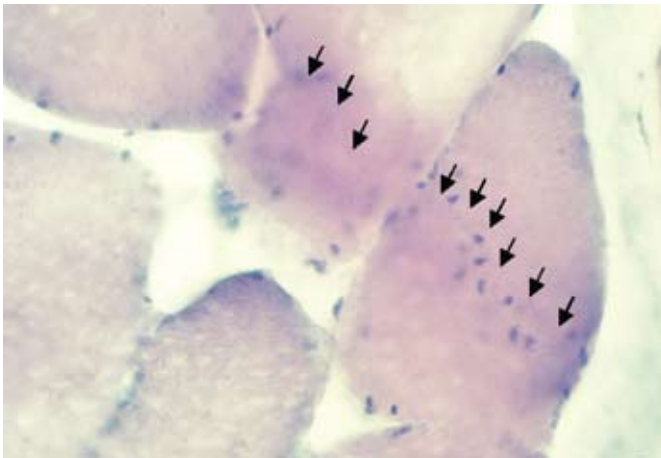




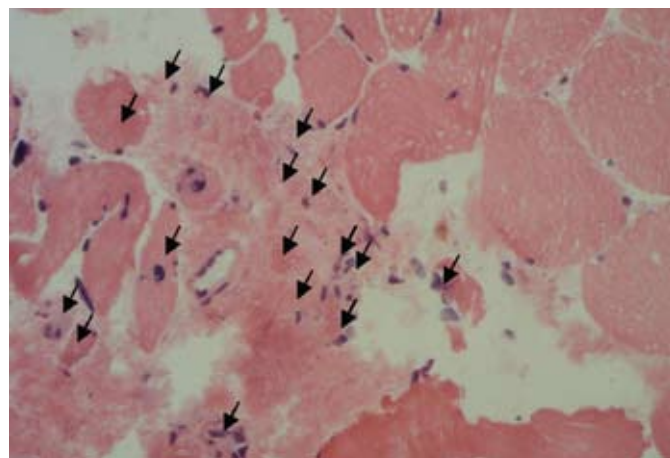
**Fig. 1 .**  
Initial stage of muscle fibre fissuring (G1). At the point of fissure there is a gap orientated towards the centre of the muscle fibres. Hematoxylin-eosin, 200x, filter.



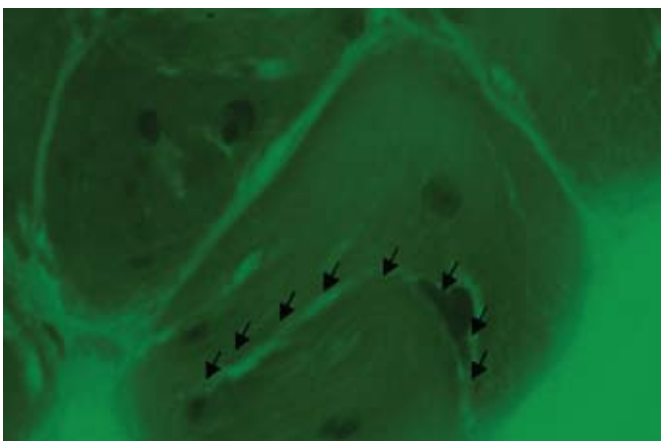
**Fig. 4.**  
Terminal stage of fissuring of giant fibres (G3). These break up into smaller fibres. Hematoxylin-eosin, 400x.



**Fig. 2 .**  
The nucleoli are grouped in the centre of the muscle fibres (G2). These are the limits of the fissuring. Hematoxylin-eosin, 400x, filter.



**Fig. 5.**  
Final stage of fissuring (G4). There are populations of newly created small fibres, which resemble myoid elements or myocytes. Hematoxylin-eosin, 400x.



**Fig. 3.**  
The gap in the centre of muscle fibre with nucleolus formation (G2). An advanced stage of the fissuring of giant muscle fibres. Hematoxylin-eosin, 1000x, filter.