

# HEMANGIOMA AND MYELOCYTOMAS INDUCED BY AVIAN LEUKOSIS VIRUS SUBGROUP J IN COMMERCIAL LAYER FLOCKS

Zhang, H., Liu, Q., Liu, J., Zhang, L., Liu, G., Qiu, B. and Cheng, Z\*

College of Animal Science and Veterinary Medicine, Shandong Agricultural University, Tai'an, 271018, China

Address correspondence and reprint requests to:

Dr. Ziqiang Cheng,  
College of Animal Science and Veterinary Medicine  
Shandong Agricultural University,  
NO 61, Daizong ST, Tai'an City, 271018, P.R. China,  
Tel: +86-538-8245288, Fax: +86-538-8241419  
Email: czqsd@126.com

**Running title:**

Hemangioma and Myelocytomas induced by ALV-J.

**ABSTRACT:**

An outbreak of hemangiomas and myelocytomas in 26 to 29-week-old egg-type chickens was observed in eastern China during late 2007. Mortality of the five flocks is 5~10%. Hemangiomas of various sizes were seen scattered over the trunk, claws, wings, and head. At necropsy, hemangiomas appeared in the pancreases, ovarian follicles and livers. In addition, numerous similar nodular lesions and resembling tumors were seen in the same tissues. Eighty-six serum samples from the five flocks were tested for the presence of ALV-J, ALV-A/B and REV antibodies by enzyme-linked immunosorbent assay (ELISA) technique. The overall seroprevalence of ALV-J antibodies was 61.63% (53/86), while ALV-A/B and REV antibodies were negative. Histologically, hemangiomas were typically cavernous hemangiomas with sponge-like architectures and myeloblastic infiltration, in which large multifocal islands of myeloblasts or myelocytes were observed. Immunohistochemistry with ALV-J and REV monoclonal antibodies revealed a diffuse presence of ALV-J antigen in hemangiomas, myelocytomas, bone marrow, liver, and other internal organs, especially in endothelial cells of small vessels, while there was no REV antigen. PCR analyses revealed the presence of ALV-J proviral sequences were more closely related to HPRS-103 than the to other Chinese field strains and ADOL-7501. No evidence of Marek's disease or lymphoid leukosis was found. The studies found that hemangiomas and myelocytomas appeared in same tissue at same time in layer chickens were induced by avian leukosis virus subgroup J (ALV-J).

**Keywords:** ALV-J, Hemangioma, myelocytoma, Immunohistochemistry, PCR.

**Abbreviations:** ALSV = avian leukosis/sarcoma viruses, ALV-J = subgroup J Avian leukosis virus; REV = reticuloendotheliosis virus; ELISA = enzyme-linked immunosorbent assay; HE = hematoxylin and eosin; IHC = immunohistochemistry; PCR = polymerase chain reaction.

## INTRODUCTION

Subgroup J avian leukosis virus (ALV-J), first described in the United Kingdom in 1989 (1), belongs to a subgroup of the avian leukosis/sarcoma viruses (ALSV) that cause neoplastic lesions mainly in broiler breeders. The most common tumor type associated with ALV-J is myeloid leukosis, although a wide variety of tumors have been associated with the virus, including nephroblastomas (1,2), hemangiomas (3), histiocytic sarcomatosis (4), neurospongoma (5) and hepatocellular cancer (6).

These neoplastic lesions can cause increased mortality in sexually mature chickens. In addition to causing tumors, ALV-J can reduce productivity and may induce immunosuppression and other production problems in affected flocks (7). More recently it was found that ALV-J can induce various tumors and cause production problems in egg-type chickens.

Hemangiomas are a variety of vascular tumors or lesions composed of multilayers of vascular endothelial cells and small vessels (8). These

tumors, including capillary hemangioma, cavernous hemangioma, hemangioendothelioma and hemangioendotheliosarcoma, appear frequently in humans and mammals, and occasionally are found in birds. Most avian hemangiomas rupture easily, and cause fatal bleeding, but their mode of induction is unknown. Also, most ALV isolates induce hemangiomas in birds. The genomes of field strains of avian retrovirus isolated from spontaneous hemangiomas in layers were cloned, and DNA sequence analysis revealed a close homology to ALSV (9).

Experimental infection with prototype virus, HPRS-103 causes mainly myelocytic myeloid leukosis (myelocytomatosis) and nephromas, with a variety of other tumors at lower frequencies (10). Natural infection in commercial flocks is associated with the occurrence mainly of myeloid leukosis (4). There are no reports of hemangiomas and myelocytomas appearing in the same tissue at the same time induced by ALV-J. Recently, there have been many cases of hemangiomas and myelocytomas occurring in commercial laying birds in eastern China.

## MATERIALS AND METHODS

### Case history

In December 2007, a significantly lower peak in production and a higher mortality rate than usual were reported by the owners of first flocks (26 weeks of age). Each successive flock placed in different geographically distinct locations also showed similar low peaks in production but much higher mortality rates. Peaks in production ranged from 60~83%, whereas normal peaks of production were typically over 90%. At 29 week of age, superficial hemangiomas ranging from 5 to 30mm in diameter were seen over the body, claws (Fig.1A), wings, and head. All sick birds showed stunting, comb pallor, blood blisters, and continuous bleeding. Mortality rates ranged from 5~10% per week. For comparison, normal mortality rates were 0.1~0.5% per week. Flock size was approximately 8000~10000 in each house.

These commercial layer flocks were not tested at hatch for possible infection with exogenous retroviruses, thus it is unknown whether they were infected congenitally. A standard vaccination program was given to all flocks. All chickens were vaccinated with a full dose of bivalent vaccine containing MDV serotype 3 (HVT) and MDV serotype 2 (SB-1). Other vaccines typical for broiler breeders were also inoculated.

### Clinical examination and sample collection

All 17 submitted chickens were bled, killed and necropsied. At necropsy, specimens of brain, heart, lung, proventriculus, intestine, liver, spleen, pancreas, ovary, kidney, and tumor tissues were collected and fixed in 10% formalin solution for histological sections. Liver tissues were frozen directly for PCR test. 86 blood

samples were collected from wing veins from the five presenting flocks including the 17 birds. The sera were analyzed with antibodies to ALV-J, ALV-A/B and REV by enzyme-linked immunosorbent assay (ELISA; IDEXX Laboratories, Incorporation, USA) techniques.

### Immunohistochemistry

The test incorporated the monoclonal antibodies G2-3 (11) to ALV-J, and 11B118+11B154 (12) to REV (provided by Professor Zhizhong Cui). Positive antigens were detected in checked slides with monoclonal antibodies against ALV-J and REV. Serial sections were examined immunohistochemically.

All stages were done at room temperature. Tissue sections were cut at 4  $\mu$ m and mounted on poly-L-lysine-coated slides. Sections were deparaffinized and rehydrated, and endogenous peroxidase activity was quenched by treating sections in 3% hydrogen peroxide in methanol. After washed with distilled water three times for 3 minutes each, neutral buffered formalin-fixed sections were treated with 0.1% trypsin in 0.1% calcium (PH 7.8) for 10 minutes to remove cross-linking matrix and reveal antigens. Sections were then washed three times for 5 minutes each with PBS (PH 7.6) and treated with 5% bovine serum albumin and 10% fetal calf serum in PBS as blocking agents for 10 minutes. Slides were then incubated with primary antibody (1:400) for 1 hour, washed with PBS, and incubated with biotinylated secondary anti-rabbit antibody for 30 minutes. The immunoreaction was visualized when brown precipitates were incubated by 3, 3'- diaminobenzidine - hydrogen peroxide substrate solution. Subsequently, the reaction was stopped by water and the slides were then counterstained with hematoxylin. Finally, the slides were covered and examined with light microscopy (Olympus).

### PCR detection of ALV-J gp85 gene and phylogenetic analysis

A pair of primer was designed according to the sequence of encoding gene for partial gp85 encoded gene according to the sequence of prototype ALV-J HPRS-103 (13). DNA was extracted from the livers of affected chickens. The primers were: Forward primer (P1): 5'-CTG-GATCCATGGGAGTTCATCTATTGCAACAACCAG-3' Reverse primer (P2): 5'-TACTGCAGTTAGCGCTGCTAC-GGTGGTGACC-3'. Primer was synthesized and PCR product was sequenced by TAKARA Biotechnology, Inc. (Dalian, China). The PCR assay included the following reagents in the reaction tube: nuclease-free water added to a final volume of 50  $\mu$ l per reaction tube, 10 $\times$ Taq buffer (5  $\mu$ l), dNTP (4  $\mu$ l), 25 pmol of the forward and reverse primers (1  $\mu$ l, respectively), TaKaRa Taq (0.5  $\mu$ l), the sample that may contain isolated viral DNA (1  $\mu$ l). The first of PCR amplification was one cycle at 95  $^{\circ}$ C for 4 minutes for denaturation, and then a total

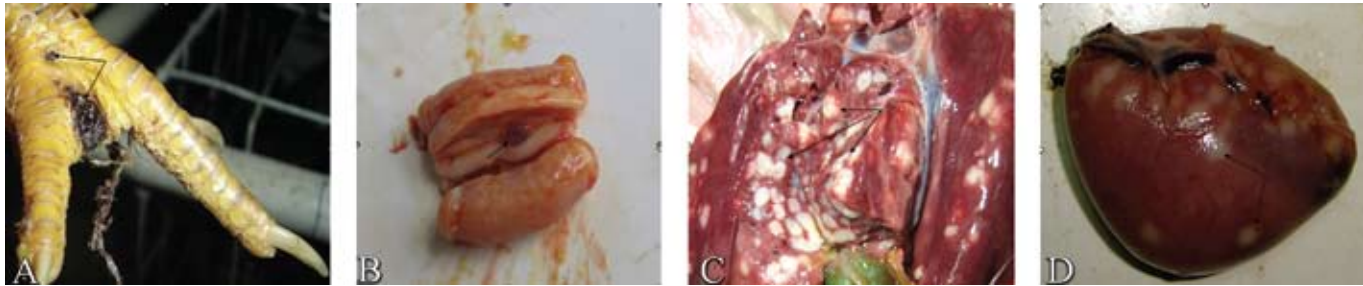of 33 cycles with each step at 95 °C for 30 seconds for denaturation, 58 °C for 1 minute for annealing, and 72 °C for 2 minutes for extension. A final extension cycle was also used at 72 °C for 10 minutes. Four positive PCR products were chosen to sequence then compared with HPRS-103, ADOL-7501 and other Chinese strains.

## RESULTS

### Gross pathology

Hemangiomas were found in ovarian follicles (4mm in diameter) and pancreas (7mm in diameter) in 2 chickens

(Fig.1B). All birds had diffuse enlargement of the livers with well demarcated tumors (Fig.1C), and some birds had a marked splenomegaly and gray-white nodules on the surface of the spleens (Fig.1D), which were 3 to 5 times larger than normal. All chickens had nodular lesions, resembling tumors, in one or more tissues. The most common sites for these lesions were in the livers, spleens, kidneys. Two birds showed minimal ovarian development, indicating that they were not in production. No tumors were observed in the bursa of Fabricius.



**Fig. 1 Gross pathology.**

A: hemangioma on toes, 30×15 mm; B: hemangioma in pancreas, 5×7 mm; C: liver enlarged with white demarcated nodules on surface and section of liver; D: splenomegaly and gray-white nodules on surface of spleen.

### Serology

61.63% (8/17, 12/17, 9/17, 13/17, 11/18) of serum samples in the five flocks were positive for ALV-J. All serum samples of the 17 chickens are positive for ALV-J. The antibodies to ALV-A/B and REV were negative.

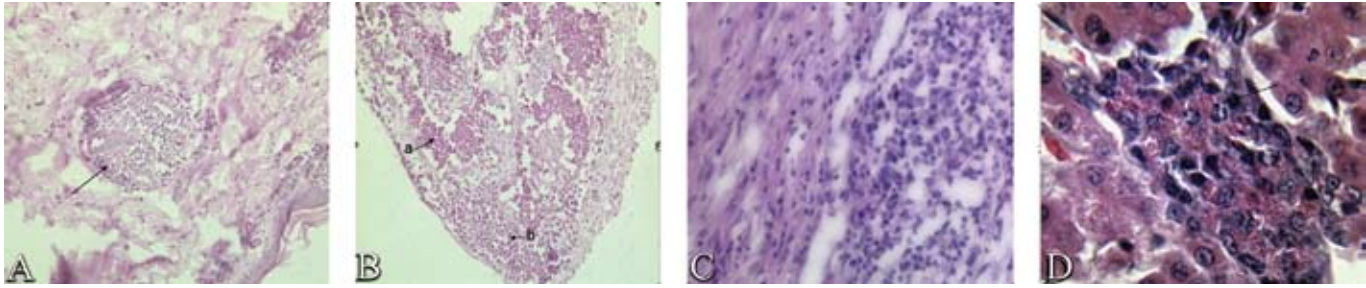
### Histopathology

Histologically, the hemangiomas were typically sponge-like. The architectures of various hemangiomas were quite similar, except some superficial hemangiomas having horny layers (Fig.2A, C). The pathologic analysis showed large cavernous vascular spaces lined with a single layer of endothelial cells and separated by various amounts of fibrosis tissue and inflammatory cells. Large blood-filled endothelium lined spaces with connective tissue septa were observed, which consisted of dilated vascular spaces lined with simple epithelium. Numerous poikilocytes and myeloblasts were filled in the endothelium lined spaces. A large island of myeloblasts in the hemangioma was observed (Fig.2B). There were many capillaries with proliferated endothelial cells observed in these sponge-like architectures. Some new immature capillaries assembled a spongy spherical

mass in encysted vessels (Fig.2A). Many small focal haemorrhages and mild lymphocytic infiltration were also detected throughout the hemangiomas (Fig.2C).

Under light microscope, typical findings in tissues containing tumors were large multifocal islands of myeloblasts comprising round cells with round vesiculated nuclei. There were some round acidophil particles in the cytoplasm of some myelocytoma cells. The granulomas were often surrounded by cellular infiltration in which abnormal mitotic figures (typical of tumor lesions) were frequently observed.

In the bone marrow, a large number of granulocytic cells that virtually filled the marrow cavity were found. The cells were mostly myeloblasts, promyelocytes, and myelocytes stages with rare metamyelocytes. There were moderate numbers of mitoses. In the liver, the interstitium was multifocally infiltrated with coalescing islands of heterophilic myelocytes (Fig.2 D). The results were similar to those in the other tissues. The spleen tissue showed a marked increase in myelocytes and macrophages around the capillaries of ellipsoids. A diagnosis of avian myelocytomatosis was made.

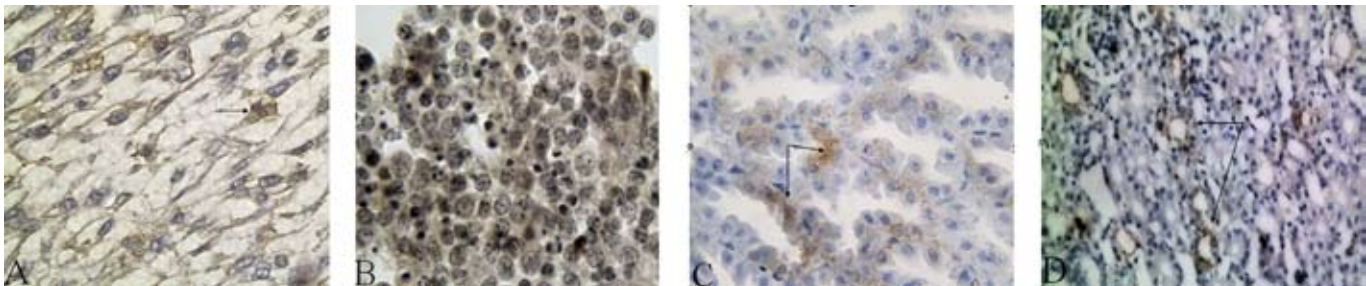


**Fig. 2 Histopathology.**

A: Hemangioma composed of horny layers and a spongy spherical mass, HE, 200×; B: Large blood-filled endothelium lined spaces, b: Island of myeloblasts, HE, 200×; C: Lymphocytic infiltration in hemangioma, HE, 400×; D: Myelocytoma cells with round acidophil particles in the cytoplasm of liver, HE, 1000×.

### Immunohistochemistry

In immunostained sections, labeling for ALV-J antigen was intense and diffuse in many tissues, while REV antigen was negative. Intense positive cytoplasmic staining for ALV-J was found in the tissues of hemangioma (Fig.3.A), bone marrow, liver (Fig.3.B), proventriculus ( Fig.3.C ), spleen, lung bronchiole, and kidney ( Fig.3.D ), especially tumor cells and endothelial cells. No signal was detected in negative control slides.

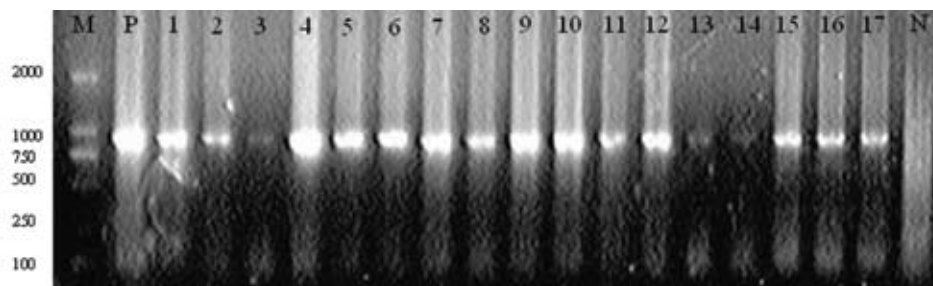


**Fig. 3 Immunohistochemistry.**

A: Endothelial cells of hemangioma were strongly stained, IHC, 1000×; B: Intense positive myelocytes in liver, IHC, 1000×; C: Positive epithelial cells in gland ductulus of proventriculus, IHC, 1000×; D: Positive renal tubular epithelial cells, IHC, 400×.

### PCR detection of ALV-J proviral DNA

PCR tests carried out on DNA samples extracted from livers of the 17 affected chickens showed positive results with amplification of a fragment with the expected size (924 bp) (Fig. 4).



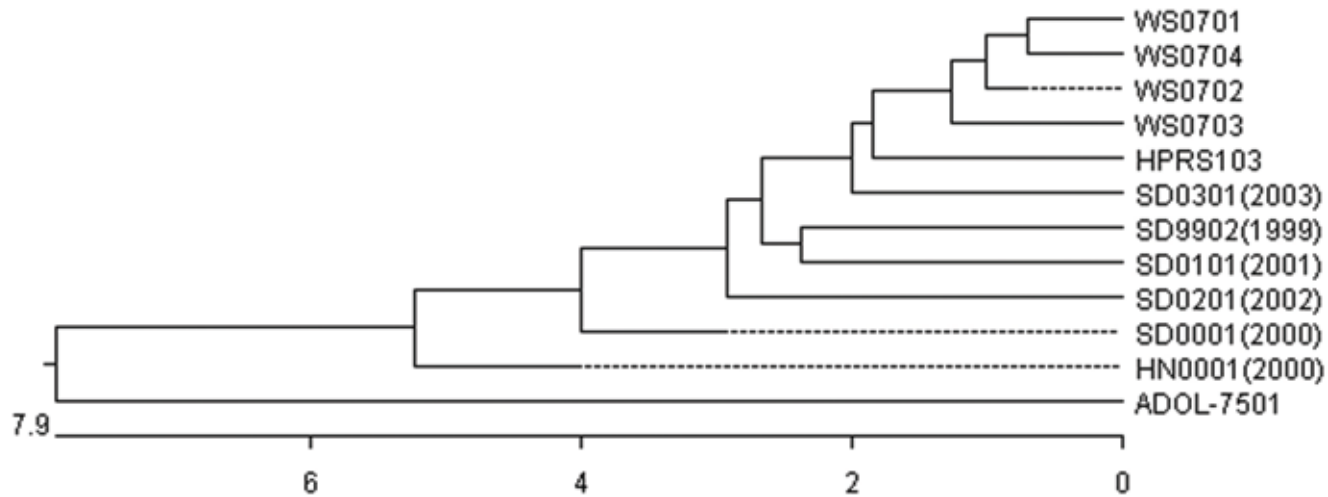
**Fig. 4 The result of PCR for ALV-J detection**

M: Marker; Lane P: positive control; Lane N: negative control; the others were positive. Lane 1~17 represent livers from affected chickens 1~17, respectively.

### Phylogenetic analysis of four PCR positive samples

4 PCR positive products (gp85 gene) were named WS0701, WS0702, WS0703, WS0704, and sequenced. A simple phylogenetic analysis is shown in Figure 5. This figure shows clearly that the four samples are thus more

related to HPRS-103 than they were to Chinese strains and ADOL-7501 sequences. WS0701 and WS0704 shared the highest degree of homology with each other. Overall, the four samples are more closely related to HPRS-103 than to ADOL-7501.



**Fig. 5.**

Phylogenetic tree of gp85 nucleotide sequences of WS strains, other Chinese field strains (SD0301,SD9902,SD0101,SD0201,SD0001,HN0001), HPRS-103 and ADOL-7501

### DISCUSSION

Disease caused by ALV-J is characterized by tumor development, often myeloid leukosis, increased mortality, and decreased body weight (1,14). Since its discovery in the United Kingdom in the late 1980s (1), ALV-J has become a disease concern for the poultry industry worldwide, including China since 1999 (15). During the last 10 years, the early non-transforming ALV-J gradually evolved into acute transforming ALV-J strains. The pathogenicity of ALV-J has evolved significantly in the years following its first identification. Myelocytomas induced by ALV-J mainly in meat-type chickens but not in egg-type chickens was reported previously (10,16). Lately the virus has infected egg-type chickens, causing a variety of tumors.

We describe here two types of tumors, hemangiomas and myelocytomas, associated with ALV-J detected in the same tissue at the same time in commercial layer flocks. Many hens died quickly with massive bleeding or anemia from hemangiomas. Several methods are used currently to diagnose the disease in our studies. The epidemiology, symptoms, and pattern of the lesions detected have varied from when it was first described by Payne in 1989 (1). The pathology of the lesions induced by ALV-J is complex. On histology, the overall appearance of their architecture indicated cavernous hemangiomas. Large areas were composed of vascular spaces lined by

neoplastic cells. Some spaces were large, dilated, filled with blood, and lined by flattened, spindle cells with the general configuration of endothelial cells. Focal to diffuse myeloid cellular infiltration was also observed in the bone marrow, liver, spleen and kidneys. Distribution of virus antigen was intense and diffusive in many tissues in immunostained sections. In addition, intense positive cytoplasmic staining was found in many epithelial cells in hemangioma, liver, spleen, lung bronchiole, proventriculus and kidney by immunohistochemistry. The result suggests that there may be a tropism for endothelial cells causing hemangioma formation.

Detection with ALV-J antibodies showed that 61.63% (53/86) of serum samples were positive for ALV-J in the five flocks by ELISA. The data reveal that commercial layer flocks are widely exposed to subgroup J avian leukosis virus (ALV-J) now. The 17 DNA samples extracted from affected tissues were positive by gp85 specific primer sets in the PCR reaction. Analysis of PCR results suggested that the presence of ALV-J sequences is more closely related to HPRS-103 than they are to other Chinese field strains and ADOL-7501 strain.

In addition, being benign in nature, the endothelial cells of hemangioma proliferate slowly. But in this case the hemangioma was formed within a short time and caused fatal bleeding. The mechanism is unknown. It may be associated with myelocytomas and immunosuppression

caused by ALV-J.

The case suggests that ALV-J continues to pose a risk for the poultry industry and deserves active surveillance. Furthermore, in these studies ALV-J seems to be capable of inducing both hemangiomas and myelocytomas, indicating the virus is capable of inducing a variety of tumors in the same tissue at the same time. It is possible that a higher incidence of tumors, a different type of tumor, tumor location, or a combination may have been detected in these flocks. More eradication programs should be introduced to control ALV-J by removing infected breeding stock from flocks, thereby reducing virus spread by vertical transmission.

## REFERENCES

1. Payne, L. N., S. R. Brown, N. Bumstead, K. Howes, J. A. Frazier, and M. E. Thoules. A novel subgroup of avian leucosis virus in chickens. *J. Gen. Virol.* 72:801-807, 1991.
2. Payne, L. N., A. M. Gillespie, and K. Howes. Myeloid leukaemogenicity and transmission of the HPRS-103 strain of avian leucosis virus. *Leukemia* 6:1167-1176, 1992.
3. Takami, S., M. Goryo, T. Masegi, K. Okada. Systemic spindle-cell proliferative disease in broiler chickens. *J Vet Med Sci.* 67(1):13-18, 2005.
4. Arshad, S. S., A. P. Bland, S. M. Hacker, and L. N. Payne. A low incidence of histiocytic sarcomatosis associated with infection of chickens with HPRS-103 strain of subgroup J avian leucosis virus. *Avian Dis.* 41: 947-956, 1997.
5. Takami, S., M. Goryo, T. Masegi. Histopathological characteristics of spindle cell proliferative disease in broiler chickens and its experimental reproduction in specific pathogen-free chickens. *J Vet Med Sci.* 66(3):231-235, 2004.
6. Cheng, Z.Q, L. Zhang, S.D. Liu, L.J Zhang, Z.Z. Cui. Emerging of Avian leucosis virus subgroup J in a flock of Chinese local breed, *Acta Microbiologica Sinica* 45 (4): 98-102, 2005.
7. Arshad, S. S. Avian leucosis virus subgroup J: disease and diagnosis. *Proceedings of 21st Symposium of the Malaysian Society for Microbiology. Seri Kembangan, Selangor.* pp: 5-9, 1998.
8. Grant, J. W., Gallagher P. J., and Hendinger C. Hemangioblastoma: an immunohistochemical study of ten cases. *Acta Neuropathol.* 76:82-86, 1988.
9. Burstein, H., N. Resnick-Roguel, J. Hamburger, G. Arad, M. Malkinson, and M. Kotler. Unique sequences in the env gene of avian hemangioma retrovirus are responsible for cytotoxicity and endothelial cell perturbation. *Virology*, 179:512-516, 1990.
10. Payne, L. N. HPRS-103: a retrovirus strikes back. The emergence of subgroup J avian leucosis virus. *Avian Pathology.* 27:36-45, 1998.
11. Qin A.J., L.F. Lee, A. Fadly, H. Hunt, Z.Z. Cui. Development and characterization of monoclonal antibodies to subgroup J avian leucosis virus. *Avian Dis.* 45(4):938-45, 2001.
12. Chen P.Y., Z.Z. Cui, L.F. Lee, R.L. Witter. Serologic differences among nondefective reticuloendotheliosis viruses. *Arch Virol.* 93(3-4):233-45, 1987.
13. Cheng, Z.Q, L. Zhang, S.D. Liu, L.J Zhang, Z.Z. Cui. Emerging of Avian leucosis virus subgroup J in a flock of Chinese local breed, *Acta Microbiologica Sinica* 45 (4): 98-102, 2005.
14. Stedman, N. L., and T. P. Brown. Body weight suppression in broilers naturally infected with avian leucosis virus subgroup J. *Avian Dis.* 43:604-601, 1999.
15. Du, Y., Z. Cui, and A. Qin. (1999). Subgroup J of avian leucosis viruses in China. *China Poult. Sci.* 3:1-4.
16. Binrui Xu; Weixing Dong; Chunming Yu; Zhaoqing He; Yanli Lv; Yanzheng Sun; Xiaoyu Feng; Ning Li; L. F. Lee; Maoxiang Li. Occurrence of avian leucosis virus subgroup J in commercial layer flocks in China. *Avian Pathology.* 33(1):13-17, 2004.

## ACKNOWLEDGEMENTS

This research was supported by the National Natural Science Foundation of China (30600444) and the Shandong provincial foundation of science and technology (2006GG2209010 2005BSB01156). We thank Professor Zhizhong Cui for the gift of monoclonal antibodies.