

The First Report of *Tritrichomonas foetus* in Cats from Turkey

Yildiz, K.^{1*} and Sursal, N.²

¹ Kirikkale University Faculty of Veterinary Medicine Department of Parasitology, 71450 Kirikkale, Turkey

² Doctor of Veterinary Medicine, 06110 Ankara, Turkey

* **Corresponding Author:** Dr. Kader YILDIZ, Kirikkale University Faculty of Veterinary Medicine Department of Parasitology, 71450 Kirikkale, Turkey.
E-mail: kaderyildiz@hotmail.com.

ABSTRACT

Tritrichomonas foetus has been identified in the ileum, cecum and colon of cats with large bowel diarrhea. The objective of this study was to identify whether *T. foetus* was present in cats with chronic diarrhea in Turkey. Fecal samples (n=45) were collected from cats with diarrhea presented to a number of pet clinics in Ankara province, Turkey. Fecal analysis was performed using saline wet mount preparations, cultures and PCR. *T. foetus* was detected in 4 out of 45 (8.8%) of the cats with chronic diarrhea by PCR analysis. The infection rate was highest (12%) in the age group ≤ 6 months ($p < 0.05$). There was no significant difference between the frequency of infection in male and female cats ($p > 0.05$). All cats in the study were mixed breed. The frequency of infection was higher in owned cats than in shelter cats (10% versus 6.6%), but this difference was not statistically significant ($p > 0.05$). *Giardia* spp. and *Toxocara leonina* were found as co-infections in the cats infected with *T. foetus*. Two PCR positive results were sequenced and deposited in GenBank (MH400076 and MH490937). Pairwise genetic distance between our isolates and the isolates submitted to GenBank from other geographic areas displayed variation ranging from 0.0% to 1.2%. This is the first report of the presence of *T. foetus* in cats in Turkey. The results support the significance of *T. foetus* as a cause of chronic diarrhea in cats.

Keywords: *Tritrichomonas foetus*; Cat; Diarrhea; Turkey.

INTRODUCTION

Tritrichomonas foetus, Parabasalia, Trichomonadidae, are pear- or spindle-shaped protozoan parasites with one posterior flagellum and three anterior flagella (1). The posterior flagellum forms an undulating membrane along body of the parasite (1). *T. foetus* has been isolated from a variety of organs from a number of species including cattle, cats, dogs and camels (1-4) and as an opportunistic infection from immunocompromised and immunosuppressed humans suffering from meningoencephalitis (5). *T. foetus* isolated from cats appears to be distinct, with minor genetic differences from cattle isolates based on internally transcribed spacer (ITS) and cysteine protease (6, 7). Moreover, it has been proposed that the cat genotype be renamed *Tritrichomonas blagburni* to distinguish it from the cattle genotype (8). At the molecular level, no

differences have been found between *T. foetus* located in the venereal system of cattle and *Tritrichomonas suis* located in the nasal cavity and gastrointestinal system of pigs (9) and it has been suggested that these are synonymous (10). *T. foetus* is also molecularly similar to *Tritrichomonas mobilensis* found in the intestinal tract of squirrel monkeys (11, 12).

Tritrichomonas foetus infection in the ileum, cecum and colon of cats can cause large bowel diarrhea (13, 14). It has also been isolated from the uterus of a cat (15) and, recently, from nasal discharge of a cat (16). *T. foetus* multiplies asexually by dividing in the large intestine, and motile trophozoites are excreted with cat feces (14). The parasite does not develop a cystic form, so trophozoites can survive for short time after shedding, in feces, contaminated water and litter (14). The exact method of transmission of trichomoniasis within cat

populations is not known. The fecal-oral route is probably the most important route of transmission in cats (17). The prevalence of trichomoniasis is particularly high in cats living in shelters and catteries, where fecal-oral transmission is higher because of high density cat populations (18-20).

Lymphoplasmacytic and neutrophilic colitis develop in the distal ileum and colon during feline trichomoniasis (13). Clinical findings vary from subclinical infections to persistent large bowel diarrhea in cats (14). Feces is malodorous, fluid to solid consistency and may contain mucus with fresh blood in infected cats (17, 21). Classical signs of colitis such as fecal incontinence, tenesmus and flatulence may also be seen (14, 17).

Diagnosis of feline trichomoniasis is made by a number of different methods (14, 17). Trophozoites can be observed by microscopic examination of a saline wet mount preparation of fresh feces, but the sensitivity is low, <20% (22). False negatives may occur, particularly if samples are small or not fresh, or if there are low numbers of trophozoites in feces or low parasite number in feces after antibiotic treatment (14, 23). *T. foetus* may be misdiagnosed as *Giardia* spp. during fecal analysis, however, *T. foetus* may be identified by the motility characteristics of the trophozoites, that is, *T. foetus* has a forward motility in contrast to a falling leaf motility of *Giardia* spp. Additionally, fecal enzyme-linked immunosorbent assay can help to confirm giardiasis in cats where trophozoites cannot be identified microscopically (18). The other diagnostic method for feline trichomoniasis is fecal culture using commercially available systems such as InPouch. The fecal samples should be collected with fecal loops, sterile swabs or a colon flush technique (22). The culture medium does not allow the growth of *Giardia* spp. or *Pentatrichomonas hominis*, the commensal protozoon in cat intestine, so positive culture results suggest *T. foetus* infection. The sensitivity of this method is 55.5% (14), false negatives can occur because of intermittent shedding of the trophozoites or recent treatment with antiprotozoal drugs (14).

PCR amplification of ITS1, ITS2 and 5.8S rDNA regions of *T. foetus* is the most sensitive method for the detection of feline trichomoniasis (22, 24, 25). The detection limit of PCR is regarded as 10 parasites per 100 mg faecal samples (26). False negatives can occur if sample size is small or due to PCR inhibitors in the feces (14).

Trichomonas foetus was first identified as a cause of chronic large bowel diarrhoea in cats by PCR in 2001 (2).

Since then there have been reports of feline trichomoniasis from many regions in the world (27-34). There is no information on feline trichomoniasis in Turkey. The objective of this work was to detect *T. foetus* in cats with a reported history of chronic diarrhea in Turkey.

MATERIALS AND METHODS

Sample area and animals

Fecal samples were collected from cats with diarrhea (n=45) admitted to a number of pet clinics in Ankara province during the period from January to May 2018. Ankara is the capital of Turkey, with an elevation above sea level of 874 m. The city has a middle latitude steppe climate, cold, somewhat snowy winters and hot, dry summers. There are estimated to be 15.000-20.000 owned cats within the boundaries of Ankara Metropolitan Municipality (35). The fecal samples were collected from house cats (n=30) which rehomed from shelters or pet shops a while ago, and from shelters cats (n=15). The epidemiological data such as age, breed, sex, origin of acquisition by owner and past treatment history was recorded. All animal handling procedures were approved by the Kirikkale University Local Ethics Committee for Animal Experiments (Protocol no: 17/100).

Fecal sampling and microscopic examination

Fecal consistency scores, based on a modified fecal scoring system for cats (Purina Fecal Scoring System for Dogs and Cats, Nestle-Purina), were either 1 (watery, no texture, flat, occurring as puddles, representing liquid diarrhea) and 2 (has texture, but no defined shape; occurs as piles or as spots) in the sampled cats. All cats were suffered from diarrhea for a time. Fresh fecal samples were taken directly from the litter box just after they had been passed. Saline wet mount preparations and wet preparations stained with Lugol's iodine solution were made from the fecal samples and examined immediately under light microscopy (Leica DM750) for the presence of motile trophozoites. Then fecal samples were collected from the rectum of the same cats using sterile swabs. The fecal samples were inoculated in InPouch TF-Feline (Biomed Diagnostics, White City, OR). The cultures were incubated upright in the dark at 37°C, and then examined microscopically, using 40x objective, every day for one week for the presence of motile trophozoites, with particularly careful examination along the seams of the culture pouch.

Table 1: Epidemiological data on the cats with diarrhea.

Sampled cats (n:45)	<i>T. foetus</i> positive (n:4)	%	P value
Sex			
Female (n: 16)	2	12.5	
Male (n: 29)	2	6.9	
Age			
2-6 months (n: 25)	3	12	
7-12 months (n: 17)	1	5.9	*
Over 1 years (n: 3)	0	0	
Conditions of care			
Owned (n: 30)	3	10	
Shelter (n: 15)	1	6.6	
Treatment			
Previously treated (n: 18)	2	11.1	
Nontreated (n: 27)	2	7.4	
Concurrent infection			
<i>Giardia</i> spp.	3	75	
<i>Toxocara leonina</i>	1	25	

* P<0.05.

Examination for co-infections with other parasites

Zinc sulphate centrifugal fecal flotation was used to detect parasitic co-infections in the cats (36). *Giardia* fecal antigen test (Asanpharm, Seoul, South Korea) was used to detect giardiasis. The fecal samples were also stained with Carbol fuchsin stain for detection of *Cryptosporidium* spp.

Genomic DNA extraction, PCR and sequencing

Genomic DNA was extracted from the fecal samples using the QIAamp DNA Mini Kit (QIAGEN, Toronto, Ontario), following the manufacturer's instructions. Primers TFR3 (5'-CGG GTC TTC CTA TAT GAG ACA GAA CC-3') and TFR4 (5'-CCT GCC GTT GGA TCA GTT TCG TTA A-3') were used to probe 5.8S rRNA gene sequences and internal transcribed spacer (ITS) regions for confirmation of *T. foetus* (24). Amplification was achieved by use of 5 x Hot Firepol Blend Master mix (Solis BioDyne, Estonia) and each primer was added at 25 pmol. *T. foetus* DNA and nuclease-free water were used as positive and negative controls, respectively. The PCR conditions were 95°C for 15 min, followed by 50 cycles of 95°C for 30 s, 67°C for 30 s, 72°C for 45 s, and a final extension at 72°C for 5 min. The PCR amplicons were examined following electrophoresis in 1.5% agarose gel stained with ethidium bromide. Positive bands of expected sizes, TFR3 / TFR4 region 347 bp were observed.

Sequencing was performed commercially (Macrogen, Holland) with ABI 3730XL DNA Sequencer (Applied Biosystems, Foster City, CA) and BigDye Terminator v3.1 Cycle Sequencing Kit (Applied Biosystems, Foster City, CA). Sequences were assembled and edited by Geneious 11.0.2 (37). Nucleotide sequences were aligned with available sequences in GenBank to make species-based identification of specimens using the BLASTn algorithm. Two ITS sequences deposited in GenBank via the Accession Numbers: MH400076, MH490937.

Statistical analysis

Statistical analyses of some epidemiological parameters (age, sex and stayed at home or shelter) were conducted using commercial software (SPSS 14.01, SPSS Inc., Chicago, IL, USA). Data was analysed using the Chi-square. P values of <0.05 were considered statistically significant.

RESULTS

Trichomonas foetus was detected using PCR in 4 out of 45 (8.8%) of the cats with chronic diarrhea. The fecal samples of the cats infected with *T. foetus* (n=4) were all scored as 2, with one of them containing fresh blood. Motile flagellates were not observed in saline wet mount preparations of the fecal samples nor in the culture pouches during the incubation period.

The epidemiological data on the infected cats is presented in Table 1. The cats ranged from 2 months to 17 years of age, with 25 cats being ≤6 months old and 17 being ≤12 months old, and 3 cats being older than one year. The prevalence of *T. foetus* was higher in the group ≤6 months (12%) than in the other age groups (p<0.05). There was no significant difference between the frequency of infection in male and female cats in the present study (p>0.05). All cats were mixed breed. Frequency of infection was higher in the owned cats than shelter cats (10% versus 6.6%), but the result was not statistically significant (p>0.05).

According to the cat owners, the infected cats had suffered from long-standing diarrhea. Two of the cats with trichomoniasis had previously been treated with metronidazole and supportive therapy in the pet clinics, but although clinically the diarrhea initially resolved, it had recurred once treatment was ceased. The other two cats were presented to the clinics with complaints of diarrhea for the first time

during the study. *Giardia* spp. and *Toxocara leonina* were found as co-infections in the cats infected with *T. foetus*. No *Cryosporidium* spp. oocysts were detected in the fecal examination.

Two of the four PCR positive results were randomly selected and sequenced for species – base identification of the isolates and ITS sequences (262–277 bp) were successfully obtained. The presence of one *Tritrichomonas* species was revealed using the BLASTn analyses. Our isolates were the first to be genetically identified as feline *T. foetus* by using sequence analyses of rDNA ITS from Turkey and were deposited in GenBank with the following accession numbers: MH400076 and MH490937. No intraspecific nucleotide diversity was observed between ITS region sequences of the two isolates identified in the present study.

Analyses indicated that Ankara-Turkey 1F-2F isolates showed 100% identity with the isolates of *T. foetus* reported from different hosts and countries including Turkey (KC236423–24), Brazil (KX267765), Poland (KJ439572), France (JX960422), Australia (JX187000), China (JN106455), Switzerland (JN006994), Norway (HM856630 and EF165538) and Australia (GU170219) in GenBank. Pairwise genetic distance between Ankara – Turkey 1F-2F (MH400076, MH490937) and isolates submitted to GenBank from different geographic areas including Turkey showed variation ranged from 0.0% to 1.2%.

Comparison of the sequences obtained from the cats in this study and the sequence of the *T. foetus* cattle isolate (KC236426) previously submitted from Turkey revealed two nucleotide polymorphism (T>A; T>C) in the 5.8S gene region. The multiple alignment analyses revealed a single nucleotide polymorphism (T>C) between cat / cattle *T. foetus* isolates and *T. mobilensis* (JX187012; TMU86612) isolates in the ITS2 region. However, the same isolates showed three nucleotide differences with the *T. mobilensis* (AY886842) isolate identified from a treeshrew in the ITS1 region (Figure 1).

Diarrhea is common in domestic cats and is an important presentation in small animal practice (38). There are many causes of diarrhea in cats, including *T. foetus* (38). *T. foetus* has been reported in cats in many regions of the world (27–34). In a previous study, PCR analysis failed to identify *T. foetus* DNA in feces of cats from Turkey (39). This study, shows a prevalence of 8.8% for trichomoniasis in cats with diarrhea in Turkey.

There are a number of difficulties in diagnosing feline trichomoniasis: the sensitivity of diagnostic methods is low and co-infection with other agents causing diarrhea can mask clinical signs caused by *T. foetus*. Feline trichomoniasis was detected by PCR analysis in this study. The motile flagellates were not seen in the fecal examinations and fecal cultures were negative. The reason for the negative results may be related to low numbers of trophozoites in the sampled feces or intermittent shedding of trophozoites in the feces of cats or treatment with antiprotozoal drugs (14). In the present study, two of infected cats had previously been treated with metronidazole. A characteristic feature of feline trichomoniasis is chronic diarrhea (22, 30, 34). In the present study, the infected cats had suffered from diarrhea for a time.

There are some risk factors for feline trichomoniasis such as age, breed, living conditions and co-infection with other infectious agents (18, 22). The relationship between prevalence of *T. foetus* and the age of infected cats has been widely studied (18, 22, 28, 29, 33). It is commonly accepted that cats less than one year of age are more sensitive to *T. foetus* (22). *T. foetus* infection is characterised by diarrhea in young cats, but asymptomatic infection may be common in older cats (23, 40). In the present study, the cats diagnosed with trichomoniasis were under 1 year, mostly less than 6 months of age. According to the cat owners, the infected cats had suffered from diarrhea for a protracted period of time. Feline trichomoniasis is widely reported in pure breed cats such as Abyssinian, Siamese and Bengal (19, 28, 41). The higher trichomoniasis incidence in purebred cats is probably due to close and direct contact between cats, which, in some prevalence studies, were sampled in breeding centres with a densely housed cat population (22). In the present study, all cats were mixed-breed, so we are unable to comment on breed susceptibility, although previous authors have also reported no breed differences in susceptibility. Crowded condition and poor hygiene may be responsible for transmission of trichomoniasis within cat populations in the shelters (18–20). In the present study, all cats infected with trichomoniasis were connected with shelters (three cats had been rehomed from the shelters, one cat still lived in the shelter).

There is still a question as to whether an immature immune system or co-infections leaves younger cats more susceptible to trichomoniasis (28). In the present study, infected cats with trichomoniasis were aged under 1 year, and mostly less than 6 months. We hypothesize that the cats

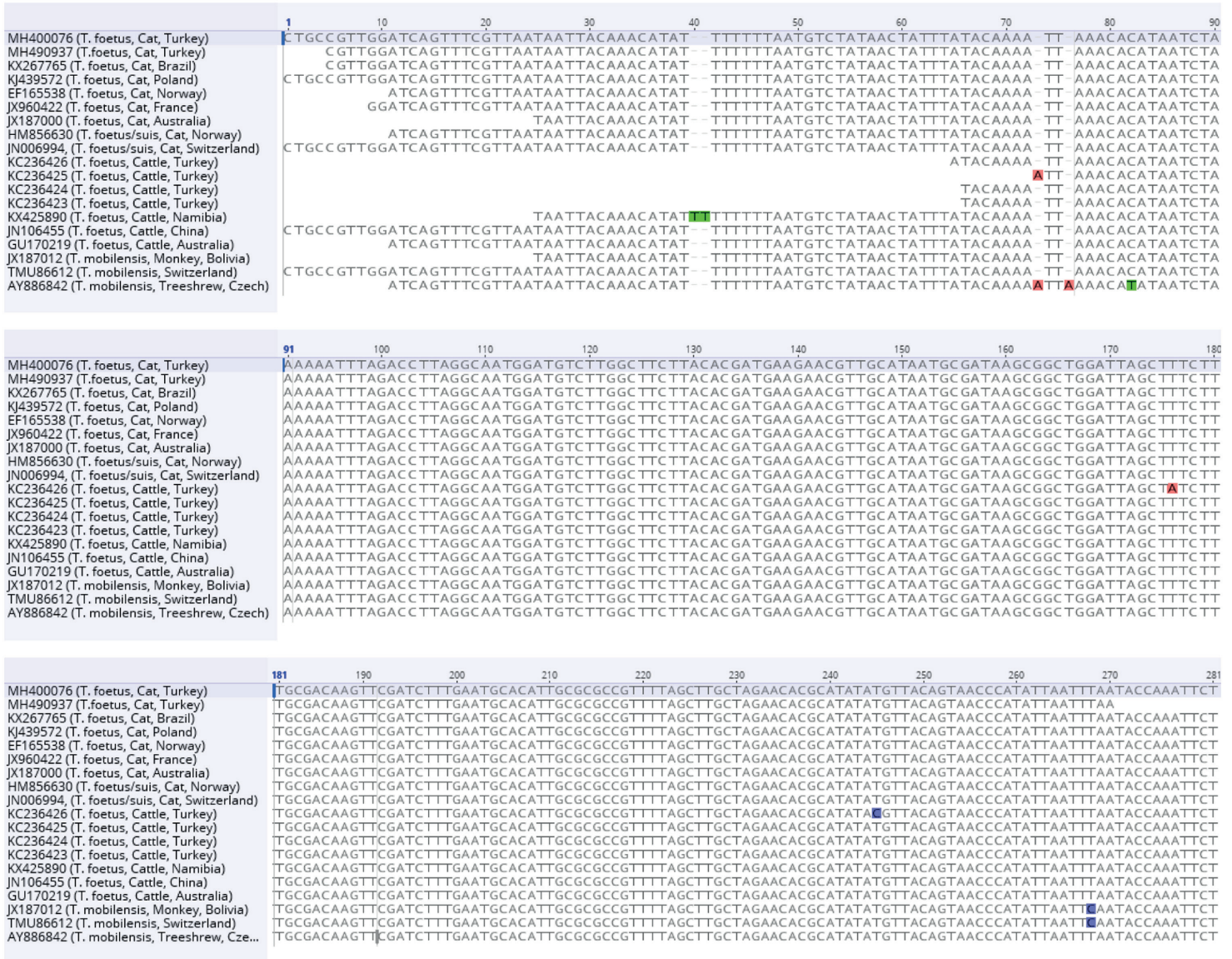


Figure 1. Multiple alignments and comparison of nucleotides of internal transcribed region (ITS), comprising internal transcribed spacer 1 (ITS1) – 5.8S ribosomal DNA – internal transcribed spacer 2 (ITS2) region of *T. foetus* isolates deposited in GenBank and obtained from the cats in the present study. Cattle reference sequences were generated from Turkey (KC236423-236426), Namibia (KX425890), China (JN106455) and Australia (GU170219). Cat reference sequences were generated from Norway (EF165538 and HM856630), Brazil (KX267765), Poland (KJ439572) and Australia (JX187000). Nucleotide changes are shown as different colour. Comparison of the sequences obtained from the cats in this study and the sequence of the *T. foetus* cattle isolate (KC236426) previously submitted from Turkey revealed two nucleotide polymorphism (T>A ; T>C) in the 5.8S gene region. The multiple alignment analyses revealed a single nucleotide polymorphism (T>C) between cat /cattle *T. foetus* isolates and *T. mobilensis* (JX187012, TMU86612) isolates in the ITS2 region. However, the same isolates showed three nucleotide differences with the *T. mobilensis* (AY886842) isolate identified from tree shrew in the ITS1 region.

may have been infected with the parasite during their time in the shelters in the present study. The stress of rehoming may have weakened the cat's immunity resulting in development of clinical signs.

Co-infection is often cited as another risk factor for feline

trichomoniasis and *Giardia* spp. is one of the most commonly detected agents of co-infection (18, 20, 27). In the present study, *Giardia* spp. and *T. leonina* were found as co-infections in the infected cats. Some authors claim the severity of diarrhea is not affected by co-infection with enteric parasites

(41). However, studies of experimental infection suggest that coexisting intestinal infections worsen clinical signs of diarrhea and increase the shedding of *T. foetus* (25). The co-infection with *Giardia* spp. may have altered the fecal consistency in the cats with trichomoniasis in the present study. The feces of cats co-infected with *Giardia* were watery rather than the characteristic semi-formed to “cow-pie” form found with feline trichomoniasis. Fresh blood is sometime reported in cat feces during trichomoniasis (41, 42). Trichomoniasis can damage the colonic epithelium resulting in fresh blood in feces in cats (42). In our study, fresh fecal blood was only found in one cat with trichomoniasis. Colonic bacteria play an important role in the pathogenesis of diarrhea in feline trichomoniasis (14). Diarrhea in cats with trichomoniasis is often decreased by the administration of antibiotics (42). The effects of antibiotics on diarrhea are not know yet, but they may decrease the bacterial load involved in diarrhea pathogenesis or decrease the number of *T. foetus* by depleting their nutrient supplies (42). In the present study, the two cats with trichomoniasis had previously been treated with metronidazole, and although diarrhea improved initially, it recurred once treatment ceased.

Recently, some molecular differences between cattle and feline genotypes of *T. foetus* have been reported (6, 7). Single nucleotid polymorphism is seen in cattle and feline isolates according to sequence data from the ITS 2 and 5.8S rDNA region (6). In the present study our sequences, including ITS1 and 5.8S ribosomal DNA regions, showed 100% identity. Single nucleotide polymorphism in the ITS-2 region have been found in cat and cattle isolates based on the available sequence data in Genbank (6). Pairwise genetic distance between Ankara-Turkey 1F-2F (MH400076, MH490937) and isolates submitted to GenBank from other geographic areas, including Turkey, showed variation ranging from 0.0% to 1,2%. Comparison of the sequences obtained from the cats in this study and the sequence of the cattle isolate (KC236426) previously submitted from Turkey revealed two nucleotide polymorphism (T>A; T>C) in the 5.8S ribosomal DNA region. The multiple alignment analyses showed a single nucleotide polymorphism (T>C) between cat / cattle *T. foetus* isolates and *T. mobilensis* (JX187012; TMU86612) isolates in the ITS2 region.

To the best of the authors' knowledge, this is the first report of the presence of *T. foetus* in cats from Turkey. The re-

sults support the significance of *T. foetus* as a cause of chronic diarrhea in cats in Turkey, especially in cases of recurrent diarrhea where treatment is not effective.

ACKNOWLEDGEMENTS

Positive control was kindly obtained from Prof. Dr. Esin Guven of Department of Parasitology of Ataturk University, Faculty of Veterinary Medicine. This study was financially supported by Scientific Research Coordination Unit of Kirikkale University (Project No: 2017/035).

REFERENCES

- BonDurant, R.H. and Honigberg, B.M.: Trichomonads of Veterinary Importance. In: Kreier JP (Ed) Parasitic Protozoa. Academic Press Inc, San Diego, California, pp.111-177, 1994.
- Levy, M.G., Gookin, J.L., Poore, M., Birkenheuer, A.J., Dykstra, M.J. and Litaker, R.W.: *Tritrichomonas foetus* and not *Pentatrichomonas hominis* is the etiologic agent of feline trichomonal diarrhea. J. Parasitol. 89: 99-104, 2003.
- Gookin, J.L., Birkenheuer, A.J, St. John, V., Spector, M. and Levy, M.G.: Molecular characterisation of tritrichomonads from faeces of dogs with diarrhoea. J. Parasitol. 91: 939-943, 2005.
- Wernery, U.: The barren camel with endometritis-isolation of *Trichomonas fetus* and different bacteria. Zentralbl. Veterinarmed. B 38: 523-528, 1991.
- Okamoto, S., Wakui, M., Kobayashi, H., Sato, N., Ishida, A., Tanabe, M., Takeuchi, T., Fukushima, S., Yamada, T. and Ikeda Y.: *Trichomonas foetus* meningoencephalitis after allogeneic peripheral blood stem cell transplantation. Bone Marrow Transplant. 21: 89-91, 1998.
- Slapeta, J., Craig, S., McDonell, D. and Emery, D.: *Tritrichomonas foetus* from domestic cats and cattle are genetically distinct. Exp. Parasitol. 126: 209-213, 2010.
- Slapeta, J., Muller, N., Stack, C.M., Walker, G., Lew-Tabor, A., Tachezy, J. and Frey, C.F.: Comparative analysis of *Tritrichomonas foetus* (Riedmuller, 1928) cat genotype, *T. foetus* (Riedmuller, 1928) cattle genotype and *Tritrichomonas suis* (Davaine, 1875) at 10 DNA loci. Int. J. Parasitol. 42: 1143-1149, 2012.
- Walden, H.S., Dykstra, C., Dillon, A., Rodning, S., Givens, D., Bird, R., Newton, J. and Lindsay, D.: A new species of *Tritrichomonas* (Sarcomastigophora: Trichomonida) from the domestic cat (*Felis catus*). Parasitol. Res. 112: 2227-2235, 2013.
- Tachezy, J., Tachezy, R., Hampl, V., Sedinova, M., Vanacova, S., Vrlik, M., Van Ranst, M., Flegr, J. and Kuldaa, J.: Cattle pathogen *Tritrichomonas foetus* (Riedmuller, 1928) and pig commensal *Tritrichomonas suis* (Gruby & Delafond, 1843) belong to the same species. J. Eukaryot. Microbiol. 49: 154-163, 2002.
- Lun, Z.R., Chen, X.G., Zhu, X.Q., Li, X.R. and Xie, M.Q.: Are *Tritrichomonas foetus* and *Tritrichomonas suis* synonyms? Trends Parasitol. 21: 122-125, 2005.
- Culberson, D.E., Pindak, F.F., Gardner, W.A. and Honigberg, B.M.: *Tritrichomonas mobilensis* n.sp. (Zoomastigophorea: Tricho-

- monadida) from the Bolivian squirrel monkey *Saimiri boliviensis boliviensis*. J. Protozool. 33: 301e4, 1986.
12. Cepicka, I., Hampl, V., Kulda, J. and Flegr, J.: New evolutionary lineages, unexpected diversity, and host specificity in the parabasalid genus *Tetratrichomonas*. Mol. Phylogenet. Evol. 39: 542-551, 2006.
 13. Yaeger, M.J. and Gookin, J.L.: Histologic features associated with *Tritrichomonas foetus*-induced colitis in domestic cats. Vet. Pathol. 42: 797-804, 2005.
 14. Lappin, M.R.: Trichomoniasis. In: Sykes J.E. (Ed). Canine and Feline Infectious Diseases. Elsevier Saunders, St Louis Missouri, pp. 779-784, 2014.
 15. Dahlgren, S.S., Gjerde, B. and Pettersen, H.Y.: First record of natural *Tritrichomonas foetus* infection of the feline uterus. J. Small. Anim. Pract. 2007; 48: 654-657.
 16. Pazzini, L., Mugnaini, L., Mancianti, F. and Ressel, L.: *Tritrichomonas foetus* and *Mycoplasma felis* coinfection in the upper respiratory tract of a cat with chronic purulent nasal discharge. Vet. Clin. Pathol. 47: 294-296, 2018.
 17. Gookin, J.L., Hanrahan, K. and Levy, M.G.: The conundrum of feline trichomoniasis. J. Feline Med. Surg. 19: 261-274, 2017.
 18. Gookin, J.L., Stebbins, M.E., Hunt, E., Burlone, K., Fulton, M., Hochel, R., Talaat, M., Poore, M. and Levy, M.G.: Prevalence of and risk factors for feline *Tritrichomonas foetus* and *Giardia* infection. J. Clin. Microbiol., 2004; 42: 2707-2710.
 19. Gunn-Moore, D.A., McCann, T.M., Reed, N., Simpson, K.E. and Tennant, B.: Prevalence of *Tritrichomonas foetus* infection in cats with diarrhoea in the UK. J. Feline Med. Surg. 9: 214-218, 2007.
 20. Kingsbury, D.D., Marks, S.L., Cave, N.J. and Grahn, R.A.: Identification of *Tritrichomonas foetus* and *Giardia* spp. infection in pedigree show cats in New Zealand. N. Z. Vet. J. 58: 6-10, 2010.
 21. Gruffydd-Jones, T., Addie, D., Belak, S., Boucraut-Baralon, C., Egberink, H., Frymus, T., Hartmann, K., Hosie, M.J., Lloret, A., Lutz, H., Marsilio, F., Möstl, K., Pennisi, M.G., Radford, A.D., Thiry, E., Truyen, U. and Horzinek, M.C.: Trichomoniasis in cats: ABCD guidelines on prevention and management. J. Feline Med. Surg. 15: 647-649, 2013.
 22. Yao, C. and Köster, L.S.: *Tritrichomonas foetus* infection, a cause of chronic diarrhea in the domestic cat. Vet. Res. 46: 35, 2015.
 23. Gookin, J.L.: Trichomonas. In: Kirk's Current Veterinary Therapy XIV. Bonagura, S.D. and Twedt, D.C. (Eds). Saunders Elsevier, St Louis, Missouri, 2008.
 24. Felleisen, R.S.J., Lambelet, N., Bachmann, P., Nicolet, J., Muller, N. and Gottstein, B.: Detection of *Tritrichomonas foetus* by PCR and DNA enzyme immunoassay based on rRNA gene unit sequences. J. Clin. Microbiol. 36: 513-519, 1998.
 25. Gookin, J.L., Levy, M.G., Law, J.M., Papich, M.G., Poore, M.F. and Breitschwerdt, E.B.: Experimental infection of cats with *Tritrichomonas foetus*. Am. J. Vet. Res. 62: 1690-1697, 2001.
 26. Stauffer, S.H., Birkenheuer, A.J., Levy, M.G., Marr, H. and Gookin, J.L.: Evaluation of four DNA extraction methods for the detection of *Tritrichomonas foetus* in feline stool specimens by polymerase chain reaction. J. Vet. Diagn. Invest. 20: 639-641, 2008.
 27. Bissett, S.A., Gowan, R.A., O'Brien, C.R., Stone, M.R. and Gookin, J.L.: Feline diarrhoea associated with *Tritrichomonas foetus* and *Giardia* co-infection in an Australian cattery. Aust. Vet. J. 86: 440-443, 2008.
 28. Stockdale, H.D., Givens, M.D., Dykstra, C.C. and Blagburn, B.L.: *Tritrichomonas foetus* infections in surveyed pet cats. Vet. Parasitol. 160: 13-17, 2009.
 29. Holliday, M., Deni, D. and Gunn-Moore, D.A.: *Tritrichomonas foetus* infection in cats with diarrhoea in a rescue colony in Italy. J. Feline Med. Surg. 11: 131-134, 2009.
 30. Lim, S., Park, S.I., Ahn, K.S., Oh, D.S., Ryu, J.S. and Shin, S.S.: First report of feline intestinal trichomoniasis caused by *Tritrichomonas foetus* in Korea. Korean J. Parasitol. 48: 247-251, 2010.
 31. Queen, E.V., Marks, S.L. and Farver, T.B.: Prevalence of selected bacterial and parasitic agents in feces from diarrheic and healthy control cats from Northern California. J. Vet. Intern. Med. 26: 54-60, 2012.
 32. Köster, L.S., Chow, C. and Yao, C.: Trichomonosis in cats with diarrhoea in Hong Kong, China, between 2009 and 2014. JFMS Open Rep. 1: 2055116915623561, 2015.
 33. Arranz-Solis, D., Pedraza-Diaz, S., Miro, G., Rojo-Montejo, S., Hernandez, L., Ortega-Mora, L.M. and Collantes-Fernandez, E.: *Tritrichomonas foetus* infection in cats with diarrhea from densely housed origins. Vet. Parasitol. 221: 118-122, 2016.
 34. Hora, A.S., Miyashiro, S.I., Cassiano, F.C., Brandao, P.E., Reche-Junior, A. and Pena, H.F.J.: Report of the first clinical case of intestinal trichomoniasis caused by *Tritrichomonas foetus* in a cat with chronic diarrhoea in Brazil. BMC Vet. Res. 13: 109-112, 2017.
 35. Ozen, D., Gurcan, S. and Kaya, U.: Ankara ilinde yer alan sahipli kedi ve köpek popülasyonunun belirlenmesi. Vet. Hekim. Der. Derg. 85: 9-16, 2014.
 36. Zajac, A.M. and Conboy, G.A.: Veterinary Clinical Parasitology. 7th Edition. Blackwell Publishing Professional, Ames, Iowa, USA, 2006.
 37. Kearse, M., Moir, R., Wilson, A., Stones-Havas, S., Cheung, M., Sturrock, S., Buxton, S., Cooper, A., Markowitz, S., Duran, C., Thierer, T., Ashton, B., Meintjes, P. and Drummond, A.: Geneious Basic: an integrated and extendable desktop software platform for the organization and analysis of sequence data. Bioinformatics, 28: 1647-1649, 2012.
 38. Thomason, J.M.: Diarrhea. In: Norsworthy, G.D. (Ed.), The Feline Patient. Fifty ed. John Wiley and Sons Inc., pp. 146-149, 2018.
 39. Pekmezci, D. and Pekmezci, G.Z.: Kedilerde *Tritrichomonas foetus* enfeksiyonu ve risk faktörleri. Erciyes Univ. Sağlık. Bil. Derg. 26: 165-168, 2017.
 40. Foster, D.M., Gookin, J.L., Poore, M.F., Stebbins, M.E. and Levy, M.G.: Outcome of cats with diarrhea and *Tritrichomonas foetus* infection. J. Am. Vet. Med. Assoc. 225: 888-892, 2004.
 41. Kuehner, K.A., Marks, S.L., Kass, P.H., Sauter-Louis, C., Grahn, R.A., Barutzki, D. and Hartmann, K.: *Tritrichomonas foetus* infection in purebred cats in Germany: prevalence of clinical signs and the role of co-infection with other enteroparasites. J. Feline Med. Surg. 13: 251-258, 2011.
 42. Tolbert, M.K. and Gookin, J.L.: Mechanisms of *Tritrichomonas foetus* pathogenicity in cats with insights from venereal trichomonosis. J. Vet. Intern. Med. 30: 516-526, 2016.