

Haemosporidian Parasites in Blood Smears of Sparrowhawks (*Accipiter nisus*, Falconiformes: Accipitridae) in Northeastern Turkey

Balkaya, I.,^{1*} Oruc, E.,^{2,3} Guven, E.¹ and Avcioglu, H.¹

¹ Department of Parasitology, Faculty of Veterinary Medicine University of Ataturk, Erzurum, Turkey.

² Department of Pathology, Faculty of Veterinary Medicine University of Ataturk, Erzurum, Turkey.

³ Department of Pathology, Faculty of Veterinary Medicine, Kyrgyzstan - Turkey Manas University, Bishkek, Kyrgyzstan.

* **Corresponding Author:** Ibrahim Balkaya, Ataturk University, Faculty of Veterinary Medicine, Department of Parasitology, Erzurum, Turkey.
Tel: +904422315532. E-mail: balkayaibrahim@hotmail.com

ABSTRACT

This preliminary study was aimed at determining the occurrence of haemosporidian parasites in the blood of sparrowhawks. For this purpose, blood samples were prepared from 9 sparrowhawks. All birds had been collected from different areas of Northeast Turkey. Blood smears were stained with 5% Giemsa solution and examined under the light microscopy. A total of 7 individuals were infected (77.8%). *Haemoproteus* spp., *Leucocytozoon* spp. and *Plasmodium* spp. were detected in 5 (55.6%), 6 (66.7%) and 4 (44.4%) birds, respectively. There were no haemosporidian parasites in 2 birds (22.2%). We observed mixed infections in 85.7% of the birds and single infections (14.3%). Each of the 3 parasites was observed together in 2 birds. Both *Haemoproteus* spp. and *Leucocytozoon* spp. were detected in 3 birds. *Leucocytozoon* sp. and *Plasmodium* sp. were detected in one bird. This is the first report of the occurrence of haemosporidian parasites in sparrowhawks in Northeastern Turkey.

Keywords: *Accipiter nisus*; Blood smear; Haemosporidian parasites; Northeastern Turkey; Sparrowhawk.

INTRODUCTION

Haemosporidians are obligatory diheteroxen parasites requiring both vertebrate and blood-sucking insect hosts to complete their life cycle (1). Insects are the definitive hosts in that in this host the sexual part of the parasite life cycle occurs. Species of genus *Plasmodium* develop in mosquitoes of the family Culicidae (Genera: *Culex*, *Aedes*, *Culiseta*, *Anopheles*, *Mansonia* and *Aedeomyia*). The primary vectors for *Haemoproteus* parasites are biting midges of the genus *Culicoides* (Diptera: Ceratopogonidae) and louse flies of the family Hippoboscidae (1). Vectors of *Leucocytozoon* are black flies (Diptera: Simuliidae) (2).

Avian haemosporidian parasites constitute those that infect erythrocytes and other organs within their hosts (1). Avian haemosporidian parasites (*Plasmodium* spp.,

Haemoproteus spp. and *Leucocytozoon* spp.) can affect host survival (3-4) and body condition (5) with extreme cases resulting in the death of the host (6). *Plasmodium* infections are thought to be the most dangerous (7).

Haemoproteus spp. is found in high prevalence in migratory birds causing a decrease in the levels of body fat and slow performance during migration (8). Despite the ecological significance of birds, many aspects of their biology remain a little-known, including the diversity of parasites infecting them in the wildlife (9).

Parasitaemia due to haemoprotozoan parasites has been detected in microscopic examination in pigeons and dove samples from Bolivia (10), Brazil (11), Mexico (12), Texas (13), Nebraska (14) and infection rates were reported as 18%, 19.3-100%, 90%, 91%, 83% respectively. In Turkey, Gulanber

et al. (15) and Senlik *et al.* (16) obtained average infection rates for *H. columbae* in adult domestic pigeons of 43.2% and 18.8%. Oz *et al.* (17) obtained infection rates for *H. columbae* in adult and nestling domestic pigeons from Adana of 89.02% and 78.57% respectively. The prevalence of parasitemia has been recorded in different geographical areas in Turkey varying between 57% and 74% (18-20).

The sparrowhawk (*Accipiter nisus*) is a small raptor, member of the family Accipitridae. Throughout the world, there are 50 different species of the genus *Accipiter*. The sparrowhawk is a main predator of small birds, especially sparrows (21-23). Quail hunting with sparrowhawks is an ancestral sport in Anatolia. Predators migrate from Asia and Europe to Africa using the Eurasian-East African flight path. The sparrowhawks, fly over the Eastern Turkey during this migration period and finally reach the Coruh Valley in Erzurum Province (24-26).

Hematology is an important aspect of veterinary medicine. It is difficult to depict the haemoprotozoan parasites in avian blood cells. The researchers need to describe the standard morphology of cells in order to interpret changes in them. The aim of this preliminary study was to determine the occurrence of *Haemoproteus* spp., *Leucocytozoon* spp. and *Plasmodium* spp., the haemosporidian parasites in the blood of sparrowhawks in Northeast Turkey.

MATERIAL AND METHODS

In this study, nine wounded and clinically incurable hawks provided by certified hunters during the hawk migration season in the north-eastern Turkey and brought to the clinic. All birds had been collected from different areas of Rize and Erzurum for the study of a PhD thesis (27). The sparrowhawks were provided during the hawk migration season (between July-October) in north-eastern Turkey. Two of them were male and seven were female. All of them were 1-1.5 years old. Blood samples were prepared from 9 sparrowhawks.

A small amount of blood (approximately 20 μ L) was obtained from the ulnar (wing) vein. Thin smears were prepared from blood samples, air-dried, and fixed in absolute methanol. All smears were stained with 5% Giemsa solution and examined under the light microscopy (Olympus BX52 with DP72 camera system, Tokyo, Japan) by using the immersion objective (x1000) for the presence of haemoprotozoans.

Specific diagnostic criteria were used for species identification (28-30). Microscopic examination of blood smears using Giemsa stain is considered a sensitive method to detect trophozoites, schizonts and gametocytes. *Haemoproteus* spp. gametocytes are only present within erythrocytes and they have a "halter-shaped" appearance with little displacement of the host nucleus. Schizonts are not seen on peripheral blood smears. *Leucocytozoon* spp. form gamonts in white blood cells. Gametocytes cause marked enlargement and distortion of the infected cells producing an American football ball-like appearance. Intraerythrocytic trophozoite of *Plasmodium* spp. are small round to oval structures with a large vacuole that forces the erythrocyte nucleus to one pole of the cell (31-33)

RESULTS

After the microscopic examination, one or more haemosporidian parasites were detected in 7 of 9 birds (77.8%). *Haemoproteus* spp. (Figure 1), *Leucocytozoon* spp. (Figure 2) and *Plasmodium* spp. (Figure 3) were detected in 5 (55.6%), 6 (66.7%) and 4 (44.4%) birds, respectively. There were no haemosporidian parasites in 2 birds (22.2%). Mixed infections were detected in 6 birds (85.7%). All of the 3 parasites were observed together in 2 birds. Both *Haemoproteus* spp. and *Leucocytozoon* spp. were detected in 3 birds. *Leucocytozoon* spp. and *Plasmodium* spp. were detected in one bird. Finally, *Plasmodium* sp. was detected alone in 1 bird. The distribution of haemosporidians parasites infection in sparrowhawks is displayed in Table 1.

DISCUSSION

Bensch *et al.* (2009) reported that the diversity of avian haemosporidian parasites among bird species worldwide includes data for 21 out of the 239 recognized species of hawks and eagles (34). In another study (35) of the Philippine Islands, of the 215 screened birds, 30 (14%) presented with different types of multiple infections: 31 infected individuals had a single *Haemoproteus* lineage (14%), 18 a single *Leucocytozoon* lineage (8%) and 12 a single *Plasmodium* lineage (6%).

In this study, *Haemoproteus* spp., *Leucocytozoon* spp. and *Plasmodium* spp. were detected in 55.6%, 66.7% and 44.4% respectively in sparrowhawk. Besides, total infection rate was found as 77.8%. We observed more mixed infections than single infections. Our data support previous studies

Table 1: The distribution of haemosporidians parasites infection in sparrowhawks.

Birds (No.)	<i>Haemoproteus</i> spp.	<i>Leucocytozoon</i> spp.	<i>Plasmodium</i> spp.	Mixed infection
1	-	-	-	-
2	+	+	-	<i>Hemoproteus</i> spp. and <i>Leucocytozoon</i> spp.
3	+	+	-	<i>Hemoproteus</i> spp. and <i>Leucocytozoon</i> spp.
4	+	+	+	<i>Hemoproteus</i> spp., <i>Leucocytozoon</i> spp. and <i>Plasmodium</i> sp.
5	+	+	-	<i>Hemoproteus</i> spp. and <i>Leucocytozoon</i> spp.
6	-	-	+	-
7	-	-	-	-
8	+	+	+	<i>Hemoproteus</i> spp., <i>Leucocytozoon</i> spp. and <i>Plasmodium</i> sp.
9	-	+	+	<i>Leucocytozoon</i> spp. and <i>Plasmodium</i> spp.
Total	5	6	4	6

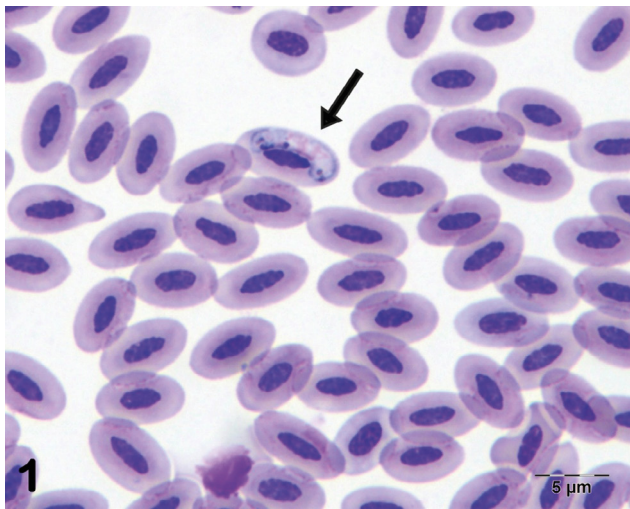


Figure 1: *Haemoproteus* sp. gametocyte in thin smears with Giemsa staining, original magnification: X1000.

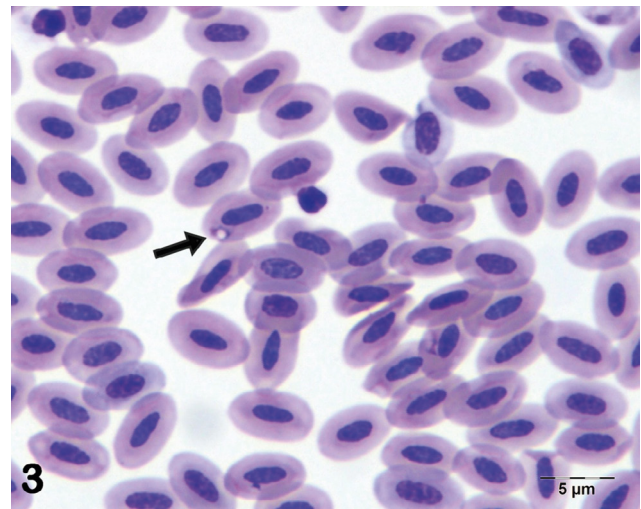


Figure 3: *Plasmodium* sp. gametocyte in thin smears with Giemsa staining, original magnification: X1000.

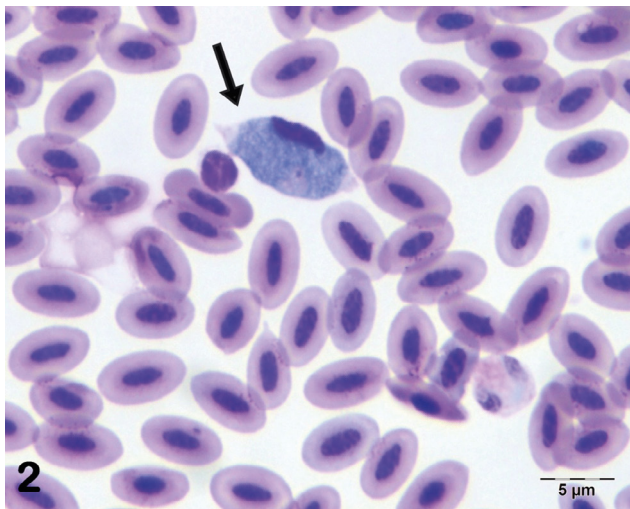


Figure 2: *Leucocytozoon* sp. gametocyte in thin smears with Giemsa staining, original magnification: X1000.

that showed *Leucocytozoon* and *Haemoproteus* to be generally more prevalent than *Plasmodium* (36-38). This difference in prevalence is likely due to less pathogenicity of *Haemoproteus* and *Leucocytozoon* as compared to *Plasmodium* (6-7, 39).

Previous studies showed that *Columbidae* family has a high prevalence of haemosporidia (7). In Turkey, Gulamber *et al.* (15) and Senlik *et al.* (16) obtained average infection rates for *H. columbae* in adult domestic pigeons of 43.2% and 18.8%, respectively. Oz *et al.* (17) obtained the infection rates for *H. columbae* in adult and nestling domestic pigeons from Adana of 89.0% and 78.6% respectively. Besides, the prevalence was recorded in different geographical areas in Turkey between 57% and 74% (18-20). In the present study, the rate of haemosporidian parasites was found as 77.8% in sparrowhawks.

In conclusion, to the best knowledge of the authors this is the first study to report the occurrence of hemosporidian parasites in sparrowhawk in Northeastern Turkey which was determined as *Leucocytozoon* sp. (66.7%), *Haemoproteus* sp. (55.6%) and *Plasmodium* sp. (44.4%) in haematological smears.

In Anatolia, sparrowhawks are valuable species in danger of extinction. In the literature review, it was observed that the studies about hemosporidian parasites in wild birds are sparse in Turkey. Because of the importance of sparrowhawk in Eastern Turkey, we believe that this study will form a basis for the future studies of other parasitologists. The limitations of this study include the small sample size and the lack of molecular techniques to detect the blood parasites. More studies using a greater number of birds are required to verify the results of this study.

ACKNOWLEDGEMENT

Blood samples used in this study were obtained from 9 sparrowhawks collected for the study of PhD thesis of Hulya Balkaya. The authors thanks to Dr. Hulya Balkaya for permission to use of blood samples.

REFERENCES

- Valkiunas, G.: Avian malaria parasites and other haemosporidia. Boca Raton, FL: CRC press, 2005.
- Martinsen, E.S., Perkins, S.L. and Schall, J.J.: A three-genome phylogeny of malaria parasites (*Plasmodium* and closely related genera): Evolution of life-history traits and host switches. *Mol. Phylogenet. Evol.* 47: 261–273, 2008.
- Dawson, R.D. and Bortolotti, G.R.: Effects of hematzoan parasites on condition and return rates of American Kestrels. *The Auk* 117: 373–380, 2000.
- Moller, A.P. and Nielsen, J.T.: Malaria and risk of predation: A comparative study of birds. *Ecology* 88: 871–881, 2007.
- Valki-unas, G., Zickus, T., Shapoval, A.P. and Iezhova, T.A.: Effect of *Haemoproteus belopolskyi* (Haemosporida: Haemoproteidae) on body mass of the blackcap *Sylvia atricapilla*. *J. Parasitol.* 92: 1123–1125, 2006.
- Van Riper, C., Van Riper, S.G., Goff, M.L. and Laird, M.: The epizootiology and ecological significance of malaria in Hawaiian landbirds. *Ecol. Monogr.* 56: 327–344, 1986.
- Atkinson, C.T. and Van Riper, C.: Pathogenicity and epizootiology of avian haematozoa: *Plasmodium*, *Leucocytozoon*, and *Haemoproteus*. New York, Oxford University Press, 1991.
- Valkiunas, G.A.: Influence of haemoproteids and leucocytozooids on wild birds. Eighth International Congress of Parasitology, Abstracts, Volume 1 (022.1. 266), 10-14 October 1994.
- Perez-Rodriguez, A., De la Puente, J., Onrubia, A. and Perez-Tris, J.: Molecular characterization of haemosporidian parasites from kites of the genus *Milvus* (Aves: Accipitridae). *Int. J. Parasitol.* 43: 381–387, 2013.
- Bennett, G.F., Garvin, M. and Bates, J.M.: Avian Hematozoa from West Central Bolivia. *J. Parasitol.* 77: 207–211, 1991.
- Adriano, E.A. and Cordeiro, N.S.: Prevalence and intensity of *Haemoproteus columbae* in three species of wild doves from Brazil. *Mem. Inst. Oswaldo Cruz.* 96: 175–178, 2001.
- Bennett, G.F., Aguirre, A.A. and Cook, R.S.: Blood parasites of some birds from Northeastern Mexico. *J. Parasitol.* 77: 38–41, 1991.
- Godfrey, R.D., Fedynich, A.M. and Pence, D.B.: Quantification of Hematozoa in blood smears. *J. Wild. Dis.* 23: 558–565, 1987.
- Greiner, E.C.: Prevalence and potential vectors of *Haemoproteus columbae*. *J. Wild. Dis.* 11: 150–156, 1975.
- Gulander, A., Tuzer, E. and Cetinkaya, H.: *Haemoproteus columbae* infections and *Pseudolynchia canariensis* infestations in pigeons in Istanbul, Turkey. *Istanbul Univ. Vet. Fak. Derg.* 28: 227–229, 2002.
- Senlik, B., Gulegen, E. and Akyol, V.: Prevalence and intensity of *Haemoproteus columbae* in domestic pigeons. *Indian Vet. J.* 82: 998–999, 2005.
- Oz, I. and Turut, N.: The prevalence of *Haemoproteus columbae* in Domestic pigeons in the province of Adana. *Bornova Vet. Kont. Arařt. Enst. Derg.* 29: 25–29, 2007.
- Gicik, Y. and Aslan, M.O.: Blood parasites of wild pigeons in Ankara district. *Turk. J. Anim. Sci.* 25: 169–172, 2001.
- Koroglu, E. and Simsek, S.: Elazig yoresi guvercinlerinde (*Columba livia*) bulunan kan parazitleri ve yayilis oranlari. *Firat Univ. Saglik Bil. Derg.* 15: 185–188, 2001.
- Tolgay, N.: Cesitli kanatli larin *Plasmodium*, *Haemoproteus* ve *Leucocytozoon* enfeksiyonlari uzerinde arastirmalar. *Ankara Univ. Vet. Fak. Derg.* 19: 271–286, 1972.
- Baris, S.: Geleneksel Atmacilik, Cevre ve Orman Bakanligi, Doga Koruma ve Milli Parklar Genel Mudurlugu. Ankara: Nurol Matbaacilik, pp. 19–28. ISBN 975920620-X, 2004.
- Lehikoinen, A.: Advanced autumn migration of sparrowhawk has increased the predation risk of long-distance migrants in Finland. *PLoS ONE* 6, e20001. 2011.
- Balkaya, H. and Ozudogru Z.: Macroanatomical Aspects of the Lumbar Plexus and its Branches in the Sparrowhawk. *Anatomia, Histologia, Embryologia*, doi: 10.1111/ah.12172. 2015.
- Greenberg, R. and Marra, P.P.: Birds of Two Worlds: The Ecology and Evolution of Migration. Baltimore, Maryland: Johns Hopkins University Press, 2004.
- Gokturk, T., Artvinli, T. and Bucak, F.: Artvin kus faunasi. *ACU J. For. Fac.* 9: 33–43, 2008.
- Balkaya, H. and Ozudogru Z.: Macroanatomical aspects of the sacral plexus and its branches in sparrowhawk. *Journal of Applied Animal Research*, doi: 10.1080/09712119.2015.1013962. 2015.
- Balkaya, H.: A Comparative, macroanatomic and subgross study on the plexus lumbosacrales of Sparrowhawk (*Accipiter nisus*) and Pigeon (*Columba livia*). [Ph.D. Thesis]. Erzurum: Ataturk University, 2012.
- Bennett, G.F. and Peirce, M.A.: The haemoproteid parasites of the pigeons and doves (family Columbidae). *J. Nat. Hist.* 24: 311–325, 1990.

29. Soulsby, E.J.L.: Helminths, Arthropods and Protozoa of Domesticated Animals. 7th Edition. Bailliere Tindall. London, 1982.
30. Bennett, G.F. and Peirce, M.A.: Morphological form avian Haemoproteidae and an annotated checklist of the genus *Haemoproteus* Kruse, 1890. J. Nat. Hist. 22: 1683-1696, 1988.
31. http://en.wikivet.net/Malaria_-_Birds#Diagnosis (23.04.2015).
32. http://en.wikipedia.org/wiki/Leucocytozoon#Diagnostic_criteria (23.04.2015).
33. http://en.wikipedia.org/wiki/Haemoproteus#Diagnostic_criteria (23.04.2015).
34. Bensch, S., Hellgren, O. and Perez-Tris, J.: MalAvi: a public database of malaria parasites and related haemosporidians in avian hosts based on mitochondrial cytochrome b lineages. Mol. Ecol. Resour. 9: 1353–1358, 2009.
35. Silva-Iturriza, A., Ketmaier, V. and Tiedemann, R.: Prevalence of avian haemosporidian parasites and their host fidelity in the central Philippine islands. Parasitol. Int. 61: 650–657, 2012.
36. Arriero, E. and Moller, A.P.: Host ecology and life-history traits associated with blood parasite species richness in birds. Journal of Evolutionary Biology. 21: 1504–1513, 2008.
37. Moller, A.P. and Nielsen, J.T.: Malaria and risk of predation: a comparative study of birds. Ecol. 88: 871–881, 2007.
38. Hauptmanova, K., Benedikt, V. and Literak, I.: Blood parasites in passerine birds in Slovakian east Carpathians. Acta Protozool. 45: 105–109, 2006.
39. Atkinson, C.T., Dusek, R.J., Woods, K.L. and Iko, W.M.: Pathogenicity of avian malaria in experimentally-infected Hawaii Amakihi. J. Wild. Dis. 36: 197–204, 2000.