

Caudal Partial Scapulectomy for the Treatment of Osteosarcoma in a Dog

Zemer, O., Cohen., Dank, G., Epstein, A. and Milgram, J.

Department of Small Animal Surgery, Veterinary Teaching Hospital Koret School of Veterinary Medicine. The Hebrew University of Jerusalem, Rehovot, Israel.

* **Correspondence:** Dr. Orly Zemer, DVM. Department of Small Animal Surgery, Veterinary Teaching Hospital, Koret School of Veterinary Medicine, The Hebrew University of Jerusalem. POB 12, Rehovot, 76100, Israel. Phone: +972 3 9688513; Fax: +972 3 9604079; email: orlyzemer@yahoo.co.uk

ABSTRACT

The objective of this case report is to describe an ostectomy of the caudal aspect of the scapula, as a limb sparing procedure, for the treatment of osteosarcoma in a dog. A 9 year old, 33kg, spayed female, mixed breed dog presented with a mass on the caudal aspect of the right scapula. The mass was suspected to be a mesenchymal cell tumor on fine needle aspiration and a computerized tomography scan confirmed the location and extent of the mass. No metastatic disease was identified in the local lymph nodes or chest. A partial scapulectomy of the caudal aspect of the scapula, preserving the glenohumeral joint, was performed. The mass was found to be a chondroblastic osteosarcoma and adjuvant chemotherapy with carboplatin and doxorubicin was initiated two weeks postoperatively. Recovery was uneventful except for a mild temporary proprioception deficit of the operated limb and seroma formation under the incision. Lameness resolved two weeks post operatively. Local recurrence and lungs metastasis were evident on follow up 8 months postoperatively. It was concluded that partial scapulectomy of the caudal aspect of the scapula fulfills all the requirements of a limb sparing procedure and is a good alternative to forequarter amputation in dogs with osteosarcoma.

Key words: Dog, Scapula, Scapulectomy, Osteosarcoma, Treatment, Surgery

INTRODUCTION

Osteosarcoma is the most common primary bone neoplasia in dogs, accounting for up to 85% of malignancies originating in the skeleton. Other types of primary bone tumors include chondrosarcoma, haemangiosarcoma and fibrosarcoma (1).

Amputation of the affected limb in combination with adjuvant chemotherapy is the recommended treatment for primary bone tumors and is tolerated well by most dogs (2). An additional treatment option suitable for some dogs is limb sparing surgery. The goal of limb sparing surgery is to eradicate skeletal neoplasia, relieve pain and maintain limb function while not effecting survival time (1,3,4). Limb spar-

ing surgery is ideal for dogs that are poor candidates for amputation or when amputation of the affected limb is unacceptable to the client.

Partial or subtotal scapulectomy is a limb sparing procedure which involves removal of a portion of the scapula while preserving the glenohumeral joint. Fracture of the scapula as a result of partial scapulectomy has not been reported and the use of prosthesis is not required (5). It has been demonstrated that up to 90% of the scapula can be excised with good to excellent function of the forelimb (5,6,7,8). This report is, to the best of our knowledge, the first to describe partial scapulectomy of the caudal aspect of the scapula for the treatment of an osteosarcoma in a dog.

CASE REPORT

A 9-year-old, 33kg, spayed female, mixed breed dog was presented to the Veterinary Teaching Hospital (VTH) Koret School of Veterinary Medicine, The Hebrew University of Jerusalem, with a history of right forelimb lameness and a mass located over the right proximal scapula. The lameness was first noticed by the owners one week prior to presentation and the dog was treated for pain by her referral veterinarian with 2.2 mg/kg Carprofen (Norocarp; Norbrook laboratories, Northern Ireland) p.o. and 3 mg/kg Tramadol HCl (Tramadex; Dexcel, Israel) p.o. for five days.

A firm, fixed and painful, 6 cm diameter subcutaneous mass over the caudal border of the proximal right scapula was found on physical examination at the VTH. A fine needle aspiration was taken from the mass and the right prescapular lymph node. Cytology of the mass was suggestive of a mesenchymal cell tumor and the cytology of the lymph node showed reactive changes. A computerized tomography (CT) scan of the forelimbs and the thorax was performed. A single round 5.0 x 6.0 x 6.5 cm soft tissue mass, containing irregular areas of bone density varying in size, which was attached to the proximal caudal margin of the right scapula, was seen. In addition, there was a localized solid periosteal reaction of the proximal caudal scapula (Figure 1). There was no evidence of metastatic disease in the lung fields.

Partial scapulectomy of the caudal aspect of the scapula was planned as amputation of the forelimb was unaccept-

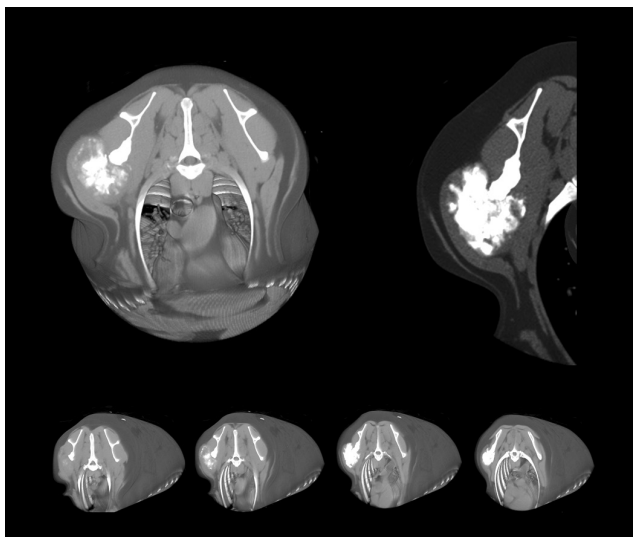


Figure 1: Three dimensional reconstruction of the CT images of the right scapula showing the mass attached to the proximal caudal aspect of the right scapula

able to the client. The dog was premedicated with 0.3 mg/kg morphine (Morphine HCl; Teva, Israel) and 0.02 mg/kg acepromazine (PromAce; Fort Dodge, South Africa) subcutaneously. General anesthesia was induced with 2 mg/kg IV propofol (Lipuro; B-BRAUN, Germany) and 0.5 mg/kg IV diazepam (Valium; TEVA, Israel). The dog was intubated and anesthesia was maintained with isoflurane (Isoflurane; Nicolas piramal, India) in oxygen. Epidural morphine (Morphine HCl; Teva, Israel) was administered after induction of general anesthesia and 25 mg/kg Cefazolin (Cefazolin; Sandoz, Germany) was administered intravenously 10 minutes prior to the skin incision and every 2 hours during surgery.

An elliptical skin incision was made 5cm from the periphery of the tumor. The skin incision was extended through the subcutaneous tissues, *cutaneous trunci* muscle and loose connective tissue until the extrinsic muscles of the forelimb could be identified. The *teres major* muscle and the long head of the *triceps* muscle were identified and cut 5cm distal to the tumor. The origins of the *infraspinatus* muscle and the scapular part of the *deltoid* muscle on the spine of the scapula were then cut and elevated exposing the scapula. These muscles were isolated and cut 5cm distal to the tumor to expose the

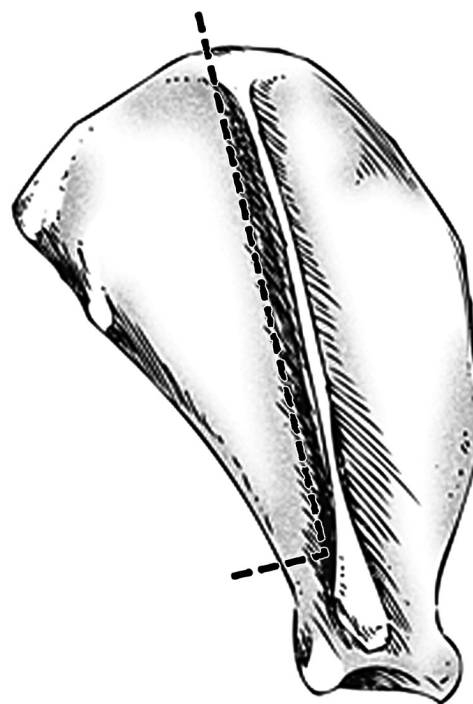


Figure 2: Schematic representation of the location of the osteotomies of the scapula

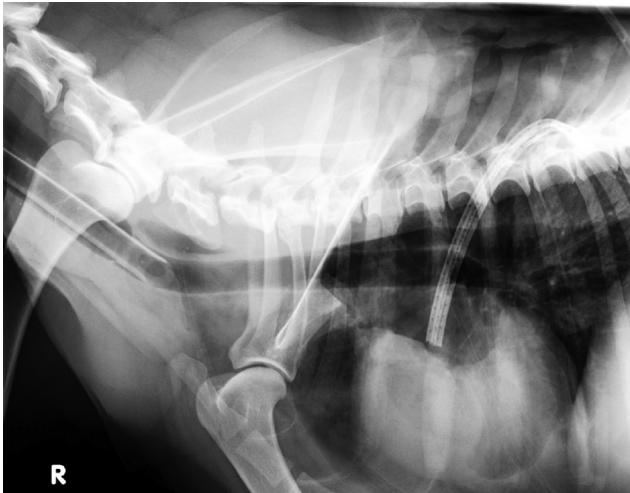

Figure 3: A lateral postoperative radiograph of the scapula showing the defect in the caudal scapula.

neck of the scapula caudal to the spine of the scapula. The neck of the scapula caudal to the spine of the scapula was then cut with an oscillating saw and the scapula was cut caudal and parallel to the spine of the scapula, from the proximal margin of the scapula to the osteotomy of the caudal aspect of the neck of the scapula (Figure 2). The *subscapularis* muscle was identified and cut parallel to the osteotomies of the scapula. The *serratus ventralis* muscle could now be identified and was cut similarly.

The transected ends of the muscles were oversewn with 3-0 polyglyconate (Maxon; Synture, USA) using a simple continuous suture pattern. A Jackson-Pratt drain was placed and the extrinsic forelimb muscles were apposed where possible (Figure 4a). A “soaker” catheter (Contiplex D; B/Braun, Germany) was placed along the incision line and the subcutaneous tissues and skin were closed routinely. The affected limb was then radiographed (Figure 3) and bandaged (Figure 4b).

Postoperative analgesia consisted of a constant rate intravenous infusion of 0.1 mg/kg/h morphine (Morphine HCl; Teva, Israel) and 0.15 mg/kg/h ketamine (Narketan; Vétquinol, France). In addition, 25 mg/kg dipyrone (Vitalgin; Teva, Israel) was administered subcutaneously every 12 hours and bupivacaine (0.5 mg/kg in 2ml saline) (Kamacaine; Kamada, Israel) was administered via the soaker catheter every four hours.

Twelve hours postoperatively the dog was walking with a weight bearing lameness as well as a conscious proprioception (CP) deficit, delayed withdrawal reflex and knuck-

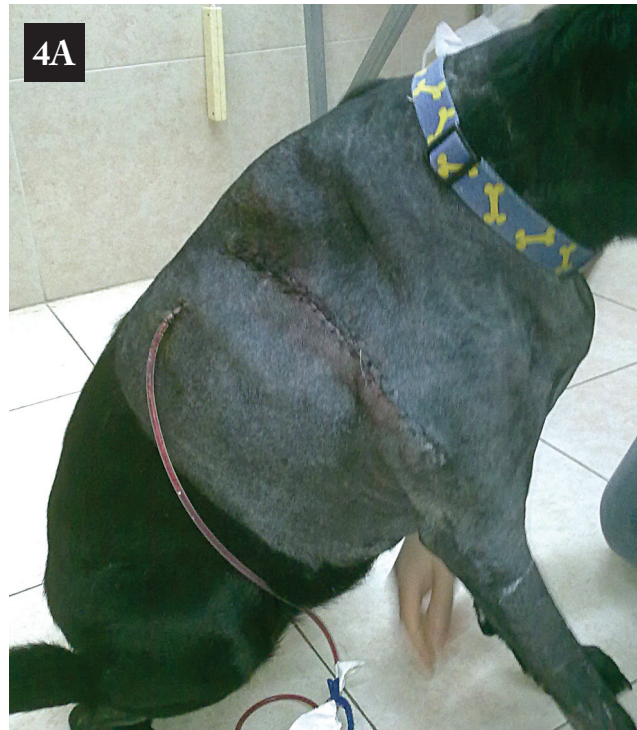

Figure 4a&b: A photograph of the dog three days postoperatively. The drain was removed and the bandage was maintained for two weeks.

ling over of the manus. Thirty six hours postoperatively the neurological deficits resolved and after 2 weeks the dog was walking without lameness.

A diagnosis of chondroblastic osteosarcoma was made on histopathology. The margins thought to be the closest to the tumor were tagged with suture material immediately after the excision of the tumor. These margins were evaluated histologically and were found to be clean.

Adjuvant chemotherapy was initiated two weeks postoperatively, after confirmation of a normal blood count. The protocol described by Kent *et al.* (9) was followed, which includes alternating doses of 300 mg/m² IV carboplatin (Carboplatin; Teva, Israel) and 30 mg/m² IV doxorubicin (Doxorubicin HCl; Pfizer, Israel) administered every 21 days for a total of 3 cycles. Thoracic radiographs, performed 4 months post operatively were within normal limits.

The tumor recurred 8 months after the surgery. A fine needle aspiration of a 1cm diameter mass at the surgery site was consistent with osteosarcoma, and a CT scan of the chest was consistent with metastases to the lungs.

The dog was euthanized, following owners request, 6 weeks later due to respiratory dyspnea.

DISCUSSION

The success of partial scapulectomy of up to 90% of the proximal scapula or 60% of the craniodorsal aspect of the scapula has been reported (5,6,7,8,10). In addition, total scapulectomy has been reported to result in fair limb function (8). Partial scapulectomy is simple, compared to other limb sparing techniques, and wide margins are easily achieved. The use of predrilled holes to reattach muscles to the scapula has been reported; however, this had no beneficial effect on motor function of the limb. (8).

Partial scapulectomy of the caudal aspect of the scapula as described in this report has not been reported, to the best of our knowledge. The rapid recovery and excellent clinical outcome are most likely due to the preservation of the insertion of the *serratus ventralis* muscle and the aggressive analgesic therapy. We were concerned that cutting the *infraspinatus* and *subscapularis* muscles close to their insertions might compromise the stability of the glenohumeral joint. However, the rapid return to function would seem to indicate that the shoulder joint was stable. The potential advantage of preserving muscle attachments should not be at the expense of tumor margins. A larger cranial margin could have been obtained by performing the osteotomy cranial to the spine of the scapula. This would have resulted in a larger cranial margin; however, it is unlikely to have affected the clinical outcome.

The temporary CP deficit and the delayed withdrawal reflex seen in this case are likely due to neuropraxia. The surgical site was close to the brachial plexus and it is probable that the surgical trauma and subsequent inflammation and edema

affected the nerves of the forelimb. The neurologic status returned to normal 36 hours postoperatively, and the dog became sound 2 weeks after surgery. The recovery time seen in this case was quicker than reported previously (5,6,7,8,10).

The disease-free interval for cases of osteosarcoma treated with a combination of amputation, carboplatin and doxorubicin administration has been reported to be 227 days (9) and 202 days (11). In this case, partial scapulectomy reduced pain, allowed full function of the forelimb and resulted in an acceptable disease free interval. Partial scapulectomy, as performed in this report, had an excellent outcome, and is a feasible alternative to forequarter amputation.

REFERENCES

1. Dernell, W.S., Ehrhart, N.P., Straw, R.C. and Vail, D.M.: Tumors of the skeletal system. In: Withrow, S.J. and MacEwen, E.G. (5th ed) Small animal clinical oncology. WB Saunders, Philadelphia. pp. 378-417, 2007.
2. Dernell, W.S.: Limb-sparing surgery for dogs with bone neoplasia. In: Slatter D. (3rd ed): Textbook of small animal surgery. WB Saunders, Philadelphia, pp. 2272-2285, 2002.
3. LaRue, S.M., Withrow, S.J., Powers, B.E., Wrigley, R.H., Gillette, E.L., Schwarz, P.D., Straw, R.C. and Richter, S.L.: Limb-sparing treatment for osteosarcoma in dogs. J. Am. Vet. Med. Assoc. 195:1734-1744, 1989.
4. Straw, R.C., Withrow, S.J. and Powers, B.E.: Management of canine appendicular osteosarcoma. Vet. Clin. North. Am.: Sm. Anim. Pract. 20:1141-1160, 1990.
5. Trout, N., Pavletic, M. and Kraus, K.: Partial scapulectomy for management of sarcomas in three dogs and two cats. J. Am. Vet. Med. Assoc. 207:585-587, 1995.
6. Canapp, Jr.S.O., Mann, F.A., Henry, C.J. and Lattimer, J.C.: The use of latissimus dorsi muscle flap for scapular reconstruction in a cat following fibrosarcoma excision. J. Am. Anim. Hosp. Assoc. 37:283-289, 2001.
7. Erdem, V. and Pead, M.J.: Haemangiosarcoma of the scapula in three dogs. J. Small Anim. Pract. 41:461-464, 2000.
8. Kirpensteijn, J., Straw, R.C., Pardo, A.D., Adams, W.H., Withrow, S.J. and Calhoun, C.S.: Partial and total scapulectomy in the dog. J. Am. Anim. Hosp. Assoc. 30:313-319, 1994.
9. Kent, M.S., Strom, A., London, C.A. and Seguin, B.: Alternating Carboplatin and Doxorubicin as Adjunctive Chemotherapy to Amputation or Limb-Sparing Surgery in the Treatment of Appendicular Osteosarcoma in Dogs. J. Vet. Int. Med. 18:540-544, 2004.
10. Norton, C., Drenen, C.M. and Emms, S.G.: Subtotal scapulectomy as the treatment for scapular tumor in the dog: a report of six cases. Aust. Vet. J. 84:364-366, 2006.
11. Bacon, N.J., Ehrhart, N.P., Dernell, W.S., Lafferty, M. and Withrow, S.J.: Use of alternating administration of carboplatin and doxorubicin in dogs with microscopic metastases after amputation for appendicular osteosarcoma: 50 cases (1999-2006). J. Am. Vet. Med. Assoc. 232: 1504-1510, 2008.