

# First Clinical Case Report of Cryptococcosis in a Dog in Israel

**Gans, Z.**

"Knowledge Farm" Emergency Center, Beit Berl, 44905, Israel

\* **Correspondence:** Dr. Zeev Gans, Zeev Gans VMD, Dipl ABVP; zeev@emergency-veterinary.co.il

## CASE DESCRIPTION

A 2 year old male Cocker spaniel was referred for second opinion with a tentative diagnosis of allergic rhinitis due to sneezing and nasal discharge which persisted over a period of 6 months. Several blood panels were unremarkable and allergy testing (blood serology) was positive to multiple tested antigens. Hyposensitization treatment was not initiated and the dog did not respond to treatment trials with several antibiotics. A few days prior to referral, the dog was initiated on prednisone (Rekah, Holon, Israel) at 0.5 mg/kg PO BID, but developed lethargy, decreased appetite and difficulty in walking. The dog lived in central Israel near the beach and did not have any travel history outside Israel.

On physical examination the dog was quiet but responsive with normal vital signs. The dog was underweight and mildly enlarged submandibular lymph nodes were detected. A bilateral clear nasal discharge was present. On ophthalmological examination the right eye appeared normal but an anterior uveitis was detected in the left eye. A fundic examination was not successful. There were no obvious neurological findings but the dog appeared somewhat disoriented and it was difficult to assess whether the "walking difficulty" was in fact due to mild ataxia or generalized weakness.

The main differential diagnoses for the sneezing and nasal discharge included allergic rhinitis, oronasal fistula, lymphocytic plasmacytic rhinitis and nasal foreign body. Less likely differential diagnoses were considered taking in to account age and prevalence which included neoplasia or fungal infection. The main differential diagnoses for the ocular findings included penetrating foreign body, glaucoma (breed predilection although less likely due to unilateral involvement) or manifestation of systemic disease (infection/neoplasia).

The lymphomegaly was mild and considered to be a result

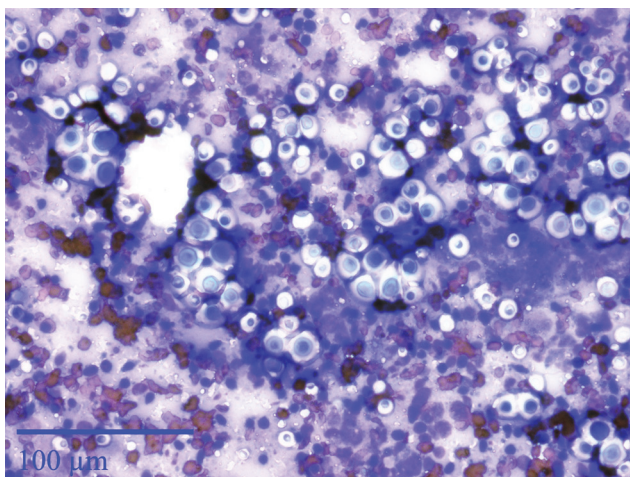
of the weight loss, chronic antigenic stimulation secondary to nasal or dental disease, or secondary to systemic infectious disease or neoplasia.

The lethargy, decreased appetite and weakness were attributed to chronic illness or systemic disease.

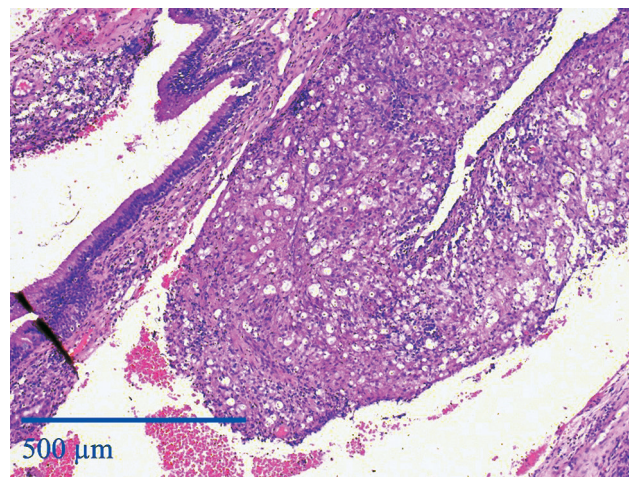
## DIAGNOSIS

The general blood profile (CBC and chemistry) were unremarkable with the exception of a mild hyperglobulinemia (5.3mg/dL (Normal limits 2.5–4.5mg/dL)). Thoracic radiographs were unremarkable. On rhinoscopy moderate, diffuse inflammatory changes were observed throughout the nasal mucosa. Samples were collected for histopathologic evaluation and fine needle aspirates were taken from the submandibular lymph nodes for cytological evaluation (Pathovet, Rehovot, Israel). The dog was referred for ophthalmologic evaluation which revealed a pan-uveitis with retinal detachment in the left eye. Based on the ophthalmological findings the ophthalmologist recommended a systemic etiology. The steroid treatment was ceased and the dog was discharged with topical eye therapy including Diclofenac Sodium (Novartis Pharma, Switzerland) at 1mg/ml, 1 drop OS BID.

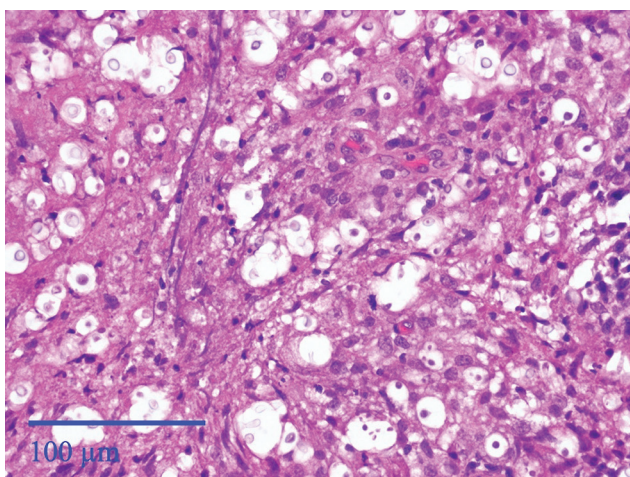
The following day, cytological examination of the submandibular lymph nodes revealed severe cryptococcal infestation (Figure 1). A blood sample for cryptococcal antigen was sent to a commercial laboratory (Antech diagnostics, USA). Based on the findings the dog was initiated on oral Fluconazole (Teva, Israel) at a dose of 6.25 mg/kg body weight BID. Histopathologic examination of biopsies from the mandibular lymph node (Figure 1) and nasal mucosa (Figure 2 and 3) confirmed the diagnosis. Furthermore antigen testing was positive for the organism at 1:101 where greater than 1:2 is considered positive.



**Figure 1:** Histopathologic examination of the biopsy of the submandibular lymph nodes. Note the abundant non-staining capsular material of the cryptococcal fungal organisms leading to a “soap bubble” appearance of the lesion.



**Figure 2:** Histopathologic examination of the biopsy of the nasal mucosa at a lower magnification. Note the presence of many cryptococcal organisms.



**Figure 3:** Histopathologic examination of the biopsy of the nasal mucosa at a higher magnification. Note the presence of many cryptococcal organisms.

## TREATMENT

The dog showed minimal improvement after 8 days of treatment with Fluconazole 6.25mg/kg PO BID. Following the histopathological results confirming the diagnosis, treatment with lipid soluble Amphotericin B (Ambiosome, Gilead Sciences, Inc., Astellas Pharma, USA) was administered intravenously every other day for 10 treatments to a total cumulative dose of 14.3mg/kg. During the treatment period the urine specific gravity remained at 1.034 and the renal function parameters remained within the normal lim-

its. The dog responded clinically, the uveitis, sneezing, nasal discharge and lymphadenopathy resolved. At this stage treatment was continued with Fluconazole at a dose of 6.25mg/kg PO BID.

Despite the resolution of the symptoms, the dog remained depressed and anorexic and presented about a month after initiation of therapy with generalized muscle tremors. The blood glucose level was found to be 41mg/dL. There was a positive response to an IV infusion of 2.5% dextrose. At abdominal ultrasound no abnormalities were detected. As fluconazole and ketoconazole may lead to iatrogenic hypoadrenocorticism it was decided to undertake an ACTH stimulation test which was found to be normal. Treatment of the anorexia was carried out by placing an esophagostomy feeding tube.

After 8 weeks of oral treatment, no systemic clinical change was observed in the dog. Antigen titer was repeated and results were 1:470. At that point the owners elected euthanasia. A post mortem examination revealed a multifocal granulomatous meningoencephalitis with intra-lesional fungal agents consistent with *Cryptococcus*.

## DISEASE DESCRIPTION

Cryptococcosis is the most common of the systemic fungal diseases in cats throughout the world (1). It can infect other mammals but the disease in these species is much less common. The disease is seen in humans mostly under conditions of immune suppression (2, 3, 4). The organisms involved in dis-



ease production are referred to as the *Cryptococcus neoformans*-*Cryptococcus gattii* species complex. *C. gattii* causes disease in healthy individuals, but *C. neoformans* is associated mainly with disease in immune compromised individuals (2, 3). The infection begins in the nasal cavity and can be asymptomatic (4). In some animals colonization (invasion of the epithelium and growth) will result in propagation (clonal expansion) within the nasal cavity with spread of the organism by extension to the lymph nodes, eyes, brain and other systemic sites (4, 5).

Dogs usually exhibit symptoms in more than one organ system (4). Central nervous system (CNS) symptoms are commonly accompanied by malaise (4). Clinical signs depend on the organs involved by the infection and include sneezing, nasal discharge, uveitis, retinitis, lymphadenopathy, cutaneous nodules, coughing, lethargy and weight loss (6). Blindness is seen less commonly in dogs than in cats and gastrointestinal signs are seen more often than in cats (4).

The disease is typically diagnosed in young adult dogs. American cocker spaniels, Doberman pinchers, Great Danes and Labrador retrievers are over represented (5). Increased risk of infection has been associated with increased external activity, pigeon nests, and commercial environmental disturbances (4).

Differential diagnoses depend on the individual's clinical signs and include other fungal infection, neoplasia, rickettsiosis, and Leishmaniasis. Diagnosis is made through cytology, histology, culture and cryptococcal antigen testing. Specimens can be collected from nasal swabs, mass lesions, lymph nodes, CSF, pleural fluid and urine (1). The advantage of cytological examination is the rapidity of results allowing the rule out of neoplasia. However cytological examination does not allow for differentiation between different fungal etiologies. In some studies, 40% of *Cryptococcus* cases were diagnosed based on cytology alone (4). A negative cytological result does not preclude the diagnosis (7). Histological evaluation takes longer but allows for better differentiation between fungal etiologies (8). Culture allows for accurate identification of the fungal organism and sensitivity spectrum to select for the most effective therapy (9). PCR testing is a highly sensitive tool for detection of the organism but is not regarded as a routine clinical tool for diagnosis of this disease (1).

Antigen level is considered the gold standard for the confirmation of cryptococcal infections and allows for moni-

toring response to therapy and determining when to cease treatment (10). The test measures antigen levels of the polysaccharide which surrounds the organism however it does not differentiate between live or dead organism. Antigen levels may increase during the first 6-8 weeks after initiation of therapy, due to release of antigen into the circulation after fungal decomposition (4).

Patients with CNS involvement should be treated with Amphotericin B as this drug is fungicidal and penetrates the CNS (11). Amphotericin B is considered highly nephrotoxic and patients undergoing treatment may develop temporary or permanent renal dysfunction (1). Lipid soluble Amphotericin is considered about 8 times less nephrotoxic than regular Amphotericin but the cost of the drug can be prohibitive (11). Patients should have their urine specific gravity and renal blood parameters monitored throughout the treatment period. In patients without CNS signs, treatment may include Amphotericin B, Fluconazole, Itraconazole or Ketoconazole. In the absence of culture and sensitivity results, fluconazole is considered the drug of choice (12). Flucytosine, a synthetic antimycotic drug may act in synergy with other anti-fungal drugs and improve their penetration to the CNS, but has been associated with a severe cutaneous drug reaction in dogs (1). The use of glucocorticoids has been associated with high mortality and should be avoided. Treatment duration of 1-2 years is recommended until 2 consecutive negative antigen tests are achieved one month apart (13).

The prognosis for dogs which survive the initial month of therapy is good and despite the extended treatment, they enjoy a good quality of life during the treatment period (4, 5). CNS involvement and chronicity of disease are associated with a poor prognosis (4).

## DISCUSSION

The care of this patient left a few unanswered issues: After 3 weeks of treatment the dog presented with hypoglycemia, which is not a typical finding of the disease. Initially the hypoglycemia was attributed to the anorexia and poor body condition of the dog. Despite the fact that the dog remained asymptomatic, blood glucose levels persisted under at 70mg/dL even after placement of an esophageal feeding tube and tube feeding based on appropriate caloric calculations. On abdominal ultrasound scan (and later post mortem exami-

nation) there were no abnormal findings along the gastrointestinal tract to justify malabsorption. Adrenal function test ruled out the presence of atypical hypoadrenocorticism.

Follow up antigen titer levels 8 weeks after initiation of therapy, revealed an almost 5 fold increase. Since no interim titer was checked it is impossible to tell whether the cryptococcal antigen level was higher earlier and began to drop, or whether the level continued to rise due to treatment failure. The dog's lack of systemic improvement and rise in antigen titer level discouraged the owners who elected for euthanasia.

Treatment failure in this dog could have resulted from several causes. First this case was chronic (the dog was already symptomatic 4 months prior to diagnosis) and second the dog had CNS involvement. These are two major negative prognostic factors present in this case. Due to financial considerations treatment with lipid soluble Amphotericin was given to the minimal cumulative dose suggested, it is possible that a higher dose would have had a better outcome. Last it is possible that the treatment was in fact effective but was not continued long enough. Unfortunately, the severity of clinical disease coupled with the increasing antigen titer allowed for the owners to prefer euthanasia.

To the best of the knowledge of the author this is the first reported case of cryptococcal infection in a dog in Israel.

## REFERENCES

1. Sykes, J.E. and Malik, R.: Cryptococcosis, In Greene, C.E. (ed), *Infectious diseases of the dog and cat*, 4<sup>th</sup> edition Elsevier Saunders, St. Louis, Missouri. pp. 621-634, 2012.
2. Kwon-Chung, K.J., Boekhout, T., Fell, J.W. and Diaz, M.: Proposal to conserve the name *Cryptococcus gattii* against *C. honduricus* and *C. bacillisporus* (Basidiomycota, Hymenomycetes, Tremellomycetidae). *Taxon*. 51:804-806, 2002.
3. Bovers, M., Hagen, F. and Boekhout, T.: Diversity of the *Cryptococcus neoformans*-*Cryptococcus gattii* species complex. *Rev. Iberoam. Micol.* 25:S4-S12, 2008.
4. Lester, S.J., Malik, R., Bartlett, K.H. and Duncan, C.G.: Cryptococcosis: update and emergence of *Cryptococcus gattii*. *Vet. Clin. Pathol.* 40: 4-17, 2011.
5. Malik, R., Dill-Macky, E. and Martin, P., Wigney, D.I., Muir, D.B. and Love D.N.: Cryptococcosis in dogs: a retrospective study of 20 consecutive cases. *J. Vet. Med. Mycol.* 33:291-297, 1995.
6. Berthelin, C.F., Bailey, C.S., Kass, P.H., Legendre, A.M. and Wolf, A.M.: Cryptococcosis of the nervous system in dogs: Part 1: Epidemiologic, clinical, and neuropathologic features. *Prog. Vet. Neurol.* 5:88-97, 1994.
7. Foster, S.F., Charles, J.A., Parker, G., Krockenburger, M., Churcher, R.M. and Malik, R.: Cerebral cryptococcal granuloma in a cat. *J. Feline Med. Surg.* 2:201-206, 2000.
8. Krockenberger, M.B., Canfield, P.J., Kozel, T.R., Shinoda, T., Ikeda, R., Wigney, D.I., Martin, P., Barnes, K. and Malik, R.: An immunohistochemical method that differentiates *Cryptococcus neoformans* varieties and serotypes in formalin-fixed paraffin-embedded tissues. *Med. Mycol.* 39:523-533, 2001.
9. Dimech, W.J.: Diagnosis, identification and epidemiology of *Cryptococcus neoformans* infection. *Aust. J. Med. Lab. Sci.* 12:13-21, 1990.
10. Malik, R., McPetrie, R., Wigney, D., Craig, A.J. and Love, D.H.: A latex cryptococcal antigen agglutination test for diagnosis and monitoring of therapy for cryptococcosis. *Aust. Vet. J.* 74:358-364, 1996.
11. Krawiec, D.R., McKiernan, B.C., Twardock, A.R., Kurowsky, L.K. and Marks, C.A.: Use of amphotericin B lipid complex for treatment of blastomycosis in dogs. *J. Am. Vet. Med. Assoc.* 209:2073-2075, 1996.
12. Kerwin, S.C., McCarthy, R.J., VanSteenhouse, J.L., Partington, B.P. and Taboada, J.: Cervical spinal cord compression caused by cryptococcosis in a dog: successful treatment with surgery and fluconazole. *J. Am. Anim. Hosp. Assoc.* 34:523-526, 1998.
13. Jacobs, G.J., Medleau, L., Calvert, C.C. and Brown, J.: Cryptococcal infection in cats: factors influencing treatment outcome, and results of sequential serum antigen titers in 35 cats. *J. Vet. Intern. Med.* 11:1-4, 1997.