

Expression of Nectin-4 in Canine Mammary Carcinomas

Dolu, H.¹ and Aydogan, A.^{2*}

¹University of Mehmet Akif Ersoy, Faculty of Veterinary Medicine, Department of Pathology, 15030 Burdur, Turkey.

²University of Çukurova, Faculty of Ceyhan Veterinary Medicine, Department of Pathology, 01930, Adana, Turkey.

* **Corresponding author:** Assoc. Professor Ahmet AYDOGAN, DVM, PhD, University of Çukurova, Faculty of Ceyhan Veterinary Medicine, Department of Pathology, 01930, Adana, Turkey. Telephone: +90 322 6133507, Email: aaydogan79@gmail.com

ABSTRACT

In this research, 30 canine mammary tumor tissues which were diagnosed as tubulopapillary carcinoma and complex carcinoma were used. The routine avidin-biotin-peroxidase complex method (ABC) was applied for detection of Nectin-4, Proliferating Cell Nuclear Antigen (PCNA) and Ki-67 in these tissues. The results were analyzed comparatively and evaluated semi-quantitatively. Immunohistochemically, Nectin-4 was expressed in the plasma membrane and cytoplasm of malignant tumor cells. Statistically, positive, linear and a high correlation was observed between Nectin-4, PCNA and Ki-67 expressions. For this reason, it has been concluded that Nectin-4 may be of significant prognostic value relating to malignancy in canine mammary carcinomas.

Keywords: Canine Mammary Carcinomas; Immunohistochemistry; Nectin-4; PCNA; Ki-67.

INTRODUCTION

Canine mammary cancers are the most common cancer type in female dogs. Approximately half of the mammary tumors in dogs are malignant and most of them are classified as carcinomas. Canine mammary cancers are end stage of a histological process with clinical and pathological similarities to human mammary carcinogenesis (1-2). Even though a reduced incidence is seen as a result of ovariohysterectomy, the canine mammary cancers are still the leading cause of cancer related death cases in female dogs (3). Hence, there is an important need for novel biomarkers and reliable prognostic indicators for better diagnosis and prognosis of canine mammary cancers (1, 3).

Nectins are members of the immunoglobulin superfamily and are components of adherens junctions in epithelial cells (4) and classified as a type I transmembrane glycoprotein (5). There are four members of this group, Nectin-1, -2, -3 and -4, which are ubiquitously expressed in adult tissue with the exception of Nectin-4, which is mainly expressed during embryogenesis. The normal mammary gland lacks expression of Nectin-4 and it is over expressed both in breast tumor cells

lines and human mammary tumors (4, 6-7). Recent studies have shown that Nectin-4 is a valuable and new tumor associated-biomarker to determine tumor progression and metastatic status of patients. It plays an important role in cancer cell growth and invasion, and may be a potential target for the development of therapeutic agents as well as a novel tissue biomarker especially for lung and mammary cancers (7-8). In spite of the recent studies of Nectin-4 expressions in human cancer, its use and significance in canine mammary carcinomas has not been yet fully described.

The current study is aimed at testing immunohistochemically Nectin-4 as a potential biomarker in canine mammary carcinomas.

MATERIALS AND METHODS

In this study, 30 collected canine mammary tissue samples obtained from female dogs and previously diagnosed as adenocarcinoma according to World Health Organization (WHO) – Armed Forces Institute of Pathology (AFIP) classification criteria (1) at the Department of Pathology, Faculty of Veterinary Medicine, Mehmet Akif Ersoy University

(Burdur, Turkey) between 2008 and 2014 were used. The tissue samples had been taken from dogs of different breeds and ages (between 3 and 17 years of age). For histopathological examination, tissue samples were processed routinely for light microscopy. 5µm sections were taken from paraffin embedded tissues, stained routinely with haematoxylin-eosin (HE) and examined microscopically.

Selected the paraffin embedded sections were stained immunohistochemically using routine avidin-biotin-peroxidase complex method (ABC) according to the manual provided by the manufacturer [avidin-biotin peroxidase complex, Abcam Rabbit Specific HRP/DAB detection IHC Kit, ab64261, Cambridge, UK]. As primary antibodies, Nectin-4 [Biorbyt, Rabbit Polyclonal Anti-Nectin-4, orb5809, Cambridge, UK (1:100 and 1:500 dilutions)]; proliferating cell nuclear antigen (PCNA) [Abcam, Rabbit Polyclonal Anti-PCNA, ab2426, Cambridge, UK (1:500 dilution)] and Ki-67 [Abcam, Rabbit Polyclonal Anti-Ki 67, ab15580, Cambridge, UK (1:200 dilution)] were used. The color was improved with a 3,3'-diaminobenzidine tetrahydrochloride substrate kit [Abcam, Cambridge, UK, (ab64238)]-H₂O₂. All sections were counterstained with Mayer's haematoxylin, washed in water, and cover slips were applied with mounting media.

Semi-quantitative data analysis was performed with scores ranging from '-' for negative staining to '+' (1-25%), '++' (26-50%) and '+++' (>51%) for weak, moderate and strong cytoplasmic staining of Nectin-4, respectively. Staining index of PCNA and Ki-67 were evaluated by counting positive and negative nuclei (minimum 1000 neoplastic cells) in representative high-power fields. Every brown stained nucleus was considered positive. The proportion of positive neoplastic cells in each sample was calculated. PCNA and Ki-67 expressions were assessed as follows: '-' negative (≤5% positive cells), '+' weak (5% - ≤25% of positive cells), '++' moderate (>25% - ≤50% of positive cells) and '+++' strong (>50% of positive cells). The primary antibody was omitted for negative controls. For positive control, human placental tissue expressing for Nectin-4 was used. In addition, non-tumoral areas served as internal positive controls on every slide for PCNA and Ki-67 and specificity of primary markers was confirmed.

Statistical analysis

All statistical analyses were performed with Statistical Package for Social Science (SPSS) version 22.0 (SPSS Inc., Chicago, IL, USA, 2014). In these analyses, 30 canine

mammary carcinoma cases were used. Nectin-4, PCNA and Ki-67 expressions were compared in these cases. Results were analyzed by Cronbach's alpha test to assess the reliability. The Kolmogorov-Smirnov test was used for determine whether the groups provided parametric test hypotheses. The correlation of relationship between the used markers was analyzed by Spearman's correlation test. Correlation was significant at the <0.01 level (2-tailed test).

RESULTS

Tumors were reclassified according to World Health Organization (WHO) - Armed Forces Institute of Pathology (AFIP) classification criteria (1). A total of 30 canine mammary cancers in which 43.33% were tubulopapillary carcinoma (13 cases) and 56.66% complex carcinoma (17 cases) were diagnosed. In addition, the correlation of Nectin-4 with PCNA and Ki67, as proliferation markers, was analyzed by immunohistochemistry.

Histopathologically, in the case of the tubulopapillary carcinoma, proliferation of neoplastic luminal epithelial cells with or without papillary projections was seen in tumoral areas (Figure 1). Anaplastic epithelial cells lining the tubules ranged in size and shape from round to cylindrical. In these cells, anisonucleosis, anisocytosis and hyperchromasia were determined. In addition, moderate mitotic activity was detected in these cases.

In complex carcinoma cases, malignant tubular epithelial and intertubular spindle shaped myoepithelial cell proliferations were observed. In these cases, luminal epithelial cells were found to form tubulopapillary structures. Pleomorphism was quite prominent in luminal epithelial cells forming tubulopapillary structures and intertubular spindle shaped myoepithelial cells. Moderate to high rates of mitotic activity were detected in these cases.

Immunohistochemically, Nectin-4 was abundantly expressed in the plasma membrane and cytoplasm of malignant tumor cells (Figure 2, 3). However, there was no or limited expression of Nectin-4 in non-cancer areas of sections (Figure 4). Immunohistochemical staining in the plasma membrane and cytoplasm for Nectin-4 revealed strong (+++) staining in eight cases, moderate (++) staining in four cases, and weak (+) staining in one case for tubulopapillary carcinomas; strong (+++) staining in 11 cases, moderate (++) staining in four cases, and weak (+) staining in two cases for complex carcinomas.

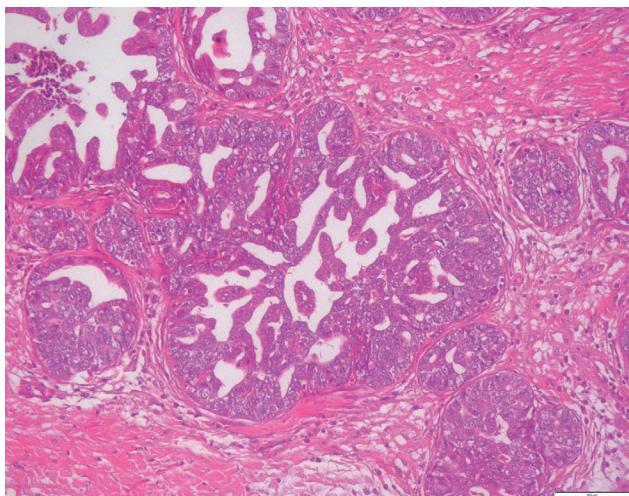


Figure 1: Tubulopapillary carcinoma. Proliferation of neoplastic luminal epithelial cells with papillary projections. HE, bar=50 µm.

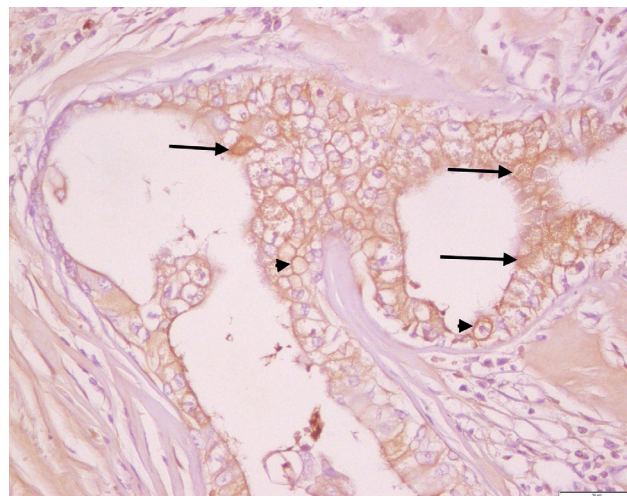


Figure 2: Tubulopapillary carcinoma. Immunohistochemical expression of Nectin-4 in the plasma membrane (arrowheads) and cytoplasm (arrows) of malignant tumor cells. ABC method, Mayer's haematoxylin counterstain, bar=50 µm.

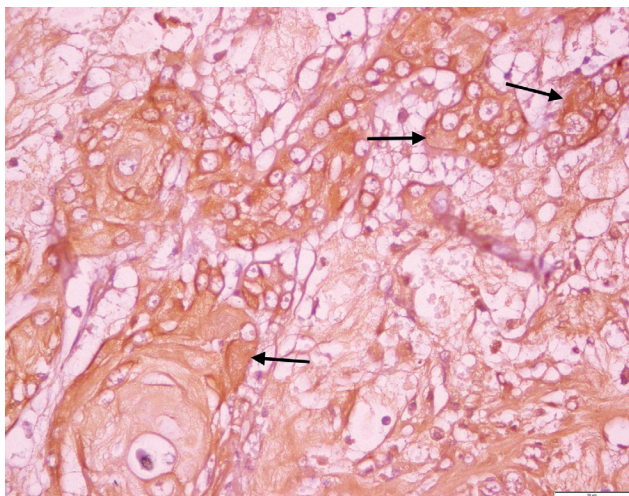


Figure 3: Complex carcinoma. Immunohistochemical staining for Nectin-4 in the plasma membrane and cytoplasm (arrows) of malignant tumor cells. ABC method, Mayer's haematoxylin counterstain, bar=50 µm.

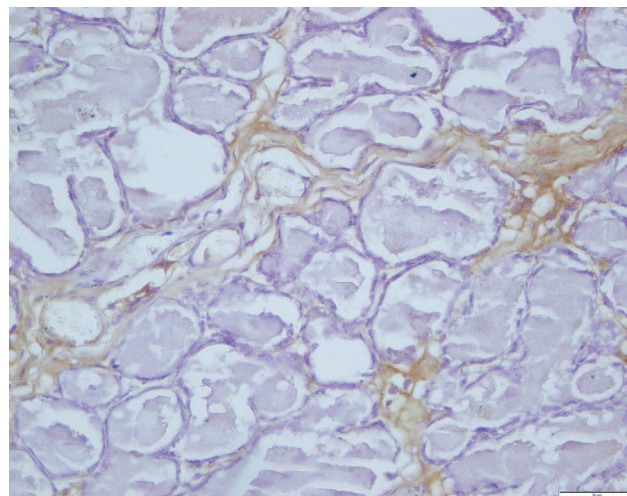


Figure 4: Non-cancer areas for internal positive control. Negative expression of Nectin-4. ABC method, Mayer's haematoxylin counterstain, bar=50 µm.

Nuclear immunopositivity of PCNA gave a strong signal in eight cases (Figure 5), a moderate signal in three cases and a weak signal in two cases for tubulopapillary carcinomas; a strong signal in ten cases, a moderate signal in three cases, a weak signal in three cases and negative in one case for complex carcinomas.

Nuclear immunoreactivity of Ki-67 was weak in seven cases and negative in six cases for tubulopapillary carcinomas; moderate in one case, weak in nine cases and negative in seven cases for complex carcinomas.

A reliability statistics result of Cronbach's alpha test was found as 0.85. This value is in the range of 0.8-1 and evaluated as very high reliability. Tumor types were found to be having a non-parametric distribution using the Kolmogorov-Smirnov test. The results from the Spearman correlation analysis are shown in Table 1. Correlation coefficients between the primary markers were found in the range of 0.70-0.89. A linear and high correlation was detected between Nectin-4, PCNA and Ki-67 according to Spearman's correlation test.

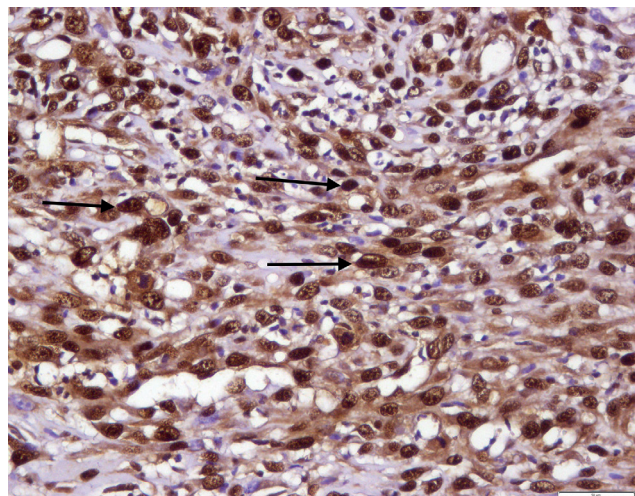


Figure 5: Complex carcinoma. Nuclear immunopositivity of PCNA in malignant tumor cells (arrows). ABC method, Mayer's haematoxylin counterstain, bar=50 μ m.

DISCUSSION

Mammary cancer is one of the most common malignancies in dogs and the incidence rate has been estimated at 198/100,000 (1). Mammary cancers are known as a heterogeneous disease at the molecular level (7). Identification of new molecular tumor associated biomarkers can be useful to improve the detection, diagnosis, prognosis, follow-up and therapy of mammary carcinoma in human and dogs (1, 7, 9). In our study, we studied immunohistochemical expression of Nectin-4 and compared it with proliferation markers (PCNA and Ki-67) in canine mammary carcinoma cases.

Nectins are newly characterized, both homophilic and heterophilic cell adhesion molecules that bind afadin, an actin filament (F-actin)-binding protein (4, 10). They can regulate many cellular activities such as movement, differentiation, polarization, and the entry of viruses, in cooperation with other cell adhesion molecules and cell surface membrane receptors (4, 10). Normally, Nectins -1, -2 and -3 reveal strong expression in adult tissues, but nectin-4 is primarily expressed in the embryo and the placenta. Nectin-4 is considered a specific tumour-associated marker in association with the normal mammary gland which lacks nectin-4 expression (7, 10).

Activation of Nectin-4 is an essential contributor to the cell growth and highly malignant phenotype of tumors (8). Previous studies have shown that nectin-4 is a valuable marker for evaluating tumor progression and the metastatic status of carcinomas (7-8). However, there are only limited studies on Nectin-4 in tumor biology and clinical cancers

Table 1: Spearman's rho correlation between Nectin-4, PCNA and Ki-67.

	Nectin-4	PCNA	Ki-67
Correlation Coefficient (rho)	1.000	0.722*	0.719*
Nectin-4 Sig. (2-tailed)	-	<0.0001	<0.0001
N	30	30	30
Correlation Coefficient (rho)	0.722*	1.000	0.884*
PCNA Sig. (2-tailed)	<0.0001	-	<0.0001
N	30	30	30
Correlation Coefficient (rho)	0.719*	0.884*	1.000
Ki-67 Sig. (2-tailed)	<0.0001	<0.0001	.
N	30	30	30

* Correlation was significant at the 0.01 level (2-tailed test).

especially in veterinary medicine. Nectin-4 has been shown to be a specific and potential tumor-associated biomarker for ductal mammary carcinoma in humans, lung adenocarcinoma in humans, pancreatic cancer in humans, ovarian carcinoma in humans and enzootic nasal adenocarcinoma of small ruminants (7-8, 11-12).

In this study, the intense immunohistochemical expression of Nectin-4 was found in most canine mammary carcinoma tissues especially in the plasma membrane and cytoplasm of malignant tumor cells. However, Nectin-4 expression was not observed in non-cancer areas of sections. This finding suggests that Nectin-4 can be used as a valuable tumour-associated biomarker in the diagnosis of canine mammary carcinomas.

In different studies, PCNA and Ki-67 are used as reliable proliferation and prognostic markers in human and canine mammary tumors (13-15). In a comparative study of PCNA and Ki-67, PCNA expressions have been reported as more intense than Ki-67 expressions in canine mammary tumors (16). In the present study, correlation of Nectin-4 with PCNA and Ki-67 is analyzed by immunohistochemistry. As a result, a linear and high correlation was found between Nectin-4, PCNA and Ki-67 expressions in canine mammary carcinomas. Thus, we propose that Nectin-4 can be used as a prognostic biomarker for canine mammary carcinomas.

In conclusion, in this study, the expression and localization of Nectin-4 and its comparison with other prognostic markers such as PCNA and Ki-67 were demonstrated in the canine mammary carcinoma tissues. Although, Nectin-4 is used for development of a new therapy for canine mammary cancers with measles virus (17), further studies are needed for

better understand the role of Nectin-4 in canine mammary carcinomas.

ACKNOWLEDGEMENTS

This paper is a summary of MSc thesis and was supported by Mehmet Akif Ersoy University Scientific Research Fund (Project no: 0285-YL-16).

REFERENCES

- Misdorp, W.: Tumors of the Mammary Gland. In: Meuten, D.J. (Ed.): Tumors in Domestic Animals. 4 th Edit., Iowa State Press, Iowa, 575-599, 2002.
- Sorenmo, K.U., Kristiansen, V.M., Cofone, M.A., Shofer, F.S., Breen, A.M., Langeland, M., Mongil, C.M., Grondahl, A.M., Teige, J. and Goldschmidt, M.H.: Canine mammary gland tumours; a histological continuum from benign to malignant; clinical and histopathological evidence. *Vet. Comp. Oncol.* 7: 162-172, 2009.
- Sleeckx, N., de Rooster, H., Veldhuis Kroeze, E.J., Van Ginneken, C. and Van Brantegem, L.: Canine mammary tumours, an overview. *Reprod. Domest. Anim.* 46: 1112-1131, 2011.
- Takai, Y., Miyoshi, J., Ikeda, W. and Ogita, H.: Nectins and nectin-like molecules: roles in contact inhibition of cell movement and proliferation. *Nat. Rev. Mol. Cell. Biol.* 9, 603-615, 2008.
- Morrison, M.E. and Racaniello, V.R.: Molecular cloning and expression of a murine homolog of the human poliovirus receptor gene. *J. Virol.* 66: 2807-2813, 1992.
- Kurita, S., Ogita, H. and Takai, Y.: Cooperative role of nectin-nectin and nectin-afadin interactions in formation of nectin-based cell-cell adhesion. *J. Biol. Chem.* 286, 36297-36303, 2011.
- Fabre-Lafay, S., Monville, F., Garrido-Urbani, S., Berruyer-Pouyet, C., Ginestier, C., Reymon, N., Finetti, P., Sauvan, R., Adelaide, J., Geneix, J., Lecocq, E., Popovici, C., Dubreuil, P., Viens, P., Gonçalves, A., Charafe-Jauffret, E., Janquemier, J., Birnbaum, D. and Lopez, M.: Nectin-4 is a new histological and serological tumor associated marker for breast cancer. *BMC Cancer.* 7: 73, 2007.
- Takano, A., Ishikawa, N., Nishino, R., Masuda, K., Yasui, W., Inai, K., Nishimura, H., Ito, H., Nakayama, H., Miyagi, Y., Tsuchiya, E., Kohno, N., Nakamura, Y. and Daigo, Y.: Identification of Nectin-4 Oncoprotein as a Diagnostic and Therapeutic Target for Lung Cancer. *Cancer Res.* 69: 6694-6703, 2009.
- Baselga, J. and Norton, L.: Focus on breast cancer. *Cancer Cell.* 1:319-322, 2002.
- Reymond, N., Fabre, S., Lecocq, E., Adelaide, J., Dubreuil, P. and Lopez, M.: Nectin4/PRR4, a new afadin-associated member of the nectin family that trans-interacts with nectin1/PRR1 through V domain interaction. *J. Biol. Chem.* 276: 43205-43215, 2001.
- Derycke, M.S., Pambuccian, S.E., Gilks, C.B., Kalloger, S.E., Ghidouche, A., Lopez, M., Bliss, R.L., Geller, M.A., Argenta, P.A., Harrington, K.M. and Skubit, A.P.: Nectin 4 over expression in ovarian cancer tissues and serum: potential role as a serum biomarker. *Am. J. Clin. Pathol.* 134: 835-845, 2010.
- Aydoğan, A. and Özmen, Ö.: Expression of Nectin-4 as a potential biomarker in Enzootic Nasal Adenocarcinoma of goats. *Acta Vet. Hung.* 64: 71-77, 2016.
- Filizel, F., Ertek, S., İlvan, Ş., Calay, Z., Oruç, N. and Bakır, S.: Meme karsinomlarında proliferating cell nuclear antigen in (PCNA) prognostikönemi. *Turkish J. Pathol.* 12- 1, 50-52, 1996.
- Trihia, H., Murray, S., Price, K., Gelber, R.D., Golouh, R., Goldhirsch, A., Coates, A.S., Collins, J., Castiglione-Gertsch, M. and Gusterson, B.A.: Ki-67 Expression in Breast Carcinoma: its association with grading systems, clinical parameters, and other prognostic factors-a surrogate marker? *Cancer.* 97, 5, 1321-1331, 2003.
- Zuccari, D.A.P.C., Pavam, M.V., Terzian, A.C.B., Pereira, R.S., Ruiz, C.M. and Andrade, J.C.: Immunohistochemical evaluation of e-cadherin, Ki-67 and PCNA in canine mammary neoplasias: Correlation of prognostic factors and clinical outcome. *Pesq. Vet. Bras.* 28, 207-215, 2008.
- Pena, L.L., Nieto, A.I., Perez-Alenza, D., Cuesta, P. and Castaño, M.: Immunohistochemical detection of Ki-67 and PCNA in canine mammary tumors: relationship to clinical and pathologic variables. *J. Vet. Diagn. Invest.* 10, 3, 237-246, 1998.
- Shoji, K., Yoneda, M., Fujiyuki, T., Amagai, Y., Tanaka, A., Matsuda, A., Ogihara, K., Naya, Y., Ikeda, F., Matsuda, H., Sato, H. and Kai, C.: Development of new therapy for canine mammary cancer with recombinant measles virus. *Mol. Ther. Oncolytics.* 3:15022, 2016.