

Fowlpox Vaccination by Subcutaneous Injection, as an Alternative to the Wing Web Stab Application in Large Commercial Poultry Farms. A Field Clinical Study-Israel

Chen, T¹., Krispin, H². and Perelman, B.³

¹Poultry Veterinarian – Clinical Consultant, Mabuim, Israel

²Poultry Veterinarian – Yavne Hatchery, Kibbutz Yavne, Israel

³Poultry Veterinarian – Clinical Consultant, Kibbutz Beit Kama, Israel

* **Corresponding Author:** Dr. Tal Chen, Mabuim 93, D.N. Negev, Israel.

ABSTRACT

Fowlpox (FP) is an enzootic viral disease that infects domestic and wild birds globally. Although commercial poultry flocks have been vaccinated since the beginning of the last century, reports of outbreaks of the disease in vaccinated flocks have been accumulating, mainly in recent years. There are several hypotheses regarding the causes of fowl pox vaccine failure, but no re-examination of the process of vaccination in today's commercial flocks has been reported. After several cases of vaccination failure in vaccinated flocks, the authors of the article identified a critical problem with the conventional wing web (WW) stab vaccination method. A primary feasibility study was followed by a series of controlled field studies comparing the safety and efficacy of the traditional vaccination method of WW stab to the subcutaneous injection. The subcutaneous application was tested using a one dose per bird in different volumes. The studies were carried out in commercial rearing farms for layers and heavy breeders in Israel. The controlled field studies under commercial conditions included more than 20,000 birds. The results demonstrated that vaccination of pox vaccine by subcutaneous injection is completely safe, much faster, and more reliable than the WW stab vaccination method, providing a better and uniform immune response and protection and should be considered as an optional method for Fowlpox vaccination in large commercial poultry flocks.

Keywords: Fowlpox; Vaccination; Vaccination Failure; Wing Web Stab; Subcutaneous.

INTRODUCTION

Fowlpox (FP) Is an enzootic viral disease known for many years, and one of the earliest diseases studied due to the relative ease of isolation and identification of the virus (1, 2, 3). Fowlpox is widespread globally in domestic and wild birds (4, 5, 6), and characterized by two clinical forms: cutaneous and diphtheric (7). Avian pox viruses (APVs) multiply in the epithelial cells cytoplasm, forming large typical cytoplasmic inclusion bodies (Bollinger bodies), causing hyperplasia, hypertrophy, degeneration and death of the infected cells (8, 9). If the multiplication takes place in the epidermis,

the cutaneous manifestations are obtained, but when the pox virus replicates in the respiratory or the digestive tract epithelium, the diphtheric pathological signs are observed. The cutaneous manifestations are considered relatively mild and characterized by multifocal proliferative skin nodules that appear mainly in non-feathered skin areas in the face and head (10). The cutaneous lesions are usually not fatal, but may cause severe stress caused by the disease itself, in the form of cutaneous pox may affect the eyes, beak and mouth decreasing the ability of the affected birds to eat and drink. In contrast, the diphtheric manifestation is considered

severe and is characterized by proliferative necrotic lesions in the mucosal layer lining the respiratory and digestive systems, which lead to severe ulceration, hemorrhage, lumen obstruction, and secondary bacterial infections as the disease progresses (11).

Infection occurs by direct contact, swallowing or inhalation of contaminated dust or aerosol and by mechanical transmission (12, 13, 14). In commercial flocks the disease is characterized by a relatively slow rolling course, causing impaired performance (decreased growth and reduced egg production) and death. In severe cases the mortality ranges between 15-50% and is more severe in young birds. The incidence and severity of the disease varies between geographic areas depending on the climate (more common in tropical and subtropical climates), thus correlating with mechanical transmission by arthropods, housing, hygiene, and vaccination protocols (15).

Fowlpox Virus (FPV) belongs to the Poxviridae family and to the genus Avipoxvirus (16, 7), which currently includes 10 taxonomic species: canarypox, fowlpox, junco-pox, mynah-pox, pigeon pox, psittacine pox, quail pox, sparrow pox, starling pox and turkey poxviruses (17). FPV is a large, enveloped virus, which contains a double stranded DNA genome with a length of about 280kb (18) that encodes more than 250 genes (15). It is environmentally resistant compared to other enveloped viruses, possibly due to the presence of genes that protect the virus from environmental damage (19, 20). Even though it was one of the earliest studied avian viruses, much knowledge is still lacking regarding the phylogenetic relationships between Avipoxviruses (APVs), as well as regarding their host specificity. However, several phylogenetic studies show that the majority of APVs are host specific, and only a few can infect and cause disease in different species (21, 22, 23, 24).

In terms of immunity, there seems to be a good cross protection between some species (Fowlpox-Turkey pox-Pigeon pox), as a result of some conserved genes among APVs (15). It is interesting to note that integration of active Reticuloendotheliosis Virus (REV) pro-viral sequences into the FPV genome can be found in most field viruses, while in the vaccine strains there are only remnants of long terminal repeats (25, 26), the sequences of which are considered to be related to virulent characteristics of the virus.

APV vaccines were already developed by the end of

1920's (27). In fact, a vaccine against the disease was reported in the literature as early as 1928, using two APV species- FPV and pigeon pox (28), which today are related as antigenically similar species (29). Those vaccine strains, that were developed in that early period, are still the source of most of the vaccine strains commonly used today (over 70 commercial live attenuated vaccines). Therefore, knowledge about the exact origin of the strains, their attenuation process, and the relationships between them is extremely limited (29).

Development of recombinant vaccines based on FPV (rFPVs) began in the 1980's (30), and in the early 1990's rFPVs containing antigenic determinants of Newcastle Disease (ND) and Avian Influenza (AI) which were already registered in the USA (31, 32, 33).

Live attenuated vaccines against avian pox disease are widely used all over the world. According to the guidelines of the O.I.E. and commercial companies, Pox vaccines can be given by injection *in ovo* or to the chick after hatching (subcutaneous injection in the back of the neck) or by the wing web stab (WW) method on the farms. Testing for proper application of the vaccine given by the WW puncture method is based on the detection of a "Take" – (the appearance of a characteristic skin swelling or scab at the stab site about 5-10 days after the vaccination-OIE Terrestrial Manual (2018) (15). The duration of the protection induced by the vaccine probably includes a cellular and humoral response, is estimated to last 6-12 months after vaccination. Regarding other vaccination methods, mass vaccination in water or by aerosol administration was tested in several studies and was not shown to produce satisfactory results (34, 35).

Despite the extensive use of Pox vaccines, there are reports of outbreaks in commercial flocks vaccinated with the standard commercial vaccines (25, 26, 36, 37). In Israel, all light and heavy pullets are vaccinated during the rearing period once or twice against APV, using commercial attenuated vaccines given by WW stab application at different ages from 12 days to 15 weeks of age according to the vaccination programs used. Despite vaccination, in farms that maintain low biological safety (layers and turkeys flocks) or suffer from immunosuppression or stress (during molting), acute or chronic rolling outbreaks of Fowlpox occur (mainly in the dry form) (Fig 1, Fig 2), causing a serious welfare problem and damage to the flock's performance.

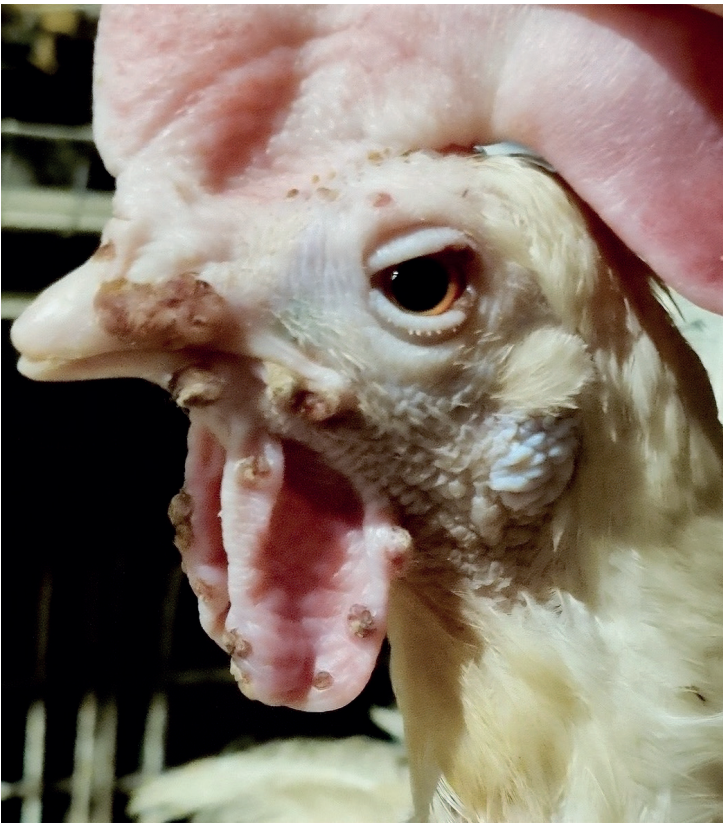

Figure 1. Cutaneous Pox lesions in layer hen vaccinated at 14 days old and 7 weeks, by the WW stab method




Figure 2. Cutaneous Pox lesions in a heavy breeder hen vaccinated at 5 weeks and 12 weeks by the WW stab method

Due to the lack of knowledge regarding phylogenetic relationships in the APV group, one of the hypotheses regarding the cause of the vaccine failure is heterology between the vaccine and field strains (25). According to this assumption, the heterology between vaccine and field strains leads to a low cross protection and therefore outbreaks in vaccinated flocks are possible. That heterology between strains may have been caused by the emergence of new FPV strains, by the presence of REV in the viral genome or by cross infection with different APV species due to the low specificity for the host that characterizes some of the strains (38, 39, 40, 22).

Despite the above mentioned, another possibility that must be considered as a cause of vaccine failure is the incorrect application of the vaccine in the field (41). Commercial fowl pox vaccines containing 1000–2000 doses per vial are usually diluted in 5 ml of the specific diluent. This means that the volume of the vaccine dose is only 0.005 ml to 0.0025 ml. during vaccination, The vaccine is applied by WW puncture using a manual applicator with one or two needles or a semi-automatic Pox syringe (Fig 3).

The needles should have a calibrated groove (Fig 4. A, B) able to contain the desired amount of vaccine and deliver it into the pierced skin of the wing.

In large commercial flocks, the manual applicators are replaced in most cases by semi- automatic syringes that enable a much faster application. At least 90% of the pullets must be optimally vaccinated to provide adequate protection, and optimal vaccination using the WW stab method requires a highly skilled and trained vaccinating team and a good monitoring of the process.

In order to identify the main cause of the vaccination failure in some of the flocks in Israel, an epidemiological investigation of the outbreaks was carried out by the authors of this article. This investigation revealed that in the rearing pullet farms (four independent rearing farms) that provided some of the affected flocks, that the vaccination was carried out by different authorized and trained vaccinating teams, with vaccines from different commercial companies, from different vaccine batches, and that the vaccinated birds were of different ages at the vaccination time. The only factor that

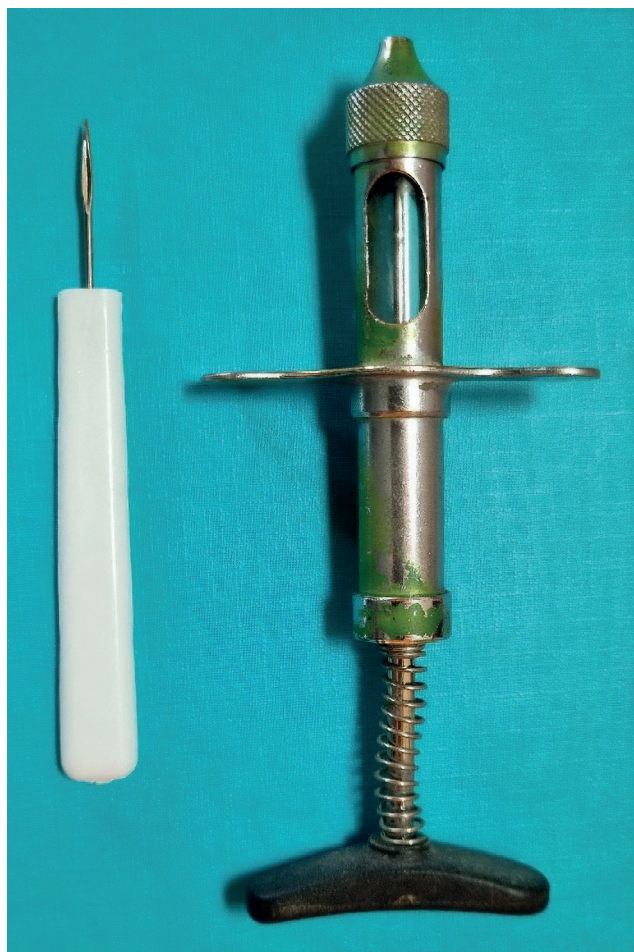


Figure 3. A manual applicator and a semi-automatic syringe for application of Pox vaccines by the Wing Web Stab vaccination.

was common to all the flocks was the method of application by the WW stab using semi-automatic Pox syringes.

In the next step, the (WW) application process carried out by different vaccination teams in the same pullet farms was closely monitored. A significant number of problems of application were identified during the vaccination of the flocks by this method and are further described in the discussion. All the vaccination teams used semi-automatic Pox syringes with one needle (in most cases) or two needles depending on the age of the birds. The authors found that in some cases the needles used had a very shallow groove and in other no groove at all, or that the groove was clogged with skin debris, leading to a very low volume of vaccine delivered to the puncture site. In many cases the semi-automatic syringes were held with the needles facing up and the diluted vaccine in the syringe container did not reach the grooves of the needles. Based on the

above observations in all the monitored farms in this study there appeared to be a substantially inaccurate amount of vaccine delivered to the chickens and in some cases as much as 30%-40% of the vaccine remained unused (data not provided).

Examination of the “Take” after vaccination by WW stab, revealed that almost 100% of the birds were stabbed, but only 60-80% reacted locally with a clear “Take” at the stabbing point 4-7 days after vaccination (data not provided).

To attempt to overcome the problems commonly observed using the WW application for Pox vaccines, we tested and compared the safety and efficacy of Pox vaccination by subcutaneous injection to the WW stab method using commercial pox vaccines under controlled field conditions. These studies were carried out in layer pullets (Lohman and Dekalb lines) and heavy breeder pullet (Ross 308) rearing farms.

In this report we describe the results of those controlled field studies and the results of a long term (two years) follow up of the birds vaccinated by subcutaneous injection (SC) using different volumes of diluted Pox vaccine.

MATERIALS AND METHODS

Farms and Birds in the study:

The vaccination studies were carried out in commercial rearing farms and included replacement pullets for commercial eggs consisting of two chicken lines Lohman and Dekalb. The heavy breeder replacement pullets were Ross 308 and were reared in a heavy breeder rearing facility. All the Vaccinations were carried out by authorized and experienced vaccination teams.

All the revaccination “Challenge” tests and evaluation of the local reaction “Take” was carried out by the poultry veterinarians on the farms.

Equipment used for Pox vaccination:

Wing web (WW) stab vaccination: The WW stab vaccination in the commercial study flocks was carried out using semi-automatic syringes – ThaMa single needle Pox vaccinator (E. Nechmad, Petach Tikvah, Israel). The same type of syringe was used in all the rearing pullet farms from 14 days to 18 weeks of age. The “Challenge” by revaccination by Wing Web stab was carried out using a manual applicator or the same semi-automatic Pox syringe (Fig. 4).



Figure 4. Calibrated grooves in the manual applicator (A) and the semi-automatic Pox-Syringe (B).

Sub-cutaneous vaccination: The field studies were performed using three different types of syringes depending on the required volume of diluted vaccine to provide one dose/bird.

1. ThaMa 405 (E. Nechmad, Petach Tikvah, Israel) fixed dose automatic syringe with a 50 ml vaccine container (Fig. 5) was used for the subcutaneous injection of low volumes (0.05 or 0.1 ml/dose/bird.). The needles used were 20G 1/4”.
2. ThaMa 240 automatic syringes (E. Nechmad, Petach Tikvah, Israel) were used for the SC injection of standard volume (0.2-0.5 ml/dose/bird). The needles used were 20G/3/8”.
3. Socorex 187 vial and tube feeding syringe (0.1-0.5 ml) (Socorex, Ecublens, Switzerland).

The diluent used for the wing web stab vaccination was the commercial diluent that was provided with the vaccine. To allow injection of higher volumes, the vaccine was initially diluted in the original diluent and then sterile saline was

added to reach the required volume to provide an accurate dose per bird.

Safety and efficacy assessment:

To assess the safety of the novel application, adverse effects including development of Pox lesions, signs of disease and mortality were closely monitored in the study groups and were compared to the control groups from the day of vaccination for 4 weeks to enable the development of any adverse effect after vaccination.

To assess the efficacy of the SC vaccination under field conditions, a Pox challenge was simulated 14 to 21 days after vaccination (OIE- Fowlpox, Chapter 3.3.10) by puncturing the wing web with the commercial attenuated Fowlpox vaccine concentrated 5 times the dose per bird. Checking the “Challenged” birds 3-6 days post challenge for the appearance of a typical pox lesion at the site of puncture “Take”. Development of a clear “Take’ was an indication that the

bird did not develop any immunity post vaccination by SC injection.

Well protected birds should not develop any local reaction “Take” at the site of the stab wound. Chapter 3.3.10 (15).

Feasibility study-Safety

To test the feasibility of the novel application, a preliminary safety study was carried out (August 2020). The safety study took place in one flock of 14 days of age, replacement Lohman line layer pullets reared on litter. The group of chicks used to test the safety of the subcutaneous injection included 50 birds which were separated from the rest of the flock by fencing a small area in the chicken house (which contained enough food and water tools for the number of fenced pullets). The 50 separated pullets were vaccinated subcutaneously (SC) in the breast with one dose of standard commercial Pox vaccine Batch 1-051532 (Biovac – Or Akiva, Israel.) contained in 0.1 ml/bird using a manual 1ml syringe.

Preparation of the Pox vaccine for SC injection: The 1000 doses vial lyophilized Pox vaccine was diluted in 5 ml of the specific diluent provided. Sterile saline solution was added to the diluted vaccine to complete 50 ml of diluted vaccine to obtain 1 dose of 0.1 ml/bird.

The rest of the flock was vaccinated with the same vaccine using a ThaMa Fowlpox Syringe with one needle by the WW stab method. Six days after vaccination, the 50 pullets in this study were examined for the presence of a local reaction or swelling at the site of the SC injection. A close follow-up of the study group was carried out for a period of 4 weeks for detection of any adverse effects (local damage at the site of injection or development of Pox clinical signs or lesions) after the vaccination by SC injection.

In order to evaluate the protection obtained (efficacy) after the administration of the Pox vaccine by SC injection, all the 50 pullets in the study group were “challenged” 20 days post vaccination using a 5 times concentrated dose of the same Pox vaccine applied by WW stabbing method using a manual applicator with two needles and calibrated grooves.

Six days after the revaccination test (challenge with a high dose of vaccine by WW stabbing method) all the birds in this group were individually examined to detect the development of a local “Take” lesion to determine the protection provided by the subcutaneous vaccination.

Commercial Field Study- Number one:

The first commercial large-scale study took place in October 2020. Four thousand Dekalb line layer replacement pullets from the same parent flock and hatchery were included in this field study. All the pullets were housed in the same row of cages in a controlled environment chicken house.

At the age of 12 days 2000 pullets were vaccinated by subcutaneous (SC) injection in the breast, with one full dose of a commercial Pox vaccine – Batch 1-051532 (Biovac, Or Akiva, Israel.) diluted to obtain 1 dose (0.1 ml per chick) using an automatic low volume syringe, ThaMa 405 (E Nechmad, Petach Tikvah, Israel). The other 2000 pullets in the same row were used as the control group and were vaccinated with the same vaccine by the WW stab method using the single needle ThaMa Fowlpox Syringe (E Nechmad, Petach Tikvah, Israel). All the birds in the study were monitored daily for 14 days after vaccination to detect any adverse effects, signs of disease, Pox lesions or mortality. Fourteen days after vaccination, 100 birds from the SC vaccinated group and 50 birds from the WW vaccinated group were “Challenged” by revaccination by WW stab method using a 5 times dose of the same commercial Pox vaccine using a manual applicator with two calibrated needles. Five days later all the revaccinated birds were individually examined for the development of a local pox “Take” lesion.

Commercial Field Study – No 2:

The next field study under commercial conditions was carried out to test larger volumes of injection due to some technical problems observed using the low volume (0.05-0.1ml) syringes. To test the technical aspects of an increased volume for the subcutaneous injection, 8000 commercial Dekalb line layer pullets reared in cages in a controlled environment chicken house, were included in this study. All the 8000 pullets were from the same hatch day and originated from the same parent flock and hatchery. At the age of 7 weeks 4000 pullets were vaccinated by SC injection in the breast with one dose of a commercial Pox vaccine Batch 1-051533 (Biovac, Or Akiva, Israel) diluted in sterile saline solution to obtain 1 dose as 0.5 ml per chick using standard ThaMa 240 automatic syringes (E Nechmad, Petach Tikvah, Israel) and 20G/0.5” needles. The other 4000 pullets in the same battery were vaccinated

using the same vaccine diluted in sterile saline to obtain 1 dose of Pox vaccine as 0.1ml/chick using small volume syringes ThaMa 405 (E Nechmad, Petach Tikvah, Israel) with the same needle size.

Two weeks after vaccination, 50 birds vaccinated with the large volume /dose (0.5 ml/dose/chick) and 25 birds vaccinated with the low volume/dose (0.1ml/dose/chick) were “challenged” by revaccinating by the WW stab method applying a 5 times dose of the same commercial Pox vaccine using a ThaMa Fowlpox single needle syringe (E Nechmad, Petach Tikvah, Israel). All the 75 birds were examined 5 days later for the detection of a local “Take” reaction at the puncture site.

Commercial Field Study – No 3: (Heavy breeders replacement pullets):

After confirming the efficacy and safety of the Fowlpox vaccination using the novel application method by SC injection in the breast in replacement layer pullets, another field study in commercial heavy breeder pullets was carried out. The replacement breeders (Ross 308) were raised on litter in a farm consisting of four pullet rearing houses containing chickens of 13 weeks of age. The study group vaccinated by SC injection, consisted of two houses containing about 8400 birds each. All the pullets in these two houses were vaccinated by SC injection in the breast consisting of one vaccine dose of commercial Pox vaccine Batch 1-051533 (Biovac-Or Akiva, Israel) diluted in 0.2 ml of saline/dose/bird, using Socorex 187 automatic syringes (Socorex, Ecublens, Switzerland) and 20G-3/8” needles.

The control group consisted of the other two houses at the farm containing 12500 birds (including 8500 females and 4000 males). All the birds in these houses were vaccinated by WW stab application with one dose of the same Pox vaccine using the single needle ThaMa Fowlpox Syringe. A few days after vaccination by the WW method a sample of the vaccinated birds were examined by the local poultry veterinarian for evaluation of the local reaction “Take”. Fourteen days after vaccination, 20 pullets were randomly selected in each house of the study group (SC injection) and revaccinated by WW stab using a full dose of the same Pox vaccine and examined three days later by the veterinarian for the presence and evaluation of a “Take” in the stabbed wing.

RESULTS

Feasibility preliminary study (Safety):

None of the pullets in the experimental group showed any adverse effect or evidence of disease, or any other lesions characteristic of Fowlpox disease during a period of four weeks.

The “challenge” test carried out by revaccination by the WW stab method using a 5 times dose of the Fowlpox vaccine demonstrated that none of the 50 vaccinated birds by the SC injection method developed any local reaction “Take” after the WW revaccination challenge, indicating a good immune response and protection after the SC vaccination.

Commercial Field Study – No 1:

As described in the materials and methods section, this study focused on comparing the safety and efficacy of SC injection compared the common WW stab method both applied by two experienced and qualified vaccination technicians in 4000 pullets under commercial conditions. In this study, no adverse effects (mortality, Pox Lesions, lesions at the site of injection in the breast, etc.) was observed in any of the SC or the WW vaccinated pullets. Furthermore, both groups showed very similar efficacy results after the “challenge” by revaccination with a 5 times dose of Fowlpox vaccine. The results were 96% (84/87) in pullets from the SC vaccinated group and 95% (42/45) in pullets from the control group vaccinated by the WW stab which did not show any sign of a “Take” indicating a good application and protection in both groups.

Two important and practical points were observed in this study:

Firstly, the vaccination of the 2000 chicks by SC injection was much faster (2000 chicks in one hour) compared to the WW application (2000 chicks in 1 hour and 30 min) even though both applications were performed by two experienced vaccination technicians working at the farm. Secondly, during the vaccination with the low volume syringe (0.05-0.1 ml) it was difficult to assess if the vaccine was flowing properly and as a result, the vaccinator had to check several times during the vaccination if the syringe was providing the right volume of vaccine.

Commercial Field Study – No 2:

This field commercial study was focused on comparing the technical and practical aspects and efficacy of the application

Table 1: Summary of three studies carried out under commercial conditions to test the safety and efficacy of Pox vaccination by Subcutaneous injection using different volumes of injection/dose.

| | Commercial study 1 | | Commercial Study 2 | | Commercial Study 3 | |
|---|--------------------|--------------|--------------------|--------------|--------------------|---------------|
| | WW | SC 0.1ml | SC 0.1ml | SC 0.5ml | WW | SC 0.2ml |
| Number of Chickens | 2,000 | 2,000 | 4,000 | 4,000 | 12,500 | 16,700 |
| Adverse effects, Pox lesions or mortality | Non | Non | Non | Non | Non | Non |
| Revaccination “Challenge” using a X5 dose Pox Vaccine by WW Stab in WW or SC vaccinated birds | | | | | | |
| | Commercial study 1 | | Commercial Study 2 | | Commercial Study 3 | |
| | WW | SC 0.1ml | SC 0.1ml | SC 0.5ml | WW | SC 0.2ml |
| Protected “No Take” | 42/44 95% | 84/87 96% | 21/25 84% | 49/50 98% | ND | 40/40 100% |
| Mild local inflammation at puncture site | 2/44 | 3/87 | 4/25 | 1/50 | ND | 0/40 |
| Not Protected Well developed “Take” | 0/44 | 0/87 | 0/25 | 0/50 | ND | 0/40 |

ND-Not Done

of a Pox vaccine by SC injection in the breast. The birds were vaccinated by the same vaccination team using different syringes providing different volumes of injection per dose: ThaMa 405 (E. Nechmad, Petach Tikvah, Israel) – using 0.1ml/dose or ThaMa 240 (E. Nechmad, Petach Tikvah, Israel) – using 0.5ml/dose.

The results in this study indicated that if the low volume of 0.1 ml/dose/bird by SC injection was applied properly, there was no difference in the efficacy when compared to SC injection using a larger volume of 0.5ml/dose/bird. In accordance, both groups vaccinated by the SC injection showed a very good protection as 100% in both groups did not show any “Take” lesion after the challenge by revaccination with a high dose of Pox vaccine by WW stab.

Commercial Field Study – No 3:

This field commercial study was focused on assessing the efficacy of SC application (compared to the WW stab technique) in heavy breeders (Ross 308) replacing pullets. All the birds on the farm were vaccinated with the same Pox vaccine by the same experienced vaccination team and the monitoring was carried out by the veterinarian in charge.

Examination of the control birds vaccinated by WW puncture by the local vaccination team revealed that only 78% (31/40) of the vaccinated pullets showed a local reaction of a “Take” after vaccination by the traditional WW stab method. In the birds vaccinated by SC injection by the same team, and “challenged” by revaccinating 14 days later by WW

stab method, no sign of a “Take” were identified in any of the revaccinated birds (40/40) indicating that the vaccination by SC injection induced a uniform and complete protection in 100% of the pullets. The results of all the commercial field studies are summarized in Table 1.

DISCUSSION:

Sporadic cases of Fowlpox are observed in vaccinated flocks all over the world including Israel. In most of these cases the outbreaks are relatively mild affecting 10%-30% of the flock. The Pox lesions are usually cutaneous and localized to the face, eyelids, wattles, and comb with no diphteric lesions. In most of these cases mortality is very low, however there is a clear welfare issue and performance is negatively affected.

Flocks suffering from Pox outbreaks during production or molting, should be revaccinated with Pox vaccine to stop the rolling of the disease within the flock causing severe stress and economic losses.

The epidemiological investigation carried out in several rearing pullet farms in Israel, to define the reason of the vaccine failures (Fowlpox outbreaks during production or molting) observed in Fowlpox vaccinated flocks, revealed that the vaccination by wing web stabbing suffered from many technical problems leading to low uniformity of the development of immunization and protection of the birds.

In large commercial rearing farms, the Fowlpox vaccine is usually applied by the WW stab technique using a one

or two needle semi-automatic Pox syringe. In some cases the needles used have a very shallow groove or no groove at all. Even in the case where the needles were examined and approved before use, we found after vaccination of several hundred birds, that the grooves of the needles were clogged with skin debris, leading to a very low volume of vaccine delivered to the puncture site.

In other cases, we observed that the semi-automatic Pox syringes were held with the needles facing upwards and the diluted vaccine in the syringe container did not reach the grooves of the needles. Independently from the vaccination team, in all the monitored farms in this study it appeared that the WW application delivered an inaccurate amount of vaccine to the chickens and in some cases as much as 30%-40% of the vaccine remained unused.

Examination of the "Take" after vaccination of the pullets flocks by experienced and authorized teams in different farms using the WW stab method, revealed that in most cases almost 100% of the birds were stabbed in the wing. However, we found that only 60-90% of the vaccinated birds reacted locally with a clear "Take" at the stabbing point four to seven days after vaccination. The results obtained after vaccination by SC injection of several thousands of birds in commercial flocks with Fowlpox vaccines diluted in sterile saline solution (one full dose/bird), strongly supported the assumption that this vaccination method was safe as no adverse effects of any kind were observed in any bird within the vaccinated flocks.

Regarding application and efficacy, we found that the subcutaneous injection (SC) in the breast using automatic syringes was faster and more reliable than the WW stab method, enabling therefore the use of 100% of the vaccine doses (one dose/bird) in all the flocks in the study compared to the WW stab application.

We found that the volume of injection between 0.1-0.5 ml/dose/bird if applied properly using different types of syringes, had no effect on the efficacy if the birds received the required one full dose of the vaccine. Technically we observed that vaccination using syringes with very low volumes (0.05-0.1ml), required the vaccinator to check continuously if the syringes were delivering the vaccine. On the other hand, the SC injection using syringes with larger volumes from 0.2ml to 0.5ml provided a better control and accuracy of the administration of the vaccine dose.

The "challenge" of the birds vaccinated by SC injection using a five times dose of Fowlpox vaccine administered

by wing web stab (WW) demonstrated a very uniform and efficient immunization of the flocks vaccinated by SC injection.

During the last two years there has been a change that is gradually spreading in the poultry industry in Israel, in which farms and private vaccination teams apply the commercial attenuated pox vaccines using the subcutaneous injection instead of the wing web stab method. It is estimated that to date, more than 3 million birds (layers and breeders) have been vaccinated with Pox vaccines by SC injection with not a single report of adverse effects during the rearing and production stages. Up to now, no reports of outbreaks of Poxvirus have been reported in Israel in any of the vaccinated flocks using the SC injection application.

The conclusion of this field studies strongly supports that the application of Fowlpox vaccines by subcutaneous injection is a safe, more practical and reliable alternative than the wing web stab (WW) application in large commercial flocks.

REFERENCES

1. Woodruff, C. E. and Goodpasture, E. W.: The relation of the virus of fowl-pox to the specific cellular inclusions of the disease. *Am. J. Path.* 6:713-720, 1930.
2. Goodpasture, E. W.: The Infectivity of isolated inclusion bodies of fowl-pox. *Am. J. Path.* 5:1-10, 1929.
3. Woodruff, A. M. and Goodpasture, E. W.: The susceptibility of the chorio-allantoic membrane of chick embryos to infection with the fowl-pox virus. *Am. J. Path.*, 7:209-222, 1931.
4. Bolte, A. L., Meurer, J. and Kaleta, E. F.: Avian host spectrum of avipoxviruses. *Avian Pathol.* 28:415-432, 1999.
5. Odend'hal, S.: Fowlpox virus. The geographical distribution of animal viral diseases. New York (NY), Academic Press. pp, 213-215, 1983.
6. Van Riper III, C. and Forrester, D. J.: Avian Pox. Thomas, N. J., Hunter, D. B. and Atkinson, C. T.: Infectious diseases of wild birds. Ames (IA): Blackwell Publishing Professional. 131-176, 2007.
7. Tripathy, D. N. and Reed, W. M.: Pox. Swayne, D. E., Glisson, J. R., McDougald, L. R., Nolan, L. K., Suarez, D. L. and Nair, V.: Diseases of Poultry 13th ed. 10:333-350, Wiley-Blackwell, 2013.
8. Woodruff, C. E.: A comparison of the lesions of fowlpox and vaccinia in the chick with especial reference to the virus bodies. *Am. J. of Path.* 6:169-174, 1930.
9. Tripathy, D. N. and Hanson, L. E.: A smear technique for staining elementary bodies of fowlpox. *Avian Dis.*, 20:609-610, 1976.
10. Nakamura, K., Waseda, K., Yamamoto, Y., Yamada, M., Nakazawa, M., Hata, E., Terazaki, T., Enya, A., Imada, T. and Imai, K.: Pathology of cutaneous fowlpox with amyloidosis in layer hens inoculated with fowlpox vaccine. *Avian Dis.* 50:152-156, 2006.
11. Giotis, E. S. and Skinner, M. A.: Spotlight on avian pathology: fowlpox virus. *Avian Path.* 48:87-90, 2019.
12. Clubb, S. L.: Avian pox in cage and aviary birds. Fowler M. E.:

- Zoo and wild animal medicine. 2nd ed. Philadelphia (PA): W. B. Saunders Company, 213-219, 1986.
13. Forrester, D. J.: The ecology and epizootiology of avian pox and malaria in wild turkeys. *Bull. Soc. Vector Ecol.* 16:127-148, 1991.
 14. Akey, B. L., Nayar, J. K. and Forrester, D. J.: Avian pox in Florida wild turkeys: *Culex nigripalpus* and *Wyeiomyia vanduzeei* as experimental vectors. *J. Wildl. Dis.* 17:597-599, 1981.
 15. World Organization for Animal Health: Fowlpox. OIE Terrestrial Manual, 3.3.10:906-914, 2018.
 16. Tripathy, D. N.: Avipoxviruses. McFerran, J. B. and McNulty, M. S.: *Virus Infections of Vertebrates – Virus Infections of Birds*, Elsevier Science Publishers, Amsterdam, the Netherlands, 4:5-15, 1993.
 17. International Committee on Taxonomy of Viruses. ICTV 2018 master species list (MSL33). 2018.
 18. Afonso, C. L., Tulman, E. R., Lu, Z., Zsak, L., Kutish, G. F. and Rock, D. L.: The genome of Fowlpox virus. *J. Virol.* 74:3815-3831, 2000.
 19. Srinivasan, V., Shnitzlein, W. M. and Tripathy, D. N.: Fowlpox virus encodes a novel DNA repair enzyme, CPD-photolyase, that restores infectivity of UV light-damaged virus. *J. Virol.* 75:1681-1688, 2001.
 20. Srinivasan, V. and Tripathy, D. N.: The DNA repair enzyme, CPD-photolyase restores the infectivity of UV damaged fowlpox virus isolated from infected scabs of chickens. *Vet. Microb.* 108:215-223, 2005.
 21. Jarmin, S., Manvell, R., Gough, R. E., Laidlaw, S. M. and Skinner, M. A.: Avipoxvirus phylogenetics: identification of a PCR length polymorphism that discriminates between the two major clades. *J. Gen. Virol.* 87:2191-2201, 2006.
 22. Adams, C. J., Feldman, S. H. and Sleeman, J. M.: Phylogenetic analysis of avian poxviruses among free-ranging birds of Virginia. *Avian Dis.* 49:601-605, 2005.
 23. Boosinger, T. R., Winterfield, R. W., Feldman, D. S. and Dhillon, A. S.: Psittacine pox virus: virus isolation and identification, transmission and cross-challenge studies in parrots and chickens. *Avian Dis.* 26:437-444, 2015.
 24. Manarolla, G., Pisoni, G., Sironi, G. and Rampin, T.: Molecular biological characterization of avian poxvirus strains isolated from different avian species. *Vet. Microbiol.* 140:1-8, 2010.
 25. Singh, P., Kim, T. J. and Tripathy, D. N.: Reemerging fowlpox: evaluation of isolates from vaccinated flocks. *Avian. Path.* 29:449-455, 2000.
 26. Singh, P., Schnitzlein, W. M. and Tripathy, D. N.: Reticuloendotheliosis virus sequences within the genomes of field strains of fowlpox virus display variability. *J. Virol.* 77:5855-5862, 2003.
 27. Beaudette, F. R.: Twenty years of progress in immunization against virus diseases of birds. *J. Am. Vet. Med. Assoc.* 115: 234-244, 1949.
 28. Doyle, T. M.: Immunization of fowls against fowlpox by means of pigeon pox virus. *J. Comp. Pathol.* 43:40-55, 1930.
 29. Skinner, M. A., Laidlaw, S. M., Eldaghayes, I., Kaiser, P. and Cottingham, M. G.: Fowlpox virus as a recombinant vaccine vector for use in mammals and poultry. *Vacc.* 4:63-76, 2005.
 30. Mackett, M., Smith, G. L. and Moss, B.: General method for production and selection of infectious vaccinia virus recombinants expressing foreign genes. *J. Virol.* 49:857-864, 1984.
 31. Edbauer, C., Weinberg, R., Taylor, J., Rey-Senelonge, A., Bouquet, J. F., Desmettre, P. and Paoletti, E.: Protection of chickens with a recombinant fowlpox virus expressing the Newcastle disease virus hemagglutinin-neuraminidase gene. *Virol.* 179: 901-904, 1990.
 32. Taylor, J., Edbauer, C., Rey-Senelonge, A., Bouquet, J. F., Norton, E., Goebel, S., Desmettre, P. and Paoletti, E.: Newcastle disease virus fusion protein expressed in a fowlpox virus recombinant confers protection in chickens. *J. Virol.* 64:1441-1450, 1990.
 33. Webster, R. G., Kawaoka, Y., Taylor, J., Weinberg, R. and Paoletti, E.: Efficacy of nucleoprotein and haemagglutinin antigens expressed in fowlpox virus as vaccine for influenza in chickens. *Vacc.* 9: 303-308, 1991.
 34. Arioshi, R., Takase, K., Matsuura, Y., Deguchi, K., Ginnaga, A. and Fujikawa, H.: Vaccination against fowlpox virus via drinking water. *J. Vet. Med. Sci.* 65:1127-1130, 2003.
 35. Beard, C. W., Schnitzlein, W. M. and Tripathy, D. N.: Effect of route of administration on the efficacy of a recombinant fowlpox virus against H5N2 avian influenza. *Avian Dis.* 36:1052-1055, 1992.
 36. Radovic, E., L'uschow, D., Ciglar-Grozdani, I., Ti'sljarić, M., Mazija, H., Vranesi, D. and Hafez, H. M.: Isolation and molecular biological investigations of avian poxviruses from chickens, a turkey, and a pigeon in Croatia. *Avian Dis.* 50:440-444, 2006.
 37. Luschow, D., Hoffmann, T. H. and Hafez, H. M.: Detection of fowlpox in chickens and turkeys in Germany. *B. Mun. Tier. Woch.* 125:60-66, 2012.
 38. Tadese, T., Fitzgerald, S. and Reed, W. M.: Detection and differentiation re-emerging fowlpox virus (FWPV) strains carrying integrated reticuloendotheliosis virus (FWPV-REV) by real-time PCR. *Vet. Microbiol.* 12:39-49, 2008.
 39. Hamidi, A., Luschow, D., George, D., Sheriff, K., Sparagano, O., Hafez, H. M. and Sylejmani, D.: Fowlpox Virus Outbreaks in Kosovan Layer Flocks: An Evidence of Vaccination Failure. *Vet.* 65: 55-58, 2016.
 40. MacDonald, A. M., Gibson, D. J., Barta, J. R., Poulson, R., Brown, J. D., Allison, A. B. and Nemeth, N. M.: Bayesian Phylogenetic Analysis of Avipoxviruses from North American Wild Birds Demonstrates New Insights into Host Specificity and Interspecies Transmission. *Avian. Dis.* 63:427-432, 2019.
 41. Perelman, B., Kin, E., Heifez, S., Noah-Bennet, C., Even-Chen, T., Ashash, U., Finger, A. and Perk, S.: Investigation Study of Turkey Meningoencephalitis (TME) Vaccine Failure. Causes and Solutions in the Field. *Isr. J. Vet. Med.* 67:154-161, 2012.