

# A Case of Chronic Abdominal Actinomycosis with Severe Hepatic Involvement in a Dog

Gavhane, D.S.,\* Moregaonkar, S.D., Mhase, A.K., Sawale, G.K. and Kadam, D.P.

Department of Veterinary Pathology, Bombay Veterinary College, Parel, Mumbai-12, India.

\* **Corresponding Author:** Dr. Gavhane Dnyaneshwar Shivaji, Department of Pathology, Bombay Veterinary College, Mumbai-12, India. Tel: +919011443802. Email: mmaulivet@gmail.com

## ABSTRACT

The authors present a case report on abdominal actinomycosis in 7 year old German shepherd dog, which was presented with the complaint of chronic fever, anorexia, weight loss, hematemesis and a recent history of mixed hemoprotozoan infections. Due to the non-specific clinical presentation, the diagnosis was delayed. X-ray and ultrasonographic examination revealed ascites; severe hepatomegaly with surface nodularity indicating possibility of hepatic neoplasia. However, findings on necropsy and detailed histopathological investigations confirmed the diagnosis as actinomycosis. To the best of the authors knowledge this is the rare report of abdominal actinomycosis in dog.

**Keywords:** Actinomycosis; Dog; Neoplasia; Hepatomegaly.

## INTRODUCTION

Actinomycosis is caused by gram positive filamentous organism from the *Actinomyces* spp. and is characterized by chronic pyogranulomatous inflammation in affected organ (5, 9). It can establish localized as well as generalized infections. Different species such as *Actinomyces bovis*, *Actinomyces israeli*, *Actinomyces hordeovulnare*, *Actinomyces canis*, *Actinomyces viscosus*, and *Actinomyces odontolyticus* have been implicated to cause actinomycosis in humans and animals (1, 2, 3, 5, 7, 11, 12). These microbes can localize at pleural cavity, pelvic cavity, abdominal cavity, neck lymphnodes, bones, eyes, nervous system, and cervico-facial region and causes different disease conditions such as osteomyelitis, lymphadenopathies, bursitis, pleuritis, pneumonia and peritonitis. Infections are relatively common in large animal particularly bovines (5, 7, 8, 15, 17). Abdominal actinomycosis is rare in animals. It usually runs a chronic course. Non-specific signs and symptoms create difficulty in a timely diagnosis (4).

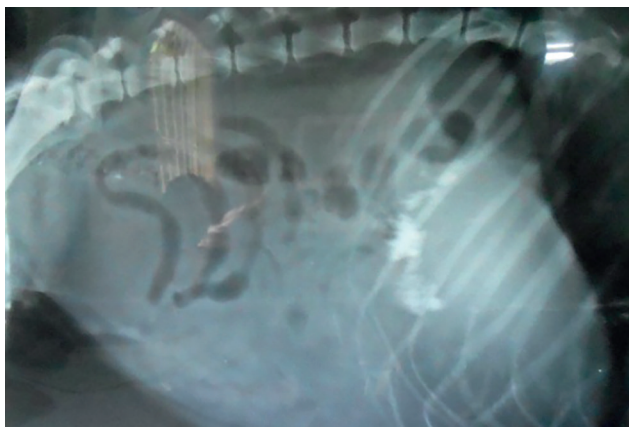
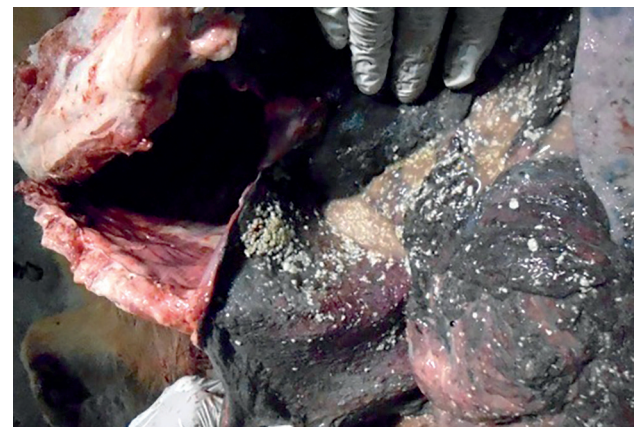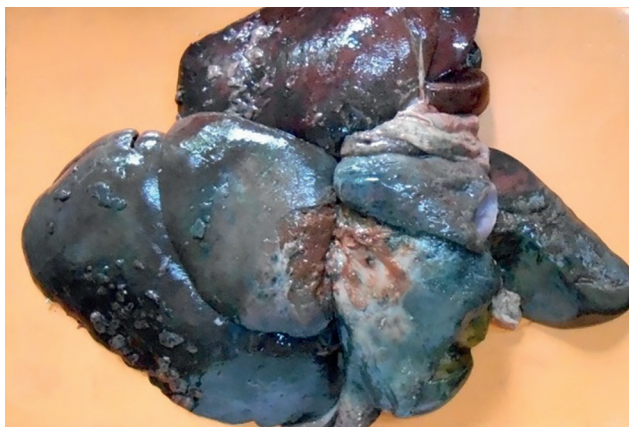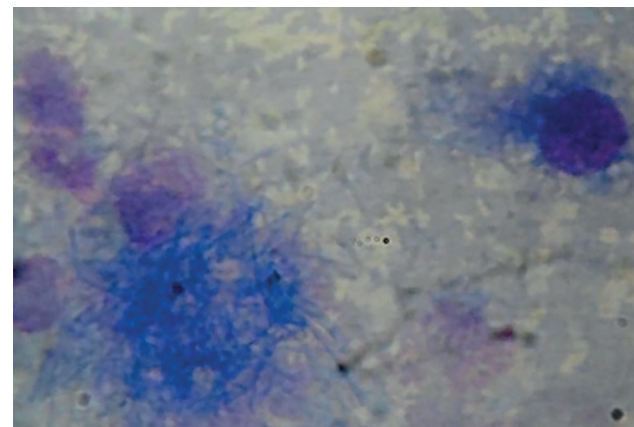
## CASE HISTORY

A seven year old female German shepherd dog with clinical presentation of chronic fever, anorexia, weight loss, hematemesis and labored breathing was presented to Department of Medicine, Bombay Veterinary College, Mumbai-12, India. A month before, antibodies were detected in serum against *Anaplasma phagocytophilum* and *Ehrlichia canis*, therefore, the dog was under treatment with Doxycycline at 5 mg/kg BW BID (Doxy1LDR Fort, Hosur, India). However, intermittent low grade fever continued. Most of the hemato-biochemical observations were within normal range (Table 1). There was mild neutrophilic leukocytosis, toxic neutrophils, microcytic hypochromic anemia and stages of *Mycoplasma haemocanis* in RBCs.

Radiologic and sonographic examination revealed ascites, severe hepatomegaly with an uneven surface having multiple small protrusions indicative of malignancy (Fig. 1). The dog died during emergency intervention and a detailed post mortem investigation was carried out.

**Table 1:** Hemato-biochemical observations.

Hematobiochemical observations	Observed values	Reference Values (7, 17)
WBC count	17.8 X 10 <sup>3</sup> / μl	6-17 X 10 <sup>3</sup> / μl
Neutrophils	78 X 10 <sup>3</sup> / μl	60-77 X 10 <sup>3</sup> / μl
RBC count	4.9 X 10 <sup>6</sup> / μl	5.5-8.5 X 10 <sup>6</sup> / μl
Hemoglobin	7.8 gm%	12-18 gm%
Packed Cell Volume (PCV)	29.8 %	37-55 %
Mean Corpuscular Volume (MCV)	60.52 fl	66-77 fl
Platelet Count	2.11 X 10 <sup>5</sup> / μl	2-5 X 10 <sup>5</sup> / μl
Aspartate transaminase	31.3 IU/ L	23-66
Alanine transaminase	20.6 IU/L	21-102
Total Bilirubin	0.3 mg/ dL	0.1-0.5 mg/ dL
Total Proteins	7.2 g/dL	5.4-7.1 g/ dL
Albumin Globulin ratio	0.6	0.75-1.2
Alkaline phosphatase	119.2 IU/ L	20-156 IU/ L
Blood urea nitrogen	12.3 mg/ dL	10-28 mg/ dL
Creatinine	0.8 mg/ dL	0.5-1.5 mg/ dL

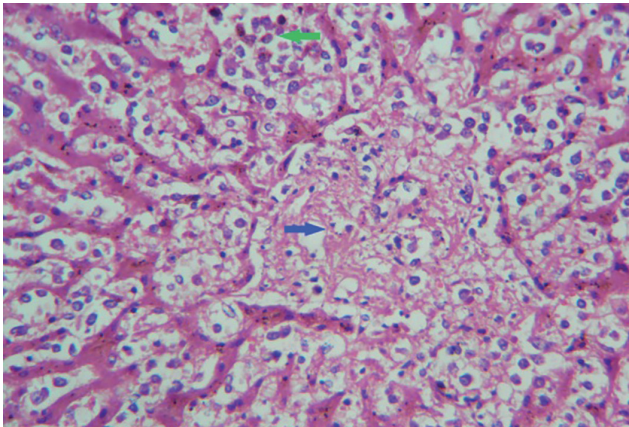
**Figure 1:** Radiographic view of lateral abdomen indicating ascites.**Figure 2:** Opened abdominal cavity showing diffuse peritonitis, grayish exudate and numerous sulfur colored granules.**Figure 3:** Severe hepatomegaly with uneven surface and numerous nodular and villous outgrowths mimicking tumor.**Figure 4:** Cytology of peritoneal exudate showing filamentous, branching, ray-fungus like organisms and macrophages (1000 X, Field's Stain).

## RESULTS AND DISCUSSION

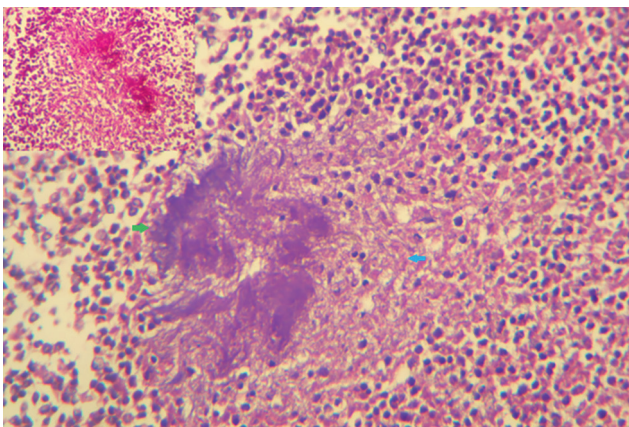
At necropsy emaciation was evident. The abdominal cavity contained 300-500ml of gray colored exudate with a fetid odor with numerous sulfur colored, flat and spherical granules measuring around 1-3 mm in size (Figure 2). The serosal surface of intestine, urinary bladder, and mesentery were reddish-gray in color and the surface appeared corrugated and hyperplastic. The liver was firm, remarkably enlarged, with rounded edges and an uneven surface. There were red and gray black areas and multiple small nodular growths on the surface of liver, which appeared to resemble hepatic neoplasia (Fig.3). The surface of all visceral organs and parietal peritoneum was heavily studded with similar sulfur colored granules (Fig.2). The gastric pyloric area showed multiple hemorrhagic ulcers. Peritoneal fluid along with the sulfur colored granules were harvested aseptically and processed

for isolation and identification of causative agent using the BacT/ALERT 3D system (BioMerieux, India Pvt. Ltd). Samples pieces of all organs were collected and immediately fixed in 10% neutral buffered formalin for routine histopathological study.

Cytology of smears made of peritoneal fluid stained with Romanowsky stain and Field's stain (S008-9, Himedia, India), revealed numerous foamy macrophages, mesothelial cells, lymphocytes and degenerating neutrophils along with bunches of numerous filamentous organisms resembling ray-fungi (Fig. 4). Histologically, sections of liver showed several degenerating hepatocytes, atrophy and distortion of hepatic cords. Sinusoids were dilated and massively infiltrated with mononuclear cells (Fig. 5). Portion of liver with nodular areas



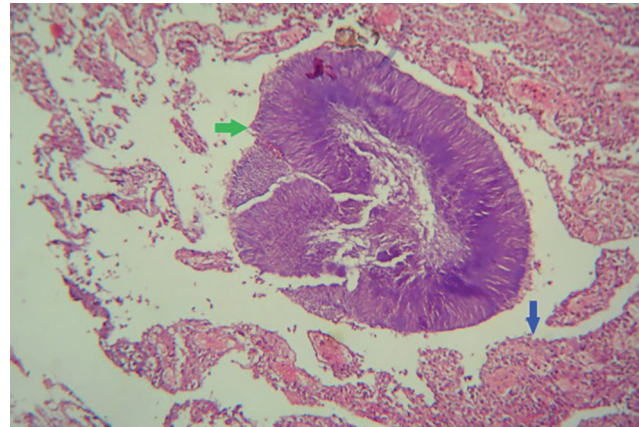
**Figure 5:** Histological section of liver showing destruction, atrophy of hepatic cords, dilatation of sinusoidal space, massive infiltration of mononuclear cells in sinusoids (Green arrow) and proliferation of fibrocytes in central vein area (Blue arrow) (400 X, H&E).



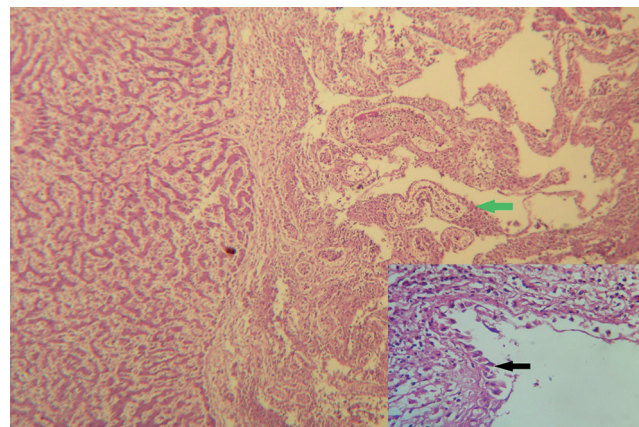
**Figure 7:** Ray fungus like filamentous bacterial colonies (Green arrow), Splendore Hoespli reaction (Blue arrow) and PAS positive organism (Upper left) (400 X, H&E).

revealed fibrous connective tissue encapsulated abscesses containing mononuclear cells, degenerated neutrophils and centrally placed sulfur granules containing bunches of filamentous ray rods radiating outwards and surrounded by pink proteinaceous material i.e. Splendore-Hoepli reaction (Fig. 6 and 7).

On the surface of liver, serosa of abdominal organs and parietal peritoneum, villous like projections made of angiofibroblastic tissue composed of loose fibrous connective tissue intermixed with numerous small capillaries, and infiltrating mononuclear cells were noticed (Fig. 8). The lining epithelium of these villous projections consisted of proliferating hypertrophied mesothelial cells (Fig.8). Duplicate sections of all tissues were stained with Brown-Brenn's grams stain (10),



**Figure 6:** Characteristic sulfur granule (Green arrow) typical of *Actinomyces* spp. in histological section of liver and agnio-fibroblastic growths (Blue arrow) (400 X, H&E).



**Figure 8:** Histological section of liver showing villous like growth of angio-fibroblastic tissue (Green arrow) lined by proliferation hypertrophied mesothelial cells (Black arrow) (400 X, H&E).

Periodic Acid Schiff (PAS) stain (Himedia, India), Gomori methanamine silver (GMS) stain (10), Ziehl Neelsen (ZN) acid fast (Himedia, India), Kinyoun's modified acid fast (Sigma Aldrich, USA) and Fite stain (14).

A panel of different stains used indicated the bacteria to be Gram positive, PAS positive, Gomori methanamine silver/GMS positive, Modified ZN acid fast negative, Kinyoun's modified acid fast negative and Fite stain negative. Whereas actinomyces have very thin branching filamentous rods, *Nocardia spp.* are variably gram positive, modified acid fast and in systemic infection do not show PAS positivity (8). Culture in the Automated BacT/ALERT 3D System confirmed the bacteria as *Actinomyces spp.*

Due to the subacute to chronic presentation, the non-specific signs and symptoms, diagnosis in such cases is frequently delayed. The dog was under immunosuppression due to already existing hemoprotozoan infections and long term chemotherapy, which might have helped to establish actinomycosis. The exact mode of spread of bacteria cannot be ascertained. In hepatic involvement, the portal of entry of bacteria is presumably hematogenous (5). Perforating ulcers in the gastrointestinal tract, penetrating objects such as pointed awns and faulty closure of the uterine stumps after hysterectomy or through penetrating intrauterine devices are proposed causes (5, 8). The dog presented here was police sniffer dog which was under daily observation. Therefore, chances of rice awns contamination in rice seems less, however, small sharp bone fragments (chicken or fish meal) may have mechanism of action similar to that of penetrating awns.

The reports on actinomycoses in dog are very scarce as the incidence is extremely rare. They are characterized as chronic progressive (5). Surgical fistulas to drain exudate and long term penicillin therapy for 6 to 12 months are proposed in such cases (5, 14). Animals should be examined for recurrence after discontinuing medication. Similar clinical presentations as well as similar patho-morphological findings have been reported in human with abdominal actinomycosis (8, 14).

## REFERENCES

1. Barnes, L.D. and Grahn, B.H.: Actinomyces endophthalmitis and pneumonia in a dog. *Can. Vet. J.* 48: 1155-1158, 2007.
2. Basheer, M., Priya, P.M., Surya, P.S., Abhinay, G. and Nair, K.: Isolation, characterization and antibiogram of *actinomyces viscosus* from a dog. *Int. J. Life Sci.* 2: 5-7, 2013.
3. Buchanan, A.M., Scott, J.L., Gerencser, M.A., Beaman, B.L., Jang, S. and Biberstein, E.L.: 1984. *Actinomyces hordeovulneris* sp. nov. an Agent of Canine Actinomycosis. *Int. J. Syst. Bacteriol.* 34: 439-443, 1984.
4. Cote, E.: *Clinical Veterinary Advisor: Dogs and Cats*, Mosby Elsevier, St. Louis, Missouri, USA, 2015.
5. Edwards, D.F., Nyland, T.G. and Weigel, J.P.: Thoracic, abdominal, and vertebral actinomycosis. Diagnosis and long-term therapy in three dogs. *J. Vet. Intern. Med.* 2: 184-91, 1988.
6. Hoyles, L., Falsen, E., Foster, G., Pascual, C., Greko, C. and Collins, M.D.: *Actinomyces canis* sp. nov, isolated from dogs. *Int. J. Syst. Evol. Microbiol.* 50: 1547-1551, 2000.
7. Kaneko J.J., Harvey J.W. and Bruss M.L.: *Clinical Biochemistry of Domestic Animals*, Elsevier, California, USA, 2008.
8. Lai, A.T., Lam, C.M., Ng, K.K., Yeung, C., Ho, W.L., Poon, L.T. and Ng, T.O.: Hepatic actinomycosis presenting as a liver tumour: case report and literature review. *Asian. J. Surg.* 27: 345-7, 2004.
9. Lum, C.A. and Vadmal, M.S.: Case Report: *Nocardia asteroides* Mycetoma. *Ann. Clin. Lab. Sci.* 33: 329-333, 2003.
10. Luna, G.: *AFIP Manual of Histologic Staining Techniques*. 3rd. edn. New York: McGraw- Hill Publications. pp: 222, 1968.
11. Moens, Y. and Verstraeten, W.: Actinomycosis due to *Actinomyces viscosus* in a young dog. *Vet. Rec.* 106: 344-5, 1980.
12. Pelle, G., Makrai, L., Fodor, L. and Dobos-Kovács, M.: Actinomycosis of Dogs Caused by *Actinomyces hordeovulneris*. *J. Comp. Pathol.* 123: 72-76, 2000.
13. Sharma, M., Briski, L.E., and Khatib, R.: Hepatic actinomycosis: an overview of salient features and outcome of therapy. *Scand. J. Infect. Dis.* 34: 386-91, 2002.
14. Sheehan D. and Hrapchak B.: *Theory and practice of Histotechnology*, Battelle Press, Ohio, USA, 1981.
15. Sivacolundhu, R.K., O'Hara, A.J. and Read, R.A.: Thoracic actinomycosis (arcanobacteriosis) or nocardiosis causing thoracic pyogranuloma formation in three dogs. *Aust. Vet. J.* 79: 398-402, 2002.
16. Venkatesh, K., Saini, M.L. and Niveditha, S.R.: Fine needle aspiration cytology of cervicofacial actinomycosis. *J. Cytol.* 25: 113-4, 2008.
17. Weiss D.J. and Wardrop K.J.: *Schalms' Veterinary Hematology*, 6th Edition, Iowa State University Press, United States, 2010.