

# Immunohistochemical Demonstration of Caspase Inhibition in Skin and Visceral Organ Lesions in Naturally Occurring Sheep Poxvirus Infection

Haligur, M.<sup>1\*</sup> and Ozmen, O.<sup>2</sup>

<sup>1</sup> Department of Pathology, Faculty of Ceyhan Veterinary Medicine, University of Cukurova, 01960, Ceyhan/Adana-Turkey.

<sup>2</sup> Department of Pathology, Faculty of Veterinary Medicine, University of Mehmet Akif Ersoy, 15030, Istiklal Yerleskesi, Burdur-Turkey.

\* **Corresponding author:** Assoc. Prof. Dr. Mehmet HALIGUR, PhD, University of Cukurova, Faculty of Ceyhan Veterinary Medicine, Department of Pathology, Fatih Sultan Mehmet Mah. 374 sk. No:1, 01960, Ceyhan/Adana-Turkey, Phone: + 90 322 6133507/108, Fax: + 90 322 6133507. Email: mhaligur@cu.edu.tr, mhaligur@gmail.com

## ABSTRACT

The objective of this immunohistochemical study was to examine the expression of caspase-3,-5,-7, and -9 in sheep pox lesions in 15 naturally infected crossbred merino lambs. Sheep pox was diagnosed based on typical gross and histopathological lesions in the skin and visceral organs that were evaluated pathologically and immunohistochemically. Macroscopically, lesions were observed in the skin and visceral organs. Characteristic sheep pox inclusion bodies and cellules claveleuses (sheep pox cells) were present in all cases. After histopathological examinations, tissue sections were immunostained for caspase-3,-5,-7, and -9. While strong positive reactions were observed in normal tissue, only weak expression was noted in poxvirus lesions, demonstrating marked caspase inhibition in naturally infected lambs. This finding suggests a role for caspases in sheep poxvirus infection and its pathogenesis.

---

**Keywords:** Caspase; Immunohistochemistry; Pathology; Sheep pox

## INTRODUCTION

Sheep pox is a highly contagious viral infection characterized by fever and ocular and nasal discharge (1, 2). Pox lesions appear on the skin and respiratory and gastrointestinal mucosa (3, 4). Mortality can be high, especially in lambs. Epidermal lesions are characterized by localized acanthosis, hyperplasia, and inflammatory cell infiltrations. The edematous dermis and subcutis contain many “cellules claveleuses” or sheep pox cells that are diagnostic for the disease (3-5). These virus-infected cells and their cytoplasm contain one or more eosinophilic inclusion bodies with margined chromatin(4, 6-8).

Caspases are a family of calcium-dependent cysteine proteases that play an essential role in apoptosis; one of the main forms of programmed cell death (9-11). These enzymes exist within the cell as inactive pro-forms or zymogens that can be cleaved to form active enzymes following apoptosis

induction. Caspases have been termed “executioner” proteins given their cellular roles. Some caspases are also required in the immune system for cytokine maturation (2, 9, 12-17).

Poxviruses express proteins that can inhibit the apoptosis of infected cells, allowing virus replication to continue. Some poxvirus anti-apoptotic proteins act by sequestering or inactivating apoptosis inducers (10). Poxviruses encode a more diverse variety of apoptosis inhibitors than any other virus families (2). The purpose of the present study was to immunohistochemically demonstrated inhibition of caspase-3,-5,-7, and -9 in sheep poxvirus lesions in naturally infected lambs.

## MATERIALS AND METHODS

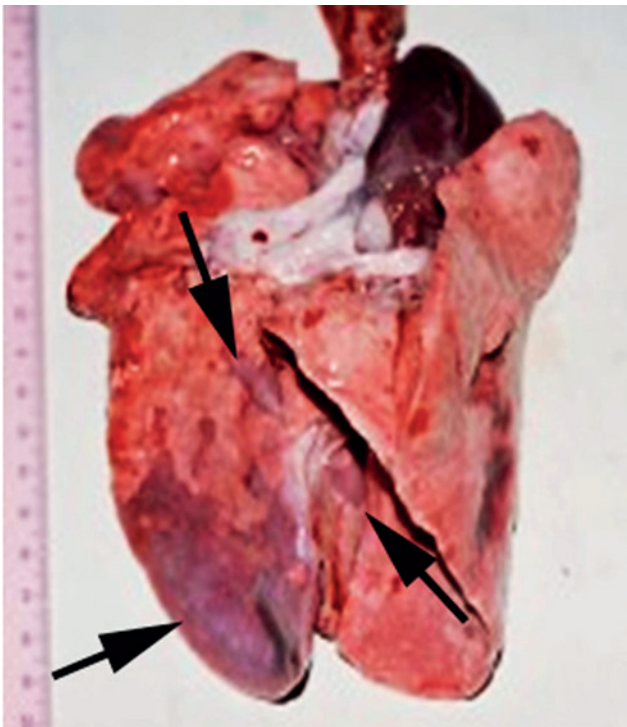
Fifteen 3- to 7-week-old, crossbred merino sheep lambs with skin and visceral pox lesions from five different flocks were brought to University of Mehmet Akif Ersoy, Faculty

of Veterinary Medicine, Department of Pathology, Burdur, Turkey for diagnosis. At necropsy, tissue samples were taken from all organs and fixed in 10% buffered formaldehyde. Using standard methods, the tissues were embedded in paraffin, cut into 5- $\mu$ m thick sections, stained with hematoxylin-eosin (HE), and examined microscopically. Skin and visceral organ samples from five merino lambs that died from other diseases at the same ages were used as controls.

Selected tissue sections were immunohistochemically processed to assess the expression of caspase-3, -5, -7, and -9 [Caspase-3, Rabbit polyclonal, Cat no: 250573, Abbiotec LLC, San Diego, CA, USA; Caspase-5, Rabbit polyclonal, Cat no: CG1669, Cell Application Inc. San Diego, CA, USA; Caspase-7, Rabbit polyclonal, Cat no: CG1671, Cell Application Inc. San Diego, CA, USA; Caspase-9, Mouse polyclonal, Cat no: ab52298, Abcam, Cambridge, UK] using routine avidin-biotin-peroxidase complex techniques (18). Selected sections were stained for immunohistochemistry processed according the manufacturer's instructions. The paraffin-embedded, 5- $\mu$ m sections were attached to glass slides coated with poly-L-lysine and dried overnight at 37°C to optimize adhesion. Sections were de-paraffinized in multiple xylene baths, and rehydrated in sequentially graduated

ethyl alcohol baths. To reduce non-specific background staining due to endogenous peroxidase, slides were incubated in hydrogen peroxide in methanol for 10 minutes. The sections were washed twice in phosphate buffer solution (PBS) and boiled in a 1:100 citrate buffer solution for 10 minutes, and cooled for 20 minutes. The slides were washed four times in PBS before 5-minute incubation in blocking serum (horse serum) (Novocastra-Newcastle Upon Tyne-United Kingdom, Novostain Universal Detection Kit-NCL-RTU-D) and 30-minute incubation with primary antibody (both at room temperature). They were rinsed four times in PBS, and then incubated with a biotinylated polyvalent antibody (Thermo-Scientific Cat No: TP-060-BN, Fremont-California, USA) for 10 minutes at room temperature. After three washes in PBS, streptavidin peroxidase was applied for 10 minutes at room temperature, and the slides were rinsed four more times in PBS. Tissues were further incubated for 20 minutes at room temperature in a solution of DAB (3,3'-diaminobenzidine) chromogen (Novocastra Liquid DAB Substrate Kit For Peroxidase, NCL-L-DAB, Newcastle Upon Tyne-UK). After a final wash in PBS, tissues were counterstained with Mayer's hematoxylin, washed in water, and cover slips were applied with mounting media.

**Figure 1:** Pox virus lesions in lung (arrows).

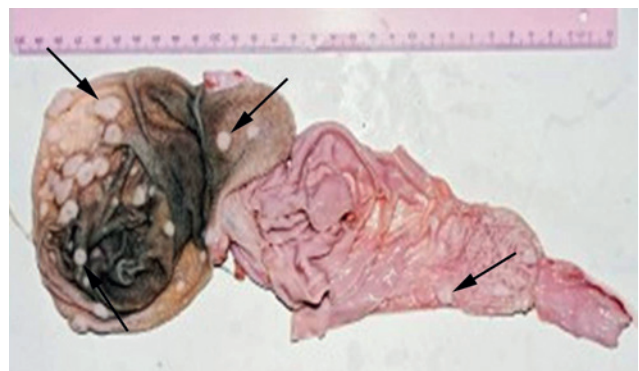


## RESULTS

Clinically, the disease first manifested as seromucous nasal discharge, lacrimation, and fever. Hyperemia of the bare skin was the initial epidermal lesion, followed by erythema and vesicular, pustular, and papular lesions that eventually crusted and scarred.

Necropsy revealed that the skin lesions involved the full depth of the epidermis, dermis, and even adjacent muscle

**Figure 2:** Typical pox lesions in gastrointestinal system (arrows).

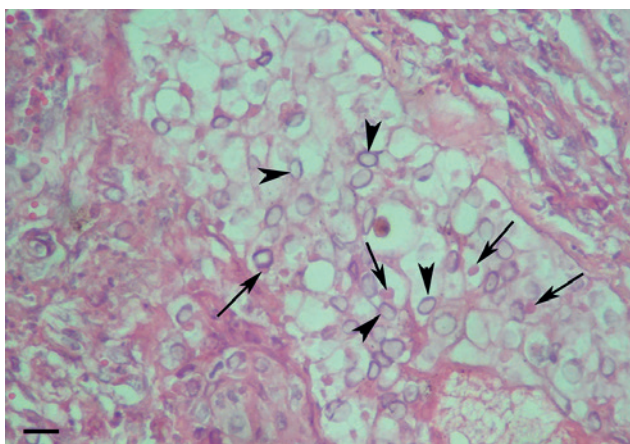


in some cases. In addition to the dermal lesions, the lungs, rumen, abomasum, heart, and kidneys were severely affected (Fig.1 and 2). Numerous hard and whitish foci were present on all lungs, rumens, and on 10 lambs' kidneys. The gastrointestinal tract, including the mouth and tongue to the anus, was affected in eight cases. Large white lesions were present on the epi- and endocardial areas of five lamb hearts.

The histopathological findings were characteristic for sheep pox infection (19, 20). The most prominent were intracytoplasmic inclusion bodies and cellules claveleuses with vacuolated nuclei and margination of the nucleoli and chromatin in all affected tissues. In the skin, hyperplasia and acanthosis with rete ridges were common in epidermal lesions, often with cell degeneration and necrosis. Intracytoplasmic inclusion bodies were present in numerous degenerated cells (Fig. 3). Coagulation necrosis and thrombosis developed in some blood vessels supplying the papules. Edema and mainly mononuclear cells and scant neutrophil infiltrations were common. Degenerative and necrotic changes were also seen in adnexal tissues of the epidermis like hair follicles and sebaceous glands.

In addition to the skin, the most affected organs were the lung and rumen. Pox lesions were detected in two cases in the heart and kidneys. The initial lesions in the lungs were alveolar edema and hyperemia of the alveolar septa. Proliferative alveolitis, bronchiolitis, and bronchitis with lymphocytic infiltrations were common findings. Necrotic cells and cellules claveleuses were seen in the septal tissue and epithelial cells of affected lungs (Fig. 4). Microscopic lesions

**Figure 3:** Pox virus lesions in dermis, cellules claveleuses (arrow heads), intracytoplasmic inclusion bodies (arrows). Haematoxylin- Eosin, Bar=50µm.



were even noted in tissues that appeared grossly normal. In the others, organ microscopic findings were similar to those of the skin and pulmonary lesions.

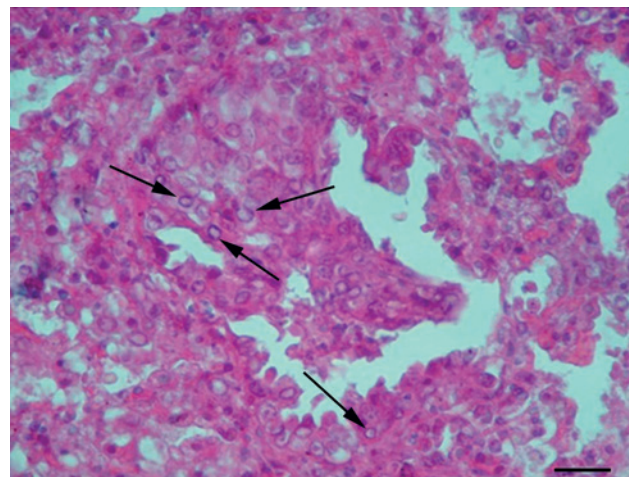
Immunohistochemical findings were similar in all affected tissues. A marked decrease in caspase-3,-5,-7 and -9 immunoreactions were observed in pox lesions compared to normal tissue. Severity and size of the lesions were related to the caspase-3,-5,-7 and -9 reactions where decreased immunopositivity was seen to a greater extent in large lesions compared to smaller ones. In skin lesions a marked inhibition of caspase-3,-5,-7 and -9 was observed. While a strong reaction of caspase-3,-5,-7 and -9 was seen in normal tissue and all layers of the epidermis (Fig. 5), only a small number of epithelial cells were positive in the pox lesions (Fig. 6). Compared to the controls, inhibition of caspase-3,-5,-7 and -9 was also prominent in hair follicles and glands (Fig. 7, 8). Similar findings were seen in dermal cells with pox lesions. Caspase-3 inhibition was marked in papules and necrotic lesions.

In the lungs, the proliferative lesions were slightly positive for caspase-3,-5,-7 and -9 compared with normal tissue. Decreased caspase-3,-5,-7 and -9 activity was prominent in both the alveoli and bronchi or bronchioles compared to control tissues (Fig. 9, 10). Similar findings were observed in all visceral organ lesions.

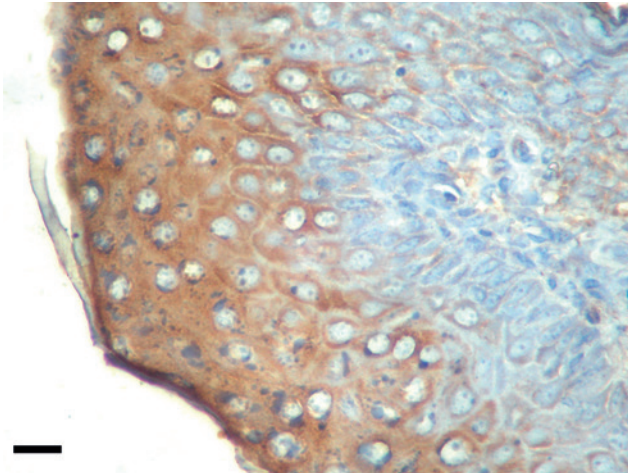
## DISCUSSION

Apoptosis is triggered by a variety of stimuli, including cell-surface receptors, the mitochondrial response to stress and factors released from cytotoxic T cells (12, 21). Initiation

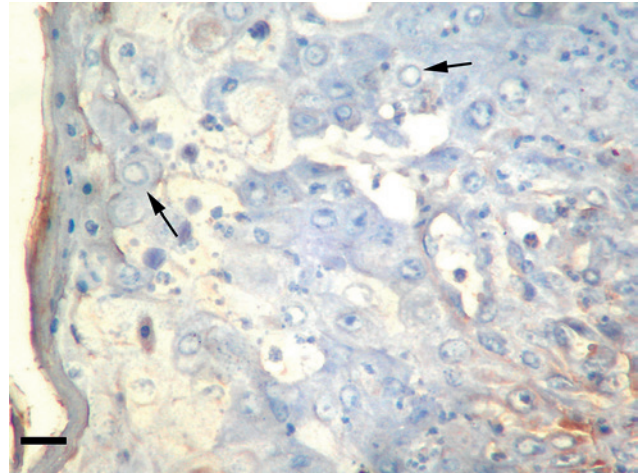
**Figure 4:** Typical "Cellules claveleuses" (arrows) in the hyperplastic bronchiole epithelial cells (arrows), Haematoxylin- Eosin, Bar = 100 µm.



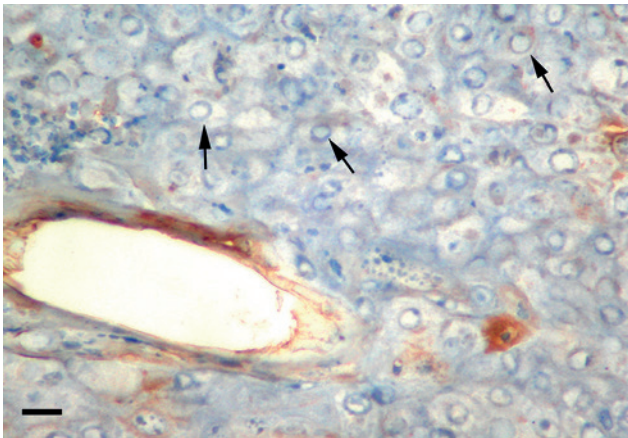
**Figure 5:** Strong positive reaction in normal epidermis with immunostaining of Caspase-3. Avidin-biotin peroxidase complex method, Mayer's Haematoxylin counter stained. Bar=50µm.



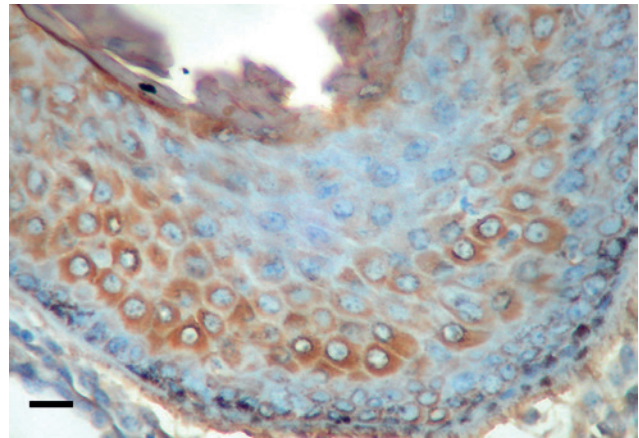
**Figure 6:** Inhibition of the Caspase-3 reaction in pox virus lesion, cellules claveleuses (arrows), Avidin-biotin peroxidase complex method, Mayer's Haematoxylin Counter stained. Bar=50µm.



**Figure 7:** Inhibition of Caspase-9 reaction in pox virus lesions, hair follicle, cellules claveleuses (arrows). Avidin-biotin peroxidase complex method, Mayer's Haematoxylin counter stained. Bar=50µm.



**Figure 8:** A strong positive Caspase-9 immunostaining in normal hair follicle cells. Avidin-biotin peroxidase complex method, Mayer's Haematoxylin counter stained. Bar=50µm.

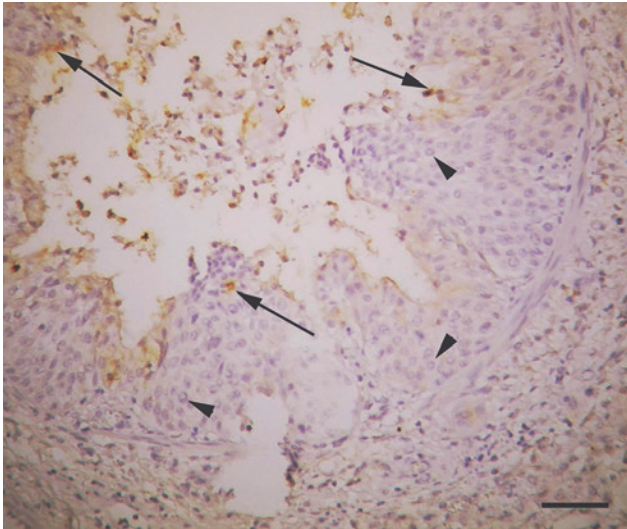


of the apoptotic mechanism occurs in one of two ways in mammals, and involves tumor necrosis factor (TNF)/TNF receptor (TNFR) and FAS ligand (22-24). The binding of TNF to TNF-R1 has been shown to initiate the pathway that leads to caspase activation via the intermediate membrane proteins TNF and FAS-associated death domains. The interaction between Fas and FasL results in the formation of the death-inducing signaling complex that contains the FAS-associated death domain-containing protein (FADD) (14, 25, 26) and some caspases such as caspase-8 and -10 (20, 27). Recent studies have identified death effector domains in the prodomain of caspase-10, suggesting that these regulatory

domains can process and activate other caspases (14, 26). Caspase-1, -4, -5, -11 and -12 are highly homologous (13, 28). Caspase-12 localizes in the endoplasmic reticulum (ER) and mediates apoptosis under ER stress, which is mainly caused by the accumulation of proteins in the ER lumen and/or the perturbation of calcium ion homeostasis. These conditions can lead to the translocation of caspase-7 from the cytosol to the ER surface (29). The functions of mitochondria in this type of apoptosis vary. The activated caspase-12 then activates other caspases, i.e., caspase-9, -3, -6 and -7 (13).

In the present study, caspase-3, -5, -7 and -9 were not highly expressed in lesions compared to control tissue.

**Figure 9:** Slight immunoreaction of Caspase-3 (arrows) compare to control in pox virus lesion, cellules claveleuses (arrowshead), Avidin-biotin peroxidase complex method, Mayer's Haematoxylin Counter stained. Bar=200µm.



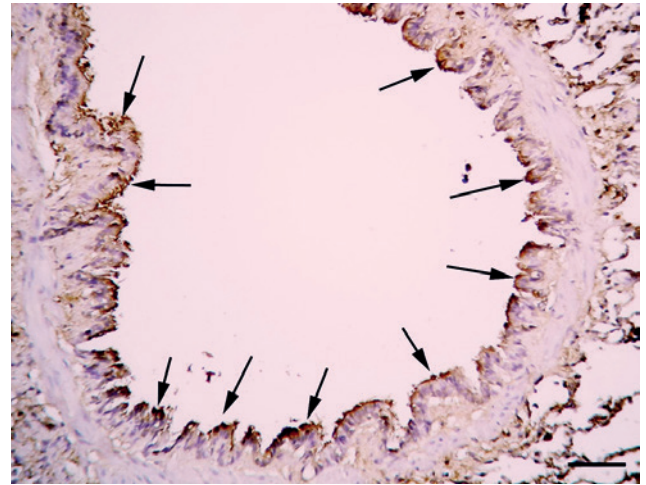
Immunoreactions of caspase-3, -7 and -9 signals can be blocked by TNF/TNFR or FAS ligand pathways, which may be active following sheep poxvirus infection (14, 30, 31). Caspase-5 and -12 are highly homologous, so it was thought that caspase-5 may use the same pathway as caspase-12. Mitochondrial injury may therefore be one of the pathogenetic mechanisms of caspase inhibition in sheep poxvirus infection.

The apoptotic cascade leads to the activation of the effector caspases, such as caspase-3 and -6. These caspases are responsible for cleaving key cellular proteins, e.g., cytoskeletal proteins, that lead to the typical morphological changes, observed in apoptotic cells (15-17, 32).

Viral replication is cellular function dependent. Viral protein synthesis, morphogenesis, and viral release, diverts and exhausts cellular function which destabilizes cellular homeostasis and integrity. This can lead to activation of the intrinsic apoptosis pathway. Therefore, it is important that apoptosis via the caspase cascade be inhibited or delayed to ensure virus replication (11). In the present study, caspase-3 inhibition was more prominent in old papules. This may explain the severe cellular destruction due to sheep poxvirus infection.

Numerous viruses have pro-apoptotic properties, which may contribute to the release of virus particles from the cell. The execution of pro-apoptotic functions may also be advantageous; for example, if apoptosis of an infected cell

**Figure 10:** Strong positive caspase-3 immureaction in normal bronchial epithelial cells (arrows). Avidin-biotin peroxidase complex method, Mayer's Haematoxylin counter stained. Bar=200µm.



leads to phagocytosis by another cell, the virus may be able to transfer to cells that it cannot directly infect. Some viruses may contain both anti- and pro-apoptotic functions (15, 29). This study revealed that the sheep poxvirus has anti-apoptotic activity.

Poxviruses express anti-apoptotic proteins that can inactivate inducers of apoptosis (2, 10). Here we examined sheep poxvirus in a naturally occurring infection and demonstrated marked inhibition of caspases in lesions. Our results suggest that the proliferative reaction in pox viral lesions is more prominent than apoptotic activity due to caspase-3 inhibition. This study also showed that the necrosis in the poxvirus lesions resulted from normal necrosis and was suggested to be caused by the virus and not by apoptosis.

Viral anti-apoptotic functions may be involved in diminishing effector cell efficacy, but caution is warranted before making this assumption. Virus-infected cells are generally lysed by T cells if the T-cell receptor is triggered, despite the presence of anti-apoptotic mechanisms. Poxviruses secrete proteins that bind to cytokines, which then activate death receptor-mediated apoptosis. This probably represents the earliest possible defense against apoptosis (33, 34). A similar mechanism may occur in sheep pox, but further studies are necessary to clarify the processes.

In conclusion, the immunohistochemical findings in sheep pox lesions suggest that inhibition of caspases -3,-5,-7, and -9 in lesioned skin may play a significant role in disease pathogenesis.

## REFERENCES

1. Singari, N. A., Moorthy, A.S. and Rama, R. P.: Sheep pox. *Lives. Adv.* 15: 40-42, 1990.
2. Everett, H. and McFadden, G.: Poxviruses and apoptosis: a time to die. *Curr. Opin. Microbiol.* 5: 395-402, 2002.
3. Bhanuprakash, V., Moorthy, A. R. S., Krishnappa, G., Gowda, R. N. S. and Indrani, B. K.: An epidemiological study of sheep pox infection in Karnataka. *Rev. Sci. Tech.-OIE.* 24: 909-920, 2005.
4. Ramprabhu, R., Priya, W. S. S., Chandran, N. D. J., Mohan, A. C. and Prathaban, S.: Clinical, hematological, epidemiological and virological studies in two sheep pox outbreaks. *Ind. J. Small Rum.* 8:129-130,2002.
5. Yager, J.A., Scott D.W. and Wilcock, B.P.: The skin and appendages. In: Jubb, K.V.F., Kennedy, P.C. and Palmer, N. (Eds.): *Pathology of domestic animals.* Academic Press, San Diego CA, pp. 628-644, 1993.
6. Haligur, M. and Ozmen, O.: Immunohistochemical detection of matrix metalloproteinase (MMP) and epidermal growth factor receptor (EGFR) during sheep pox infection. *Rev. Vet. Med.* 160:574-558, 2009.
7. Gulbahar, M. Y., Davis, W. C., Yuksel, H. and Cabalar, M.: Immunohistochemical evaluation of inflammatory infiltrate in the skin and lung of lambs naturally infected with sheep poxvirus. *Vet. Pathol.* 43: 67-75, 2006.
8. Jones, T. C., Hunt, R. D. and King, N. W.: Disease caused by viruses. In: Jones, T. C., Hunt, R. D. and King, N. W. (Eds.): *Veterinary Pathology.* Williams and Wilkins, Baltimore, pp.202-210, 1997.
9. Li, P., Nijhawan, D. and Wang, X.: Mitochondrial Activation of Apoptosis. *Cell.* 116: 57-59, 2004.
10. Peter, C., Turner, R.W. and Moyer, C.: Control of Apoptosis by Poxviruses. *Sem. Virol.* 8: 453-469, 1998.
11. Salvesen, G. S. and Dixit, V. M.: Caspases: intracellular signaling by proteolysis. *Cell.* 91: 443-446, 1997.
12. Earnshaw, W. C., Martins, L. M. and Kaufmann, S. H.: Mammalian caspases: structure, activation, substrates, and functions during apoptosis. *Annu. Rev. Biochem.* 68: 383-424, 1999.
13. Morishima, N., Nakanishi, K., Takenouchi, H., Shibata, T. and Yasuhiko, Y.: An endoplasmic reticulum stress-specific caspase cascade in apoptosis. Cytochrome c-independent activation of caspase-9 by caspase-12. *J. Biol. Chem.* 277: 34287-34294, 2002.
14. Fan, T. J., Han, L. H., Cong, R. S. and Liang, J.: Caspase Family Proteases and Apoptosis. *ActaBioch. Bioph. Sin.* 37: 719-727, 2005.
15. Bortner, C. D. and Cidlowski, J. A.: Cellular mechanisms for the repression of apoptosis. *Annu. Rev. Pharmacol.* 42: 259-281, 2002.
16. Gregersen, P. K.: Modern genetics, ancient defenses, and potential therapies. *New Engl. J. Med.* 356: 1263-1266, 2007.
17. Yuan, J. and Horvitz, H. R.: A first insight into the molecular mechanisms of apoptosis. *Cell.* 116: 53-56, 2004.
18. Hsu, S., Raine, L. and Fanger, H.: Use of avidin-biotinperoxidase complex (ABC) in immunoperoxidase techniques: a comparison between ABC and unlabeled antibody (PAP) procedures. *J. Histochem. Cytochem.* 29, 577-580, 1981.
19. Yeruham, I., Pearl, S., Abraham, A. and Algazi, R.: Simultaneous infections: lambs with contagious ecthyma and sheep pox or contagious ecthyma and papillomatosis. *Rev. Med. Vet.* 49: 1115-1120, 1998.
20. Beytut, E.: Sheep pox virus induced proliferation of type II pneumocytes in the lungs. *J. Comp. Path.* 143, 132-141, 2010.
21. Adrain, C. and Martin, S. J.: The mitochondrial apoptosome: a killer unleashed by the cytochrome seas. *Trends Biochem. Sci.* 26: 390-397, 2001.
22. Wajant, H.: The Fas signaling pathway: more than a paradigm. *Science*, 296: 1635-1636, 2002.
23. Boldin, M. P., Varfolomeev, E. E., Pancer, Z., Mett, I. L., Camonis, J. H. and Wallach, D.: A novel protein that interacts with the death domain of Fas/APO1 contains a sequence motif related to the death domain. *J. Biol. Chem.* 270: 7795-7798, 1995.
24. Chinnaiyan, A. M., O'Rourke, K., Tewari, M. and Dixit, V. M.: A novel death domain-containing protein, interacts with the death domain of Fas and initiates apoptosis. *Cell.* 19: 81: 505-512, 1995.
25. Chen, G. and Goeddel, D. V.: TNF-R1 signaling: a beautiful pathway. *Science* 296: 1634-1635, 2002.
26. Fernandes-Alnemri, T., Armstrong, R. C., Krebs, J., Srinivasula, S. M., Wang, L., Bullrich, F., Fritz, L. C., Trapani, J. A., Tomaselli, K. J., Litwack, G. and Alnemri, E. S.: In vitro activation of CPP32 and Mch3 by Mch4, a novel human apoptotic cysteine protease containing two FADD-like domains. *Proc. Natl Acad. Sci.* 93: 7464-7469, 1996.
27. Muzio, M., Chinnaiyan, A. M., Kischkel, F. C., O'Rourke, K., Shevchenko, A., Ni, J., Scaffidi, C., Bretz, J. D., Zhang, M., Gentz, R., Mann, M., Krammer, P. H., Peter, M. E. and Dixit, V. M.: FLICE, a novel FADD-homologous ICE/CED-3-like protease, is recruited to the CD95 (Fas/APO-1) death-inducing signaling complex. *Cell.* 85: 817-827, 1996.
28. Wang, S., Miura, M., Jung, Y. K., Zhu, H., Li, E. and Yuan, J.: Murine caspase-11, an ICE-interacting protease, is essential for the activation of ICE. *Cell.* 92: 501-509, 1998.
29. Rao, R.V., Hermel, E., Castro-Obregon, S., del Rio, G., Ellerby, L. M., Ellerby, H. M. and Bredesen, D. E.: Coupling endoplasmic reticulum stress to the cell death program. *J. Biol. Chem.* 276: 33869-33874, 2001.
30. Kischkel, F. C., Hellbardt, S., Behrmann, I., Germer, M., Pawlita, M., Krammer, P. H. and Peter, M. E.: Cytotoxicity-dependent APO-1 (Fas/CD95)-associated proteins form a death-inducing signaling complex (DISC) with the receptor. *EMBO J.* 14: 5579-5588, 1995.
31. Chinnaiyan, A. M., O'Rourke, K., Yu, G. L., Lyons, R. H., Garg, M., Duan, D. R., Xing, L., Gentz, R., Ni, J. and Dixit, V. M.: Signal transduction by DR3, a death domain-containing receptor related to TNFR-1 and CD95. *Science.* 8: 274: 990-992, 1996.
32. Benedict, C. A., Norris, P. S. and Ware, C. F.: To kill or be killed: viral evasion of apoptosis. *Nat. Immunol.* 3: 1013-1018, 2002.
33. Kirchhoff, S., Sebens, T., Baumann, S., Krueger, A., Zawatzky, R., Li-Weber, M., Meinel, E., Neipel, F., Fleckenstein, B. and Krammer, P. H.: Viral IFN-regulatory factors inhibit activation-induced cell death via two positive regulatory IFN regulatory factor 1-dependent domains in the CD95 ligand promoter. *J. Immunol.* 168: 1226-1234, 2002.
34. Liang, C., Oh, B.H., and Jung, J.U.: Novel functions of viral anti-apoptotic factors. *Nat. Rev. Microbiol.* 13: 7-12, 2015.