

Solitary Distal Limb Mast Cell Tumor in a Three Year Old Arabian Mare

Horn-Mandel, H.,¹ Valentine, B.A.,³ Brenner O.,² Tatz, J.A.¹ and Kelmer, G.^{1*}

¹ Large Animal Department, Veterinary Teaching Hospital, Koret School of Veterinary Medicine, Robert H. Smith Faculty of Agriculture, Food and Environment, the Hebrew University of Jerusalem, Rehovot, Israel.

² Department of Veterinary Resources, Weizmann Institute, Rehovot, Israel.

³ OSU Veterinary Diagnostic Laboratory, College of Veterinary Medicine.

* **Corresponding Author:** Dr. Gal Kelmer, DVM, DACVS, Large Animal Department, Veterinary Teaching Hospital, Koret School of Veterinary Medicine, Robert H. Smith Faculty of Agriculture, Food and Environment, The Hebrew University of Jerusalem, Beit Dagan, 76100, Israel. Tel: 03-9688532, Fax: 03-9604079. Email: galkelmer@hotmail.com

ABSTRACT

A 3 year old Arabian mare was presented to the Veterinary Teaching Hospital, Koret School of Veterinary Medicine, with a mass on the dorsal aspect of the left metatarsus, immediately distal to the tarsus. Ultrasonographic evaluation showed a soft tissue mass with some dotted hyperechogenicity and no involvement of the extensor tendons. Radiographs demonstrated a mass of soft tissue opacity with areas of mineralization and no bone involvement. The mass was injected with triamcinolone (18 mg) but continued to grow. It was removed surgically under general anesthesia and submitted for histopathologic examination. Microscopic evaluation demonstrated a mast cell tumor which had been excised with clean margins. Four years later, there was no recurrence and the mare was used, as intended, for reproductive purposes.

Keywords: Mast cell tumor, horse, surgery.

INTRODUCTION

Mast cell tumors (MCT) represent less than 1% of diagnosed dermatological lesions in horses (1) and about 3% (2) - 7% (1) of equine cutaneous and mucocutaneous tumors. Some reports (1) suggest no breed predilection, higher occurrence in males and a wide age distribution (1-18 years of age with an average of 9.5 years) but others suggest that the Arabian breed maybe over represented (3, 4, 5).

MCT are usually benign and well demarcated firm solitary tumors of the skin or subcutaneous tissue of the head, neck, trunk or limbs, although MCT of the testes (6), eyes (7, 8), nasal cavity and nasopharynx (3), trachea (9) and synovial membrane (10) have also been reported. In addition, a multicentric form (11) and metastases to draining lymph nodes (12) were reported and a form of multiple mast cell tumors was described in foals (13). In general, the masses are slow growing, and usually not associated with pain or lameness.

Radiographic appearance of MCT in the equine limb is usually of soft tissue opacity with areas of granular mineralization. They are usually located in close proximity to a joint, but remain extracapsular, not involving the joint. Periosteal reaction may occur but is considered atypical (5, 14) and although radiological findings are rather consistent histopathology remains the gold standard of diagnosis.

The preferred treatment for MCT is complete surgical excision. In cases of incomplete surgical excision the tumor may spontaneously regress (4, 5) and there have been reports of complete spontaneous resolution (15). In the case reported here surgical excision of a solitary MCT was curative.

CASE HISTORY

A 3 year old Arabian mare was presented to the Veterinary Teaching Hospital of the Koret School of Veterinary Medicine, due to a mass in the dorsal metatarsal region, just distal to the tarsal joint in the left hind limb.

CLINICAL FINDINGS

At presentation, the mare was bright, alert and responsive and her physical parameters were within normal limits. The mass was circular, firm and well demarcated and the overlying skin appeared normal (Figure 1). The mare was 2/5 lame on the left hind limb (AAEP grading scale 0-5) (16) and did not respond to flexion tests. An ultrasound examination demonstrated that the mass did not involve the adjacent extensor tendons. On lateral radiographs the mass appeared as a soft tissue enlargement with small areas of opacity compatible with granular mineralization, without bone or joint involvement (Figure 2).

Due to the owner's complaint of a previous injury to the area, the mass was initially thought to be an area of inflammation and fibrosis and 18 mg of triamcinolone (Bristol

Myers Squibb, NY, USA) was injected intra-lesionally and the mare was sent home. A week later the owner reported that the mass had continued to grow and the mare was sent to the hospital for biopsy. Punch biopsies were acquired from the mass under standing sedation and local anesthesia. Samples were sent to bacteriology, mycology and histopathology. No growth was noted on either bacteriological or mycological samples.

Histologically, the sample was mainly composed of fibrous tissue with several small clusters of mast cells, surrounded by partly lytic eosinophils. The lesion was suspected to be inflammatory, with a suspected parasitic background. The unusual presence of mast cells raised the possibility of mast cell tumor, but their number was considered too low to confirm the diagnosis. A decision was made to undertake an excisional biopsy.

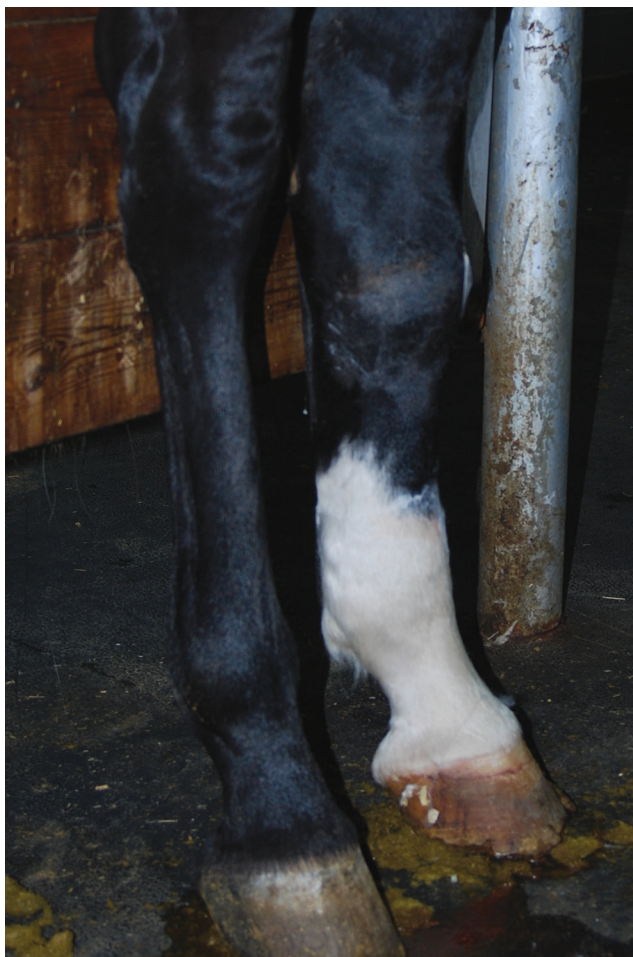

Figure 1: Photograph of both hind limbs of a 3 year old Arab mare. Notice the marked swelling on the dorsal aspect of the left metatarsus, just distal to the tarsal joint.

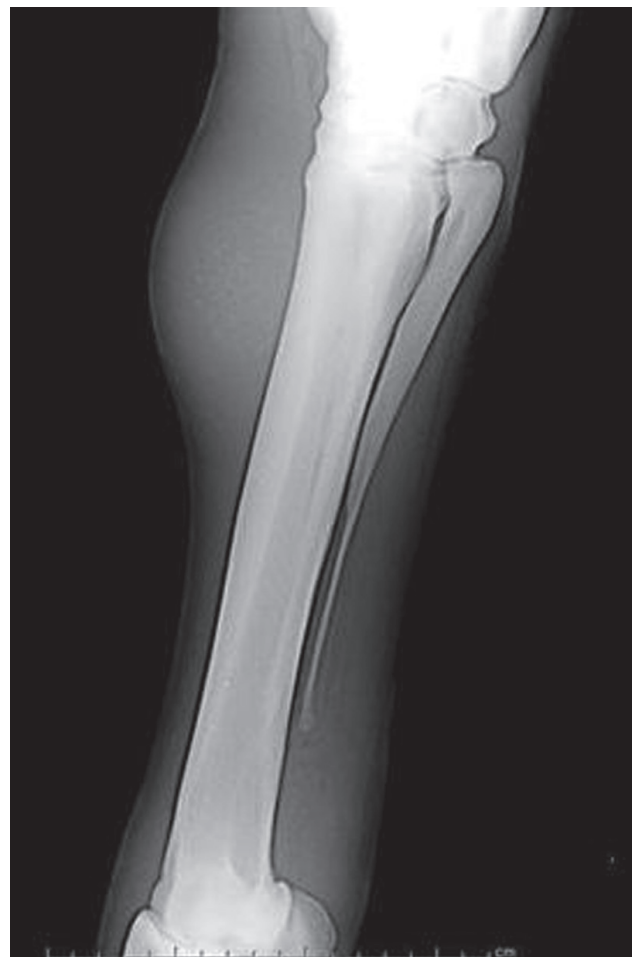

Figure 2: Lateral radiographs of the left hind limb of a 3 year old Arab mare. Notice the mass on the dorsal aspect of the third metatarsus. The mass is of soft tissue opacity with small areas of enhanced opacity. There is no periosteal reaction or joint involvement.

TREATMENT

The mass was removed under general anesthesia, an active drain was placed and the limb was aseptically bandaged. After surgical excision, the mass was incised, and small yellow granules were present which were suspected to be sulfur granules due to habronema infestation (Figure 3). Samples were, again sent to bacteriology, mycology and histology.

Post-operative care included an intravenous non-steroidal anti-inflammatory drug (Flunixin meglumine,

Norbrook laboratories Ltd, Newry, N.Ireland) and antimicrobials (Gentamicin, Gentaveto-5 pro injection, Biove Laboratories, Arendonk, Belgium and Penicillin G sodium, Sandoz GmbH, Kundl, Austria) and the area was bandaged.

HISTOLOGICAL EXAMINATION

Histopathologic examination of the tumor stained with hematoxylin eosin (H&E) showed a well-demarcated mass surrounded by a thick collagenous capsule. The mass was composed of clusters of lightly to less commonly moderately granular mast cells admixed with eosinophils within a moderate amount of fibrous stroma. Mitotic figures were not identified in the mast cells. Giemsa stain demonstrated a variable complement of metachromatic cytoplasmic granules in the mast cells. Collections of hyper-eosinophilic material admixed with lytic nuclei - foci of collagen degeneration (collagenolysis) were a prominent component of the neoplasm. They were of variable shape and size and correspond to the yellow-brown granules seen grossly. Tissue at the rim of these collections was frequently discolored and did not contain nuclei. Throughout the mass there was mild to moderate infiltration of eosinophils, lymphocytes, siderophages and scattered multinucleated giant cells. This histologic picture is typical of equine mast cell tumor (17) (Figure 4).

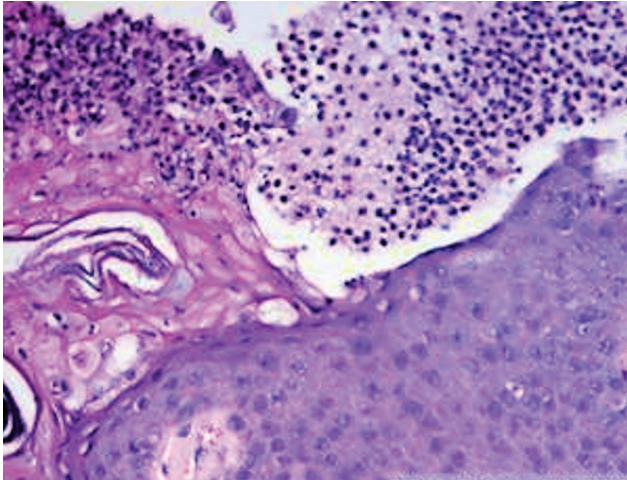


Figure 3: A mass removed from a left hind limb of a 3 year old Arab mare. The mass was incised along its long axis. In the center of the mass there are multiple pale brown-yellow granules.

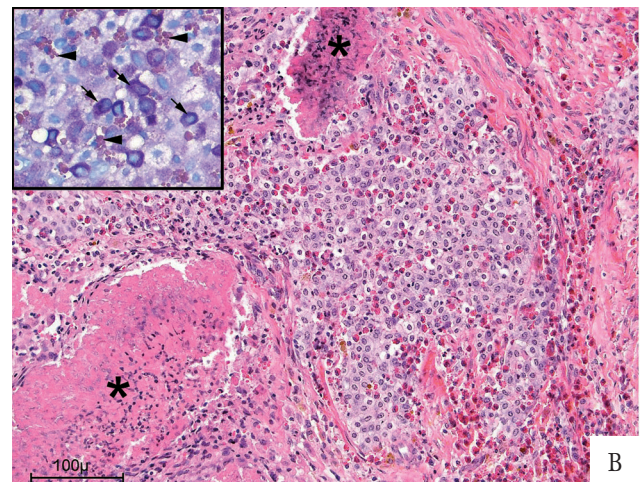
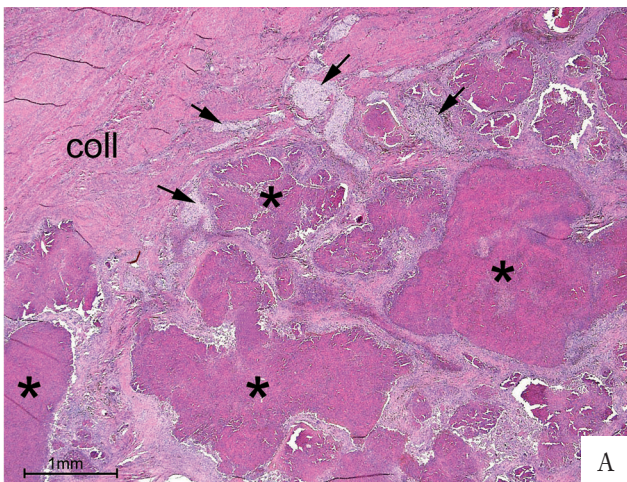


Figure 4A and 4B: Histologic findings of the mass from figure 3. 4A) Low magnification. The bulk of the mass is occupied by foci of collagen degeneration (asterisks) separated by moderate amount of fibrous stroma. Clusters of mast cells are identified with arrows. Part of the collagenous capsule surrounding the mass is seen at the top right-hand corner. (H&E $\times 20$); 4B) High magnification. In the center of the field there is a cluster of mast cells admixed with eosinophils. The edges of 2 foci of collagen degeneration are marked with asterisks (H&E $\times 20$). Inset: High magnification of Giemsa staining. Mast cells with a large number of metachromatic granules are marked with arrows. Most of the mast cells in the field show paler, less prominent cytoplasmic granulation. Eosinophils are marked with arrowheads (Giemsa $\times 40$).

OUTCOME

The mare was referred to the hospital again one year later with a suspected ovarian granulosa theca cell tumor (GCT). The owner complained on recent stallion like behavior and an enlarged cystic left ovary was found by the referring veterinarian. An ovariectomy was performed by standing laparoscopy and the left ovary was indeed diagnosed as GCT by histological examination. The mare had foaled successfully the following season. On both occasions the mare was not lame on the left hind limb, there was no recurrence of the tumor with only a small area of leukotrichia where the MCT was previously removed.

DISCUSSION

In the mare presented here, it was not possible to diagnose MCT based on punch biopsy alone. Histopathologically, MCT is sometimes misdiagnosed, especially when chronic and when containing areas of extensive mineralization with small localized areas of mast cells, or when it contains significant eosinophilic inflammation. In such cases it must be differentiated from calcinosis circumscripta and parasitic eosinophilic granulomatous dermatitis (e.g. habronematosis) (1, 3) and equine eosinophilic granuloma with collagen degeneration. (17). Fine needle aspirates (FNA) of the lesion which are both easy and fairly safe to perform may raise the suspicion of a MCT due to the typical cytological appearance of mast cells (11,18) but do not provide a conclusive diagnosis. Once the mass was completely removed the histological diagnosis was clear, and was mainly based on the presence of clusters of mast cells, a finding which would not be compatible with the other differential diagnoses. Based on our experience we recommend excisional biopsy for suspected equine MCT whenever possible.

The radiographic presentation of MCT involving equine extremities is fairly typical whereas other differential diagnosis for a partially mineralized soft tissue enlargement include calcinosis circumscripta, parasitic or foreign body granuloma (5). In our case, based on the radiographs, habronemiasis was suspected but histopathological examination of the excised mass demonstrated a MCT.

Although MCT is usually well demarcated, and does not involve nearby structures, as in the current case, joint, bone and tendon involvement should always be ruled out, especially when pain or lameness are present. Taylor *et al.* reported a case of MCT with involvement of the tarsocrural joint (10).

Complete surgical excision is typically curative, with no recurrence (1). In cases where complete surgical excision is not an option, intralesional injection of glucocorticoid (3) or cisplatin, oral administration of cimetidine or hydroxyzine hydrochloride (H-1 receptor antagonist which decreases mast cell degranulation and thus secondary inflammation), cryosurgery or radiotherapy (11) may be considered. Nevertheless, recurrence of MCT in areas remote from the primary lesion has been reported and may occur years after resolution of the primary lesion (3). In the current case, at the time of writing, 4 years post-operatively, there is no sign of recurrence either at the tumor site or at any remote site in the body.

Oral administration of glucocorticoids is well documented for reducing the size or even resolving canine mast cell tumors (19, 20). In dogs these tumors are often metastatic and wide margins of excision are recommended with at least one fascial plane deeper than the tumor. Reduction of the tumor size by steroids may allow the surgeon to achieve clean margins of excision. This is not the case in horses where MCT are generally benign. However, reduction of tumor size will reduce damage to surrounding structures and formation of dead space, thus encouraging better healing. In the case presented here an intralesional administration of triamcinolone was not found to be effective in reducing the size of the tumor. Other steroids may be more effective in horses but species differences may render equine MCT refractive to steroids.

Since the Arabian breed has a predilection for MCT, when one is presented with a young Arabian mare suffering from a firm mass on a limb, adjacent to a joint, as was the case here, one should include MCT high in the differential diagnosis. The radiographic appearance of a well-defined soft tissue mass with granular mineralization is highly indicative of MCT. Surgical removal of the tumor serves both for final diagnosis and, as in the current case, is typically curative.

REFERENCES

1. Scott, D.W. and Miller, W.H.: Neoplastic and non-neoplastic tumors. In: Scott, D.W. and Miller, W.H: Equine Dermatology, Saunders, Philadelphia, pp.698-795, 2003.
2. Valentine, B.A.: Survey of equine cutaneous neoplasia in the Pacific Northwest. *J Vet. Diagn. Invest.* 18:123-126, 2006.
3. Mair, T.S and Krudewig, C.: Mast cell tumors (mastocytosis) in the horse: A review of the literature and report of 11 cases. *Equine Vet. Edu.* 20:177-182, 2008.
4. McEntee, M.F.: Equine cutaneous mastocytoma: morphology, biological behaviour and evolution of the lesion. *J. Comp. Pathol.* 104:171-8, 1991.
5. Samii, V.F., O'Brien, T.R. and Stannard, A.A.: Radiographic features of mastocytosis in the equine limb. *Equine Vet. J.* 29:63-66, 1997.
6. Hodder, D.J., Peterson, T., Claes, A., Liu, I.K.M. and Ball, B.A.: Unilateral testicular mastocytoma in a Peruvian Paso stallion. *Equine Vet. Edu.* 20:172-175, 2008.
7. Hum, S. and Bowers, J.R.: Ocular mastocytosis in a horse. *Aust. Vet. J.* 66:32, 1989.
8. Martin, C.L. and Leipold, H.W.: Mastocytoma of the globe in a horse. *J. Am. Anim. Hosp. Assoc.* 8:32-34, 1972.
9. Wenger, I.E. and Caron, J.P.: Tracheal mastocytosis in a horse. *Can. Vet. J.* 29: 563-565, 1988.
10. Taylor, S., Martinelli, M.J., Trostle, S.S. and Kemper, T.: Articular mastocytosis in the tarsocrural joint of a horse. *Equine Vet. Edu.* 17: 207-211, 2005.
11. Milward, L.M., Hamberg, A., Mathews, J., Machado-Parrula, C., Premanandan, C., Hurcombe, S.D., Radin, M.J. and Wellman, M.L.: Multicentric mast cell tumors in a horse. *Vet. Clin. Pathol.* 39:365-370, 2010.
12. Reppas, G.P. and Canfield, P.J.: Malignant mast cell neoplasia with local metastasis in a horse. *N. Z. Vet. J.* 44:22-25, 1996.
13. Prasse, K.W., Lundvall, R.L. and Chevillie, N.F.: Generalized mastocytosis in a foal, resembling urticaria pigmentosa of man. *J. Am. Vet. Med. Assoc.* 166:68-70, 1975.
14. Cole, R., Chesen, A.B., Pool, R. and Watkins, J.: Imaging diagnosis- equine mast cell tumor. *Vet. Radiol. Ultrasound.* 48:32-34, 2007.
15. Pascoe, R.R.R. and Knottenbelt, D.C.: Neoplastic conditions. In: Pascoe, R.R.R. and Knottenbelt: *Manual of Equine Dermatology*, Saunders, Hong-Kong, pp. 241-279, 1999.
16. *Guide for Veterinary Service and Judging of Equestrian Events* (ed 4). American Association of Equine Practitioners, Lexington, KY, 1991, p. 19.
17. Scott, D.W.: Neoplastic diseases. In: Scott, D.W: *Large Animal Dermatology*, Saunderson, Philadelphia, pp.419-467, 1988.
18. Brown, H.M, Cuttino, E. and LeRoy, B.E.: A subcutaneous mass on the neck of a horse. *Vet. Clin. Pathol.* 36:109-113, 2007.
19. McCaw, D.L., Miller, M.A., Withrow, S.J., Brewer, W.G. Jr., Klein, M.K., Bell, F.W. and Anderson, S.K.: Response of canine mast cell tumors to treatment with oral prednisone. *J. Vet. Intern. Med.* 8:406-408, 1994.
20. Stanclift, R.M. and Glison, S.D.: Evaluation of neoadjuvant prednisone administration and surgical excision in treatment of cutaneous mast cell tumors in dogs. *J. Am. Vet. Med. Assoc.* 232:53-62, 2008.