

# Heart Base Abscess Caused by *Prevotella Oral* in a Dog

Joseph, R.,<sup>1\*</sup> Ohad, D.,<sup>2</sup> Dank, G.,<sup>3</sup> Blum, S.<sup>4</sup> and Milgram, J.<sup>1</sup>

<sup>1</sup> Department of Surgery, Koret School of Veterinary Medicine, The Hebrew University of Jerusalem, The Hebrew University of Jerusalem Israel.

<sup>2</sup> Department of Cardiology, Koret School of Veterinary Medicine, The Hebrew University of Jerusalem, The Hebrew University of Jerusalem Israel.

<sup>3</sup> Department of Oncology, Koret School of Veterinary Medicine, The Hebrew University of Jerusalem, The Hebrew University of Jerusalem Israel.

<sup>4</sup> Department of Veterinary Bacteriology Kimron Veterinary Institute, Bet-Dagan, Israel.

\* **Corresponding author:** Dr. Rotem Joseph, Levin Epstein 41/3, Rehovot, 76462 Israel, Tel: 972-52-8344585, Fax: 972-77-9400545. Email: rotemjoseph@gmail.com.

### ABSTRACT

A two-and-a-half year old, neutered, female Weimaraner was presented with a history of dyspnoea, coughing, retching, anorexia, vomiting and restlessness. A pyothorax with a hypoechoic mass at the heart base was diagnosed on thoracic ultrasound and cytology of the fluid aspirated from the thoracic cavity. An explorative thoracotomy was performed to assess the mass at the base of the heart and to flush and drain the thoracic cavity. The dog went into cardiac arrest and died immediately post operatively. The findings at surgery and the gross pathology, histopathology and culture were consistent with a heart base abscess and chronic pyothorax caused by *Prevotella spp.* *Prevotella spp.* constitute normal oral flora in dogs and cats and are known as abscess formatting agents, however, the means by which the pathological organism gained access to the pleural cavity could not be determined.

**Keywords:** *Prevotella*, Pyothorax, Heart base, Abscess.

### INTRODUCTION

*Prevotella spp.* is a gram-negative anaerobic bacterium found in a variety of domestic animals (1). *Prevotella spp.* constitute normal oral flora in dogs including the dental plaque (2, 3). The incidence of *Prevotella spp.* infection in humans due to dog and cat bite wounds is as high as 50% and 75% respectively (4). An infection, presumed to be caused by *Prevotella spp.*, introduced into the wound by licking, has also been reported in a dog (5).

The incidence of *Prevotella spp.* in canine and feline pyothorax is 6–26% and 9% respectively (6, 7). *Prevotella spp.* have been associated with abscesses at bite wounds sites (4), in the orbit (8) and in the meninges (9).

Bacteria as a cause of abscess formation in the thoracic cavity have been reported in the lungs (10, 11) and the mediastinum (12). Mediastinal abscessation has been associated

with actinomycosis (13, 14) and with suspected perforation of the oesophagus (12). To the best knowledge of the authors no reports of an abscess located at the base of the heart were found in the veterinary literature.

### CASE HISTORY

A two-and-a-half year old, neutered, female Weimaraner was presented to the Koret School of Veterinary Medicine (KSVM) with a history of dyspnoea, coughing, retching, anorexia, vomiting and restlessness of one-week duration. The dog had been presented to an emergency clinic 24 hours prior to presentation at the KSVM. Other abnormalities noted at the emergency clinic included weakness, pale mucous membranes, tachypnoea (52/min), dyspnoea, tachycardia (160/min) and dull heart sounds, bilaterally. Haematology and biochemistry were unremarkable except microcytic nor-

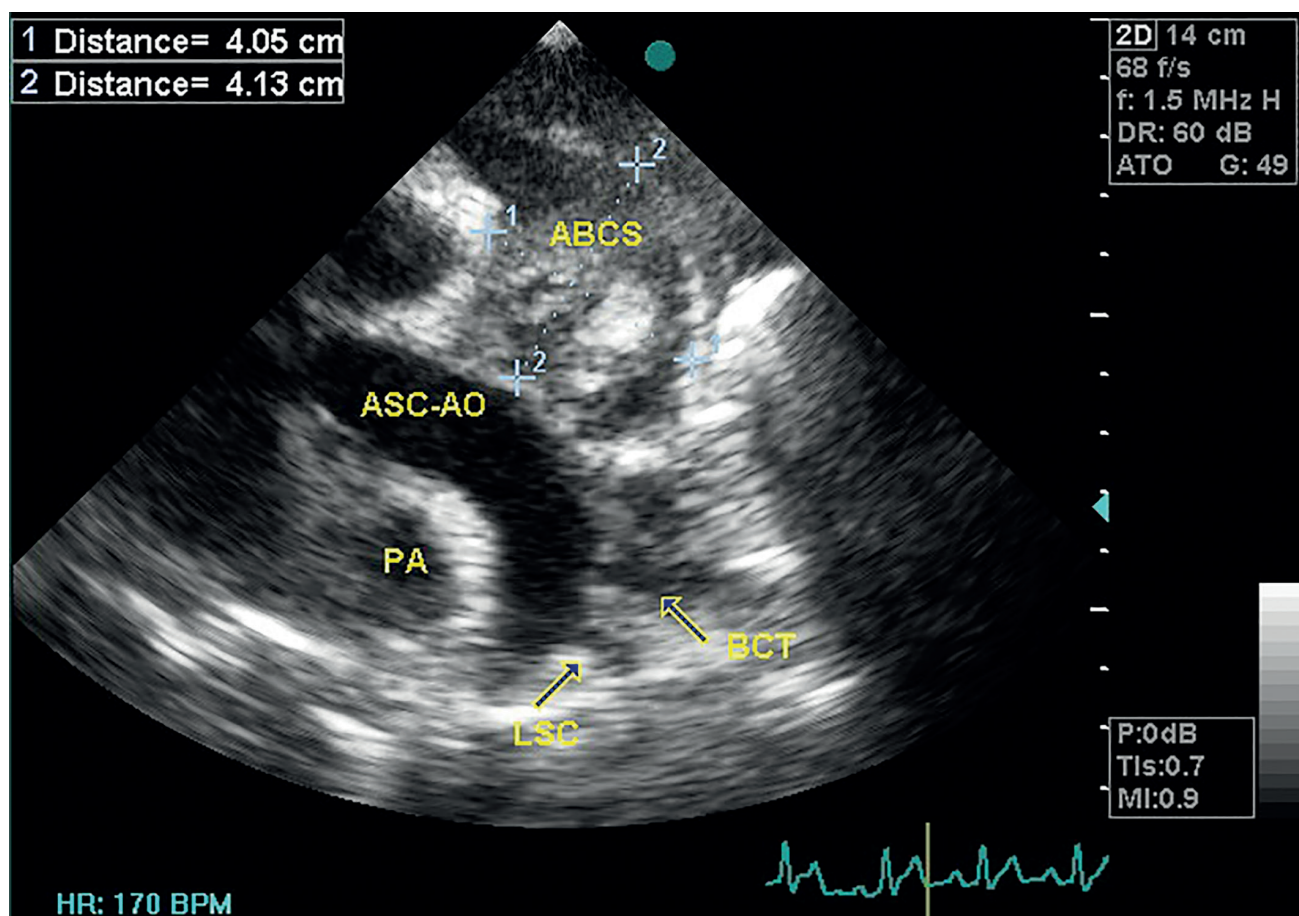
mochromic anaemia PCV (packed cell volume) = 30%, MCV (mean corpuscular volume) = 57.7 fl, Hb (haemoglobin) = 113 g/l, normal leukocyte count with mild toxicity and left shift (30% band cells), hypoalbuminaemia (20 g/l) and hyponatraemia (129 mmol/l). A large amount of anechoic fluid within the pericardial sac was diagnosed on thoracic ultrasound, causing a decrease in diastolic filling of the ventricles. Red coloured fluid was aspirated, but cytological evaluation of the fluid was not performed. Abdominal ultrasound was unremarkable.

Physical examination at the KSVM was unremarkable. The owners reported marked improvement, however, on thoracic auscultation, the heart sounds remained dull. Thoracic ultrasound was performed and a hypoechoic mass (approximately 4 cm × 4 cm) was detected at the base of the heart and caudal to the ascending aorta (Figure 1). In addition, a small amount of fluid within the pericardial and pleural cavities was seen as well as mild collapse of the right atrium

at the end diastole. The owners declined further diagnostic work up, and no treatment was prescribed.

Two weeks subsequent to the initial presentation, the dog's clinical signs recurred. A toxic leukocytosis ( $27.2 \times 10^9/l$ ) with 13% band cells and regenerative normocytic normochromic anaemia (PCV = 27%) was now present. Urine analysis was normal and faecal flotation was negative. On repeat thoracic ultrasound the hypoechoic heart base mass was seen to be unchanged. The pleura were thickened and irregular and a large quantity of anechoic fluid had accumulated within the pleural cavity. There was no recurrence of the cardiac tamponade.

Prior to performing thoracic radiography 1000 ml of purulent exudate was drained from the thoracic cavity by thoracocentesis. The mass could not be visualised on the chest radiographs but a dorsal displacement of the intrathoracic trachea was noted on the right lateral radiograph. The oesophagus was evaluated endoscopically and no abnormalities were detected.



**Figure 1:** A modified long-axis, left heart-base echocardiographic view of the aortic arch. The abscess (4.05 × 4.13 cm) is located next to the ascending aorta. ASC-AO = Ascending Aorta; BCT = Brachiocephalic Trunk; LSC = Left Subclavian Artery; ABCS = Abscess; PA = Pulmonary Artery.

An explorative thoracotomy was undertaken through a midline sternotomy. The endothoracic fascia immediately under the sternum was thickened, discoloured and highly vascular. Multiple ligations were required and a large amount of tissue, including the sternal lymph node had to be excised in order to gain access to the pleural cavity. A severe empyema was present and five hundred millilitres of pus was suctioned from the pleural cavity. All pleural surfaces were thickened, irregular and opaque, with numerous soft tissue masses varying in size from 0.2-3 cm. Adhesions were present both between lung lobes and between the lung lobes and the mediastinal pericardium as well as the body wall, making evaluation of the dorsal thoracic cavity difficult. These adhesions also complicated the approach to the pericardium and a subtotal pericardectomy would have required partial lung lobectomy.

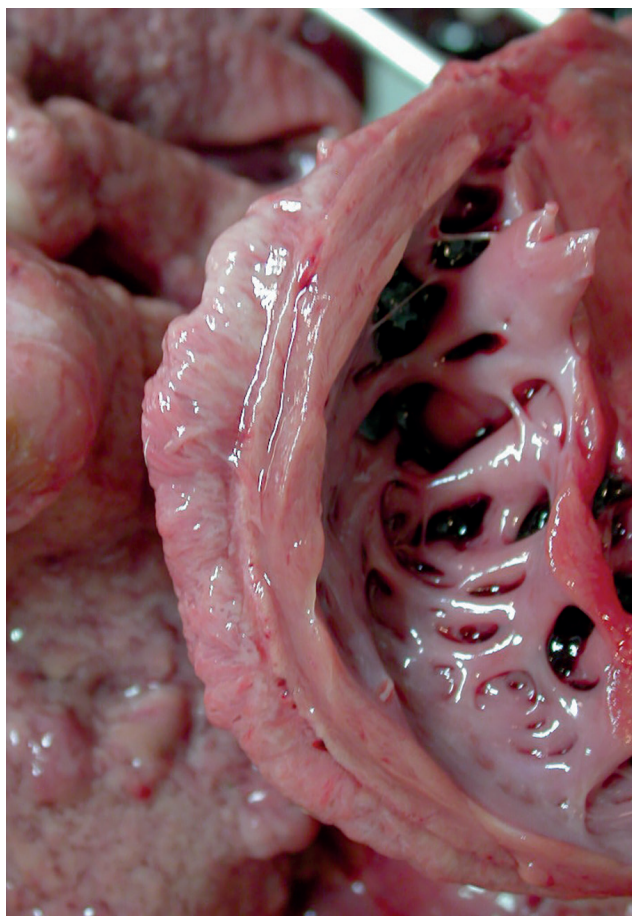
Following systemic deterioration, further exploration of the chest was halted. Prior to closure samples for histopathology, bacteriology and mycology were obtained. Chest

tubes were placed bilaterally prior to a routine closure of the chest. The dog suffered a cardiac arrest prior to fully recovering from the anaesthesia. All attempts to revive, including open chest cardiac massage were unsuccessful.

A post mortem was performed the following day: A 6 × 4 cm abscess was found at the heart base, surrounding the ascending aorta with a concurrent severe pleuritis, mediastinitis and pericarditis. On gross examination of the heart, an irregular, thickened (5-6 mm) epicardium was the only abnormality detected (Figure 2). No evidence was found to implicate the oesophagus or trachea as the source of the abscess.

On histopathological evaluation of the pericardium and epicardium, a severe infiltration of granulation tissue was noted (Figure 3). This tissue was characterized by new blood vessel formation as well as elongated spindle cells with activated nuclei, and presence of lymphocytes, macrophages and plasma cells. A similar process, with additional multifocal localized areas of dense connective tissue was found infiltrating the pleura. In some areas of the pleura, a process of encapsulation, characteristic of chronic abscess formation, had taken place. These abscesses contained a mixed population of inflammatory cells, mostly degenerated neutrophils, and haemosiderin (Figure 4). A homogenous population of bacteria (rods) could be identified among the cell debris (Figure 5). In other areas, in addition to the inflammatory process of the pleura, an intense proliferation and focal accumulation of mesothelial cells was observed. These proliferate cells were characterized by enlarged nuclei, prominent nucleoli and mitotic figures. A mild lymphocytic infiltration with occasional neutrophils was observed within the myocardium. The lung parenchyma was unaffected.

Samples of the pleura taken intraoperatively and at post mortem were sent for culture and sensitivity. The samples were inoculated on MacConkey (Difco, USA), Tryptose soy agar (Difco, USA) and Tryptose Blood agar plates (Difco, USA), which were incubated at 37°C aerobically; while a second blood agar plate was inoculated and incubated at 37°C anaerobically. After 48 hours of incubation, a growth of morphologically identical colonies was observed only on the anaerobic plates. The isolated bacterium was a gram negative, non-spore forming, catalase and indol negative bacteria. Final identification was made with API rapid 32A (BioMérieux, France). The bacterium was identified as *Prevotella oralis* with 87.6% confidence; leucine arylamidase (LeuA) being the only atypical test.

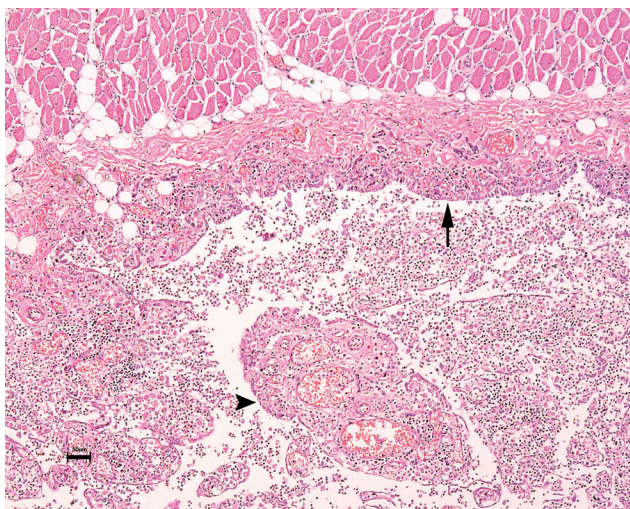


**Figure 2:** Right ventricle wall. Note the thick irregular epicardium suggesting a chronic process of a few weeks duration.

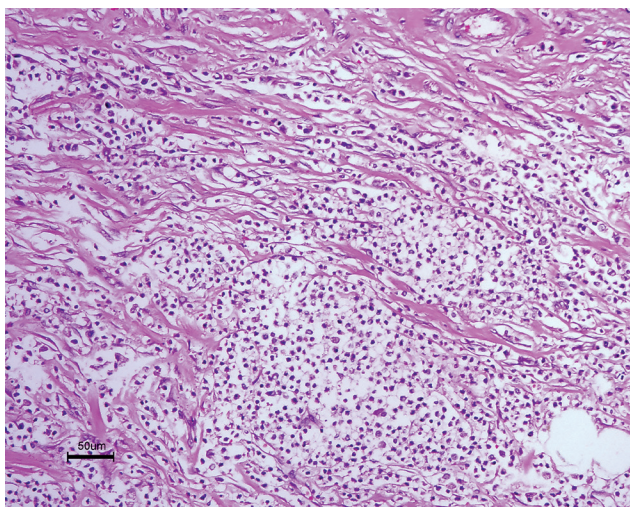
## DISCUSSION

*Prevotella spp.* are residents of the canine and feline oral cavity (2, 3). Inhaled or ingested plant material, oesophageal perforation, penetrating thoracic wounds and haematogenous spread have all been suggested as means by which the organism may gain access to the thoracic cavity.

In this case thoracic bite wounds (or penetrating thoracic injury) were ruled out based on the history. An iatrogenic aetiology cannot be ruled out as pericardiocentesis was performed prior to presentation at the KSVM, but this



**Figure 3:** Pericardial sac filled with pyogranulomatous infiltration. Note the severe proliferation of the mesothelial cells along the epicardium (arrow) and granulation tissue formation (arrow head) (H & E). ( $\times 400$ )



**Figure 4:** Abscess wall formation (newly formed collagen connective tissue) with central accumulation of neutrophils, macrophages and cell debris (H & E). ( $\times 400$ )

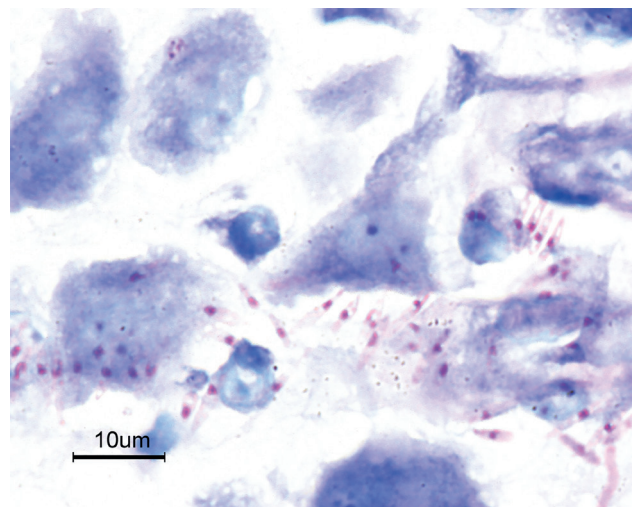
is considered unlikely as pericardiocentesis was performed one week after the onset of clinical signs, and the abscess was present already visualized at the first ultrasound examination performed at the KSVM.

Pneumonia, which may cause empyema in humans, is unlikely to be the primary process as there was no evidence for its presence either clinically or on gross post mortem and histopathological examination.

The location of the abscess on the heart-base supports oesophageal perforation as a probable cause. At post mortem examination the thoracic cavity was thoroughly searched but no foreign body could be found. The oesophagus, trachea and bronchi were all carefully examined but evidence consistent with perforation of these structures could not be found. The absence of oesophageal pathology is likely due to the healing of the oesophageal wall in the three weeks between the suspected oesophageal perforation and the time of post mortem. The duration of the disease is reflected in the chronic, severe pyogranulomatous pleuritis with abscess formation, and the chronic pericarditis and myocarditis.

In some cases it is difficult to distinguish between a highly proliferated mesothelium during a severe inflammation and a neoplasia (mesothelioma). Thus, a complicated mesothelioma may also be considered as a possible aetiology. Complicated mesothelioma was considered to be an unlikely aetiology as changes consistent with this diagnosis were confined to a small area of the pleura.

Medical and/or surgical treatment of canine and feline



**Figure 5:** Uniform colony of rod shaped bacteria in-between cellular debris from the heart base abscess (Giemsa stain) subsequently confirmed on culture to be *Prevotella oralis*. ( $\times 1000$ )

pyothorax have been proposed. Surgery is indicated in cases where mediastinal or pulmonary masses are identified or in cases where complications arise from the placement of thoracostomy tubes (11, 15). The success-rate of medical management as the sole means of treatment has been reported to be between 56-100% (7, 15, 16, 17, 18). However, when surgical and medical treatments were compared, 78% of the surgically treated cases and 25% of the medically treated cases were disease-free after one year (6).

Exploration of the pleural cavity was undertaken via a median sternotomy as the nature and the extent of the process was unknown. This approach proved to be difficult and time consuming due to the highly vascular and proliferative nature of the mediastinum and the extent of the adhesions between the lungs and the pericardium.

Preoperative CT may have been useful in this case to further define the location of the lesion with a resultant possible change in surgical approach. A left intercostal thoracotomy may have provided better access to the abscess at the heart base and would have obviated the need to resect the highly vascular mediastinum. A shorter less invasive approach would have decreased the surgical time and may have altered the outcome of this case.

## REFERENCES

1. Even, H., Rohde, J., Verspohl, J., Ryll, M. and Amtsberg, G.: Investigations into the occurrence and the antibiotic susceptibility of gram negative anaerobes of the genera *Bacteroides*, *Prevotella*, *Porphyromonas* and *Fusobacterium* in specimens obtained from diseased animals. *Berl. Munch. Tierarztl. Wochenschr.* 111: 379-386, 1998.
2. Allaker, R.P., Young, K.A., Langlois, T., De Rosayro, R. and Hardie J.M.: Dental plaque flora of the dog with reference to fastidious and anaerobic bacteria associated with bites. *J. Vet. Dent.* 14:127-130, 1997.
3. Allaker, R.P., De Rosayro, R., Young, K.A. and Hardie J.M.: Prevalence of the *Porphyromonas* and *Prevotella* species in the dental plaque of dogs. *Vet. Rec.* 140:147-148, 1997.
4. Talan, D.A., Citron, D.M., Abrahamian, F.M., Moran, G.J. and Goldstein, E.J.: Bacteriologic analysis of infected dog and cats bites. *New Engl. J. Med.* 340:138-140, 1999.
5. Schindl, A. and Schon, H.: Foot infection with *Prevotella bivia*, *P. oralis* and *P. loescheii* after wound licking. *J. Med. Microbiol.* 48:109, 1999.
6. Rooney, M.B. and Monnet, E.: Medical and surgical treatment of pyothorax in dogs: 26 cases (1991-2001). *J. Am. Vet. Med. Assoc.* 221:86-92, 2002
7. Walker, A.L., Jang, S.S. and Hirsh, D.C.: Bacteria associated with pyothorax of dogs and cats: 98 cases (1989-1998). *J. Am. Vet. Med. Assoc.* 216:359-363, 2000.
8. Homma, K. and Schoster, J.V.: Anaerobic orbital abscess/cellulites in a Yorkshire Terrier dog. *J. Vet. Med. Sci.* 62:1105-110, 2000.
9. Allan, R., Fenwick, S.G., Clark, P. and Cave, N.: Meningitis in a dog caused by *Prevotella oralis*. *J. Small Anim. Pract.* 45:421-423, 2004.
10. Nelson, A.W. and Monnet, E.: Lungs. In: D. Slatter (Ed): *Textbook of small animal surgery*. 3<sup>rd</sup> ed. Saunders, Philadelphia, PA, USA. Pp. 880-889, 2003.
11. Demetriou, J.L., Foale, R.D., Ladlow, J., McGrotty, Y., Faulkner, J. and Kirby, B. M.: Canine and feline pyothorax: a retrospective study of 50 cases in the UK and Ireland. *J. Small Anim. Pract.* 43:388-394, 2002.
12. Seiler, G., Rytz, U. and Gaschen, L.: Radiographic diagnosis – cavitary mediastinal abscess. *Vet. Radiol. Ultrasound.* 42:431-433, 2001.
13. Sivacolundhu, R. K., O'Hara, A. J. and Read, R. A.: Thoracic actinomycosis (arcanobacteriosis) or nocardiosis causing thoracic pyogranuloma formation in three dogs. *Aust. Vet. J.* 79:398-402, 2001.
14. Schmidt, M. and Wolvekamp, P.: Radiographic findings in 10 dogs with thoracic actinomycosis. *Aust. Vet. J.* 79:398-402, 2001.
15. Johnson, M.S. and Martin, M.W.S.: Successful medical treatment of 15 dogs with pyothorax. *J. Small Anim. Pract.* 48:12-16, 2007.
16. Robertson, S.A., Stoddart, M.E. and Evans, R.J.: Thoracic empyema in the dog: a report of twenty two cases. *J. Small Anim. Pract.* 24:103-119, 1983.
17. Turner, W.D. and Breznock, E.M.: Continuous suction drainage for management of canine pyothorax – a retrospective study. *J. Am. Anim. Hosp. Assoc.* 24: 485-494, 1988.
18. Piek, C.J. and Robben, J.H.: Pyothorax in nine dogs. *Vet. Q.* 22: 107-111, 2000.