

The Pathology of *Macrorhabdus ornithogaster* and *Eimeria dunsingi* (Farr, 1960) Infections in Budgerigars (*Melopsittacus undulatus*)

Ozmen, O.,^{1*} Aydogan, A.,¹ Haligur, M.,¹ Adanir, R.,² Kose, O.² and Sahinduran, S.³

¹ University of Mehmet Akif Ersoy, Faculty of Veterinary Medicine, Department of Pathology, Istiklal Yerleskesi , 15030, Burdur, Turkey,

² University of Mehmet Akif Ersoy, Faculty of Veterinary Medicine, Department of Parasitology, Istiklal Yerleskesi, 15030, Burdur, Turkey.

³ University of Mehmet Akif Ersoy, Faculty of Veterinary Medicine, Department of Internal Medicine, Istiklal Yerleskesi, 15030, Burdur, Turkey.

*Corresponding Author: Dr.Ozlem Ozmen, University of Mehmet Akif Ersoy, Faculty of Veterinary Medicine Department of Pathology, Istiklal Yerleskesi, 15030, Burdur, Turkey, Tel: +90 248 2132170. Email: ozlemozmen@mehmetakif.edu.tr.

ABSTRACT

The aim of this study was to describe the pathological findings in budgerigars simultaneously infected under field conditions with coccidiosis and megabacteriosis. Severe diarrhea and vomiting were observed in a budgerigar flock. Affected birds showed inappetence and loss of condition, with a flock mortality rate of 30%. At necropsy, the proventriculi and ventriculi were swollen and hyperemic, and viscous mucus and blood adhered to the mucosa. Cytological examination of Giemsa stained proventricular and ventricular tissue revealed clusters of yeast. Microscopically, mild to severe inflammatory reactions, ulcers and hemorrhage were observed in the proventriculi. Numerous large, rod shaped *Macrorhabdus ornithogaster* organisms had colonized the proventriculi, ventriculi and gut. The bright pink organism was easily detected in periodic acid Schiff stained sections. On microscopic examination of the feces, numerous *Eimeria* oocysts were observed. Histopathological examination of the gut revealed numerous coccidial organisms in epithelial cells. *Eimeria dunsingi* (Farr, 1960) was identified in the gut contents of the birds, based on morphological characteristics. Surviving birds were treated with amphotericin-B for megabacteriosis and with toltrazuril for coccidiosis, after which the mortalities ceased. These results demonstrated that simultaneous natural infections under field conditions can cause severe, gross histopathological lesions and high rates of mortality in birds. At the same time, this is the first report of *M. ornithogaster* infection in budgerigars in Turkey.

Keywords: *Macrorhabdus ornithogaster*, *Eimeria dunsingi* (Farr, 1960), megabacteriosis, budgerigar, pathology, coccidiosis, treatment.

INTRODUCTION

Macrorhabdus ornithogaster was previously referred to as Megabacteria and was once considered to be a bacterium, however, research has confirmed that it is a yeast organism containing a eukaryotic nucleus (1). *M. ornithogaster* colonizes the proventriculi and ventriculi of birds (2). This organism causes a chronic wasting disease, characterized by emaciation, weakness, high rates of morbidity and low rates

of mortality, and has been described in canaries and budgerigars. Vomiting of slimy material due to acute hemorrhagic gastritis occurs in advanced stages of the disease in budgerigars (3, 4). The known host range of the organism includes several species of poultry, other captive bird species belonging to several orders, including psittacine and passerine cage and aviary birds, and some free-living bird species (5).

M. ornithogaster is an anamorphic ascomycetous yeast

that is the only known member of its genus (6). The organism is relatively large (20-70 μm long and 1-5 μm wide), rod-shaped to filamentous, and stains positive with Gram and periodic acid-Schiff (PAS) stains (7). Hematoxylin and eosin staining reveals a histological appearance of the organism in infected birds of a typical "haystack" appearance in situ.

Coccidiosis is a disease that infects all avian species, including psittacine birds. The disease can cause hemorrhagic diarrhea, depression, emaciation, weight loss and sometimes death (8-11). Coccidial infections in psittacine birds may be asymptomatic or associated with diarrheal syndromes (sometimes with blood in the droppings), emaciation, general ill health, and systemic disease (8). Coccidial species causing infections in aviary birds include *Eimeria dunsingi* (Farr, 1960), *E. haematodi*, *Isospora psittaculæ*, *I. serini* and *I. lacazei* (12-14).

M. ornithogaster has a worldwide distribution and a wide range of host birds, including psittacines, passerines, ratites and poultry species (15). There has been one report on *M. ornithogaster* in laying hens, (16) however, there have been no reports concerning *M. ornithogaster* infection in budgerigars in Turkey. Coccidiosis is a protozoan disease and can cause high mortality in all avian species (17). Budgerigar breeding is rapidly becoming more popular in Turkey and the knowledge about diseases of this species is drawing attention. Both megabacteriosis and coccidiosis are common diseases in budgerigars but there have been no reports on pathological findings in natural and simultaneous infections.

The aim of this study was to describe the pathological findings in simultaneous infections with *M. ornithogaster* and *E. dunsingi* (Farr, 1960) in budgerigars, as well as the treatment and prophylaxis of these diseases. This is the first report of dual infection in budgerigar in Turkey.

MATERIALS AND METHODS

Deaths occurred in a colony of birds that were transported from a hatchery 650 km away from the aviary. Seventy-five birds in the flock of about 250 budgerigars died, and 38 of these were presented to the Department of Pathology University of Mehmet Akif Ersoy, for diagnosis during the preceding three days. Eighteen of the 38 birds were infected with both megabacteria and coccidial organisms. Severe hemorrhagic diarrhea, depression and death were

the most common clinical symptoms. Feces usually adhered around the anus (Figure 1). At necropsy, hemorrhages at the proventriculus and gut were observed in birds. Coccidiosis was diagnosed in 12 birds while eight birds were diagnosed with megabacteriosis alone. Direct microscopy of fresh impression smears of ventricular or proventricular mucosa was prepared on glass slides, unstained and Giemsa stained preparations were examined microscopically to diagnose *M. ornithogaster* infection. All fecal impression smears without staining were examined for any microorganism and then Fulleborn's flotation method used for initial diagnosis of coccidiosis. A 2.5% solution of potassium dichromate was added to feces containing the oocysts and homogenized. The mixture was filtered and stored in a petri dish at room temperature for sporulation. Identification of oocysts was based on their morphological characteristics (9, 11, 17).

For histopathological examination, tissues were fixed in 10% buffered formalin, processed routinely and stained with hematoxylin and eosin (H&E). Samples from proventriculi, ventriculi, and the gut were also stained with PAS to identify *M. ornithogaster*.

The severity of gut lesions was assessed by scoring hemorrhages and inflammatory reactions in birds with single or dual infections. Each criterion was graded on a scale of 0 to 4 as follows: 0= no lesion, 1= focal slight, 2= focal severe, 3= diffuse slight and 4= diffuse severe. Data from each animal was analyzed statistically. One-way analysis of variance was used to detect any differences between the single and dual infection groups. The non-parametric Duncan multiple com-



Figure 1: Feces around the anus, diarrhea in three budgerigars which died from combined infection coccidiosis and megabacteriosis.

parison method was used to assess the statistical significance of differences. Statistical analyses were performed using the SPSS 13.0 program (SPSS Inc., Chicago, IL). A P value < 0.05 was considered as statistically significant.

Surviving birds were treated with amphotericin-B (Fungizone, Bristol-Myers Squibb Inc, Istanbul-Turkey) and toltrazuril (Baycox, Bayer- Istanbul-Turkey). Amphotericin-B was administered twice a day (0.15-0.30 mL/bird) over 30 days to treat megabacteriosis, and toltrazuril (1.5 mL per liter of drinking water) was administered 3 days to treat coccidiosis. In addition, 0.1% apple vinegar (Baktat Elma Sirkesi- Bursa- Turkey) in the drinking water was administered during 10 days with one-week intervals three times, totally 30 days.

RESULTS

At necropsy, atrophy of the pectoral muscle was most commonly observed in dead birds affected by megabacteriosis. Thickening of the proventricular and ventricular walls, covering of the proventricular mucosa by thick white mucus, ulceration and hemorrhage of the proventricular and ventricular mucosa, loosening of the koilin layer and hemorrhage into the lumen of these organs were commonly observed (Figure 2). In addition marked hemorrhage in the small intestinal wall and into the lumen were also observed. The most severe histopathological lesions were seen in the proventriculus and, in some cases the ventriculus, including penetration of organisms into the lumen of the superficial proventricular crypts and occasionally to deep-

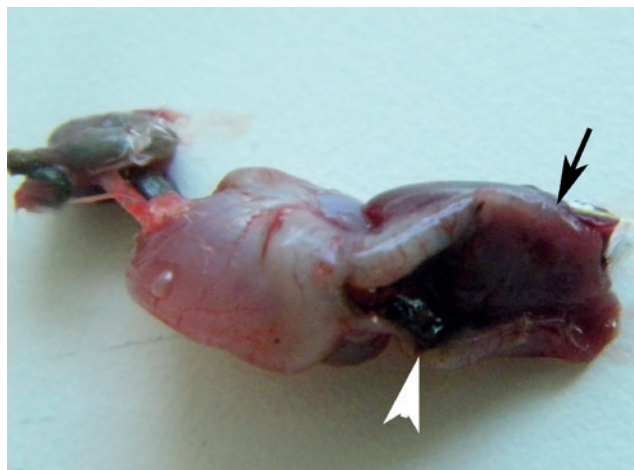

Figure 2: Thickening of the proventricular walls (arrow) and hemorrhage of the proventricular mucosa (arrow head).

er parts of the glands. Inflammatory reactions were also noted. On microscopic examination of impression smears, long, rod-shaped organisms were observed even at $\times 40$ magnification. These microorganisms were filamentous and non-branching. The morphology, staining characteristics, and tissue localization of the microorganisms were consistent with previous descriptions of *M. ornithogaster*. Organisms close to and infiltrating the epithelium were in parallel aggregations, whereas their orientation in the mucin layer was less organized. The characteristics of the disease and the shape of the organisms in the ulcerated gastric mucosa suggested a diagnosis of *M. ornithogaster* infection.

At necropsy of the birds that suffered from coccidiosis, small hemorrhagic areas and blood were observed in the small intestine (Figure 3). On microscopic examination of the gut contents of these birds, numerous *Eimeria* oocysts were seen. Histopathology of the guts of these birds revealed numerous *Eimeria* organisms, with desquamation and inflammation of the gut wall.

The owner stated that after transport of the birds from the hatchery to the aviary the budgerigars gradually became emaciated and mortality increased. Birds presented with diarrhea and accumulation of dried feces around the cloaca, which in some individuals formed a packed obstruction or plug. At necropsy of the dead birds, atrophy of the pectoral muscles was observed, with hemorrhage of the proventricular mucosa adjoining the transition to the gizzard. Blood was also seen in the intestinal lumen. Examination of impression smear without staining of the gut contents revealed numer-



Figure 3: Hemorrhagic areas in gut in a budgerigar, died from combined infection.

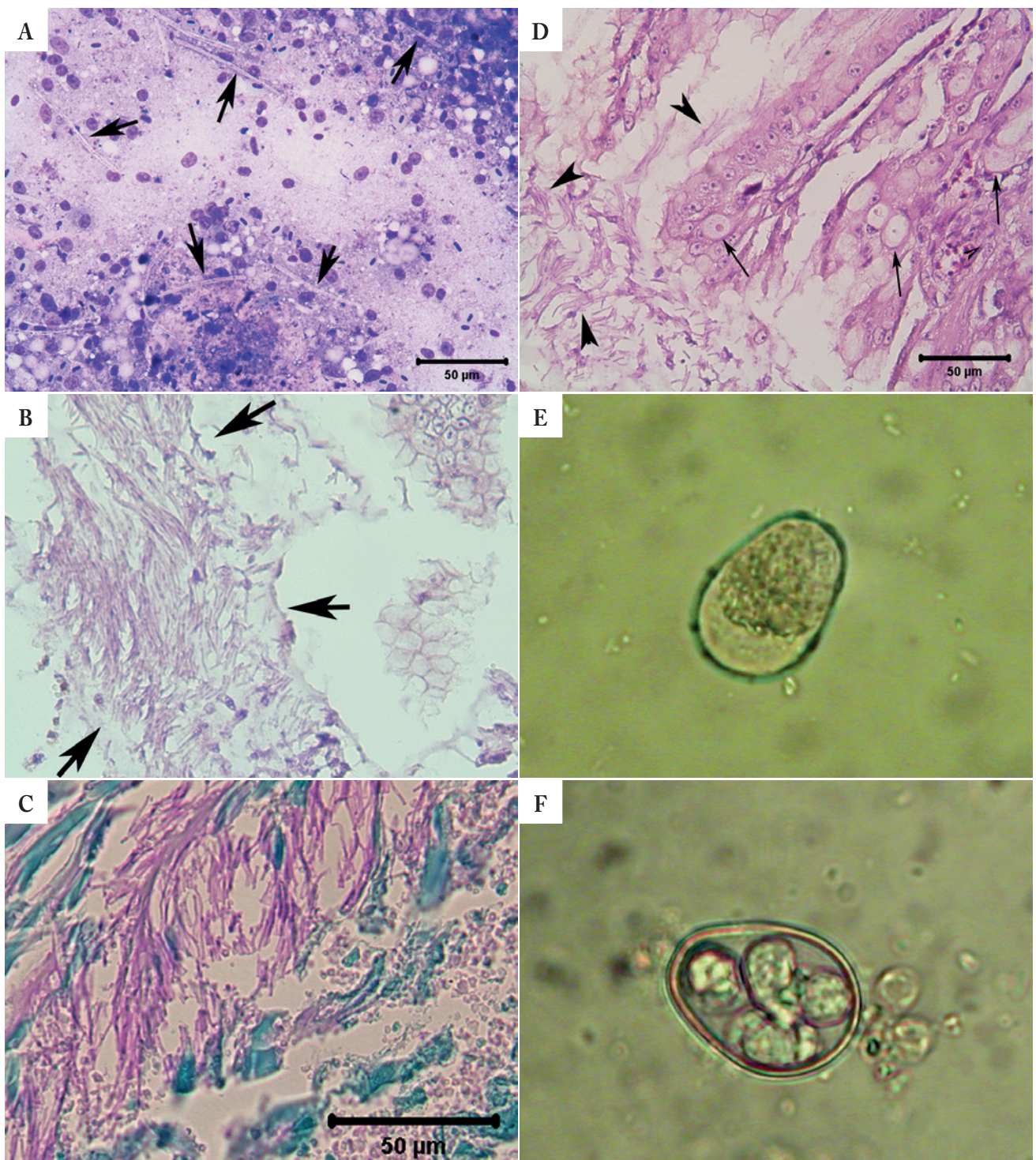


Figure 4: A: Numerous *M. ornithogaster* organisms (arrows) in Giemsa stained proventricular tissue from a budgerigar. B: Clusters of *M. ornithogaster* (arrows) in the lumen of the proventriculus. Hematoxylin and eosin stain. C: *M. ornithogaster* organisms show brilliant pink coloration on periodic acid-Schiff stained sections. D: Simultaneous identification of *M. ornithogaster* (arrow heads) and *E. dunsingi* (Farr, 1960) organisms (arrows) in a budgerigar gut. Hematoxylin and eosin stain. E: An *E. dunsingi* (Farr, 1960) oocyst as observed on microscopic examination of feces. F: Sporulated oocyst of *E. dunsingi* (Farr, 1960).

ous coccidial organisms, together with very large rod-shaped organisms. These organisms were also observed on Giemsa stained impression smears (Fig. 4A).

In 18 birds, *M. ornithogaster* organisms were observed in the proventriculus, ventriculus and gut, together with coccidial organisms in the small intestine. At necropsy of these birds both proventricular-ventricular and gut lesions, as well as inflammation were observed. Younger birds, especially, died from the diseases, and death usually occurred suddenly in simultaneously affected birds. Atrophy of the pectoral muscle was not severe in these cases. Microscopic examination revealed more severe hemorrhage and infiltrations in birds with dual infections and this was statistically significant ($p < 0.01$) (Table 1). On histopathological examination of the mucosa of the gizzard, massive clumps of rod shaped organisms attached to the epithelium were visualized (Figures 4B, 4C), and these clumps were observed throughout the proventriculus, ventriculus and gut. In some of the birds, the organisms penetrated deeply between mucosal folds and were occasionally detected in submucosal glands (Figure 4D). Numerous coccidial organisms were observed in the epithelial cells of the gut. Inflammatory reactions were observed in almost all organs of the gastrointestinal tract.

Oocysts collected from infected birds sporulated within one week when stored at room temperature. The oocysts were distinctly ovoid and colorless to pale blue. They measured 25 to 35 μm (mean 29.91 μm , SD 3.34 μm) \times 22.5 to 27.5 μm (mean 24.37 μm , SD 1.88 μm). The oocysts lacked a collar, micropyle and polar cap but possessed a single eccentrically located polar granule (Figure 4E). The oocysts were bound by a smooth bilayered wall. The outer layer was colorless or light brown and the inner layer was colorless or blue. Sporulated oocysts contained four ovoid to pyriform sporocysts measuring 12.5 to 15 μm \times 7.5 to 10 μm in diameter (Figure 4F). The sporocysts contained a prominent anterior steida body and a large posterior residuum consisting of numerous granules in a compact mass. The sporocysts contained two elongate sporozoites arranged head-to-tail. The sporozoite nuclei were located centrally next to a single large refractile granule. Based on these morphological data, only one *Eimeria* spp. had infected the birds and this was the highly pathogenic *Eimeria dunsingi* (Farr, 1960). The other visceral organs were normal in appearance. There was no mortality after treatment of the flock.

Table 1: Statistical analysis and mortality in birds with single or dual infections.

Groups	n	Mortality rate (%)	Hemorrhage	Infiltration
Coc+ Mega	18	47	2.72 \pm 1.01 ^a	2.94 \pm 0.80 ^a
Coc	12	32	1.91 \pm 0.90 ^b	2.25 \pm 0.96 ^b
Mega	8	21	1.50 \pm 0.75 ^b	1.62 \pm 0.51 ^b
P value			<0.01*	<0.01*

Coc: Coccidiosis, Mega: megabacteriosis,

*Differences between mean values for groups, as indicated by different letters in the same column, are statistically significant ($P < 0.01$).

DISCUSSION

M. ornithogaster “megabacteriosis” has been diagnosed in many species and results in a varied spectrum of clinical symptoms and pathologies. In some species (chickens, turkeys, guinea fowls) the disease has been characterized clinically by emaciation, prostration, loss of appetite, cachexia and death, with a typically chronic course. A more acute disease was observed in finches and budgerigars (18). In budgerigars in this study suffering from megabacteriosis the symptoms included emaciation, diarrhea, and hemorrhage of the proventriculus. The presence of characteristic large, rod-shaped organisms supported the diagnosis (19-21).

Coccidiosis is a common disease in budgerigars and can result in death. In this study, megabacteriosis and coccidiosis were found to occur concurrently. Clinical signs and pathological findings related to the gastrointestinal system, and mortality was 30%. Diarrhea was more frequent than vomiting, and coccidiosis lesions were more marked than megabacteriosis lesions.

Postmortem findings included proventriculitis and proventricular dilatation. Gram-positive, PAS-positive, acidophilic (on Giemsa staining), rod-shaped bacteria were identified histologically, especially in the area between the proventriculus and the ventriculus. A diagnosis may be made by cytological demonstration of organisms in proventricular washings (22). In the present study, the diagnosis was made by cytological and histological confirmation of megabacteriosis, and by histological and parasitological confirmation of coccidiosis. PAS staining was performed to support the diagnosis of megabacteriosis. The clinical and pathological findings were in agreement with previous studies however due to the coccidiosis co-infection the pathology was more severe and mortality was higher.

Eimeria dunsingi (Farr, 1960) is a highly pathogenic

Eimeria species found in parrots and budgerigars. This organism localizes in the anterior part of the gut and is common throughout the world. The endogenous developmental stages generally localize in villus epithelium, distal to the nucleus (14). The findings from this study were in agreement with previous studies on the localization and morphology of this organism. Because of the pathogenicity of the organism, the coccidiosis lesions were more severe than those due to megabacteriosis.

Experimental infections with pure cultures of megabacterium induce disease only in English standard budgerigars and not in the common breed. These findings suggest that birds vary in their susceptibility to the organism, and other factors are involved in the pathogenesis. Spontaneous recovery was common in experimental cases (23). This present study showed that simultaneous infection with *M. ornithogaster* and *E. dunsingi* (Farr, 1960) can increase the severity and rate of mortality of the disease in budgerigars. The study also indicated that when mortality in budgerigars is high, the possibility of a coinfection should be taken into consideration.

Domestic animals are invariably transported for a variety of reasons, and it can cause potential stress. Transport stress may increase the animals' susceptibility to diseases (24) and increase the mortality rate (25). Birds are very sensitive to change, so moving can be particularly stressful for them (13). Transportation was considered to be a predisposing factor in the occurrence of disease outbreaks in birds in this study as there were no clinical problems observed in the hatchery and in the remaining birds. The outbreak only occurred after transportation.

The prevalence of *M. ornithogaster* infection is highest in captive-bred budgerigars, parrotlets and canaries, and the disease occurs in these birds throughout the world (19, 26, 27). To the best knowledge of the authors this is the first report of megabacteriosis in budgerigars in Turkey. Owners do not generally seek veterinary or laboratory assistance and professionals may not be aware of the occurrence of exotic bird diseases in this country, which may explain the absence of previous reports. This study showed that *M. ornithogaster* infection may have been a problem in budgerigars.

Because the pathogenic organism is a yeast, birds with megabacteriosis show very poor responses to antibiotics, and antifungal drugs are most commonly recommended (27-29). The present study confirmed the benefit of treat-

ment with amphotericin-B in budgerigars with megabacteriosis. Megabacteriosis causes an increase in the pH of the proventricular mucus from 2.7 to 7.0-7.3 (39, 30). Because megabacteria thrive in an alkaline environment, an alternative treatment strategy is to increase the acidity of the proventricular fluid by oral administration of apple vinegar or grapefruit juice (13). We also found that 0.01% apple vinegar in drinking water was effective for prophylaxis. This study also confirmed that toltrazuril is an effective treatment for coccidiosis. The present results showed that co-infection can cause severe lesions and increased mortality in budgerigars. Practitioners should consider simultaneous infection in budgerigars, especially in disease outbreaks with high mortality, and when there is no response to treatment. Prophylactic measures against megabacteriosis, such as administration of apple vinegar, may be advisable before birds are transported or experience other types of stress.

REFERENCES

1. Moore, R.P., Snowden, K.F. and Phalen, D.N.: A method preventing transmission of so-called "megabacteria" in budgerigars (*Melopsittacus undulates*). *J. Avian Med. Surg.* 15: 283-287, 2001.
2. Phalen, D.: Diagnosis and management of *Macrorhabdus ornithogaster* (formerly megabacteria). *Vet. Clin. North Am. Exotic Anim. Pract.* 8: 299-306, 2005.
3. Schweighardt, H. and Pechan, P. and Lauermaun, E.: Emaciation and vomiting as signs of a specific fungal proventriculitis in budgerigars and canaries. *Kleintierpraxis.* 9: 439-442, 1984.
4. Uyttbroek, E. and Ducatelle, R.: Megabacterium proventriculitis, a disease of cage birds. *Vlaams. Diergen. Tijdst.* 59: 147-150, 1990.
5. Gerlach, H.: Megabacteriosis. *Semin. Avian Exotic Pet Med.* 10: 12-19, 2001.
6. Tomaszewski, E.K., Logan, K.S., Snowden, K.F., Kurtzman, C.P. and Phalen, D.N.: Phylogenetic analysis identifies the 'megabacterium' of birds as a novel anamorphic ascomycetous yeast, *Macrorhabdus ornithogaster* gen. nov., sp. nov. *Int. J. Syst. Evol. Micr.* 53: 1201-1205, 2003.
7. Campbell, T.W. and Ellis, C.K.: Comparative Cytology. In: Campbell, T.W. and Ellis, C.K. (Eds.): *Avian and Exotic Animal Hematology and Cytology.* Blackwell Publishing, Iowa, pp.139-217, 2007.
8. Hiepe, T. and Jungman, R.: *Lehrbuch der Parasitologie, Band 2, Veterinärmedizinische Protozoologie,* Gustav Fischer Verlag New York, Stuttgart, pp.63-133, 1983.
9. Levine, N.D. and Ivens, V.: *The Coccidian Parasites [Protozoa, Apicomplexa] of Artiodactyla.* Illinois Bio. Monogr. 55, Illinois Univ. Pres, Chicago, pp.141-155, 1986.
10. Mimioglu, M., Goksu, K. and Sayin, F.: *Veteriner ve Tibbi Protozooloji II,* Ankara Universitesi Basimevi, Ankara, pp. 607-684, 1969.

11. Ministry of Agriculture, Fisheries and Food (MAFF) Manual of Veterinary Parasitological Laboratory Techniques. References Book, London, pp. 607-684, 1986.
12. Black, S.S., Steinohrt, L.A., Bertucci, L.B., Rogers, L.B. and Didier, E.S.: Encephalitozoon hellem in Budgerigars (*Melopsittacus undulatus*). Vet. Pathol. 34: 189-198, 1997.
13. Grainer, C.G. and Ritchie, B.W.: Avian Medicine: Principles and Application, 1st ed., Wingers Publishing Inc, Florida, 1994.
14. Inci, A.: Hindi, Kaz, Ördek ve Kuşlarda Coccidiosis. In: Dincer S,(Ed.) Coccidiosis, Türkiye Parazitol. Dern. Yayın No: 17, Izmir. 193-208, 2001.
15. Phalen, D.N. and Moore, R.P.: Experimental infection of whitel-eghorn cockerels with *Macrorhabdus ornithogaster* (Megabacterium). Avian Dis. 47: 254-260, 2003.
16. Mutlu, O.F., Seckin, S., Ravelhofer, K., Hildebrand, R.A. and Grimm, F.: Proventriculitis in domestic fowl (*Gallus gallus* var. dom. L., 1758) caused by megabacteria. Tierarzt. Praxis. 25: 460-462, 1997.
17. Levine, N.D.: Veterinary Protozoology, 1st ed. Iowa State University Press, Ames, Iowa, 1985.
18. Martins, N.R.S., Horta, A.C., Siqueira, A.M., Lopes, S.Q., Resende, J.S., Jorge, M.A., Assis, R.A., Martins, N.E., Fernandes, A.A., Barrios, P.R., Costa, T.J.R. and Guimaraes, L.M.C.: *Macrorhabdus ornithogaster* in ostrich, rhea, canary, zebra finch, free range chicken, turkey, guinea-fowl, columbina pigeon, toucan, chuckar partridge and experimental infection in chicken, japane- se quail and mice. Arq. Bras. Med. Vet. Zoo. 58: 291-298, 2006.
19. Baker, J.R.: Megabacteriosis in exhibition budgerigars. Vet. Rec. 131: 12-14, 1992.
20. Rosskopf, W.J.: Megabacterial Proventriculitis. In: Diseases of Cage and Aviary Birds, Rosskopf WJ, Woerpel RW (Eds.), 3rd ed., Williams and Wilkins, Baltimore, p.442. 1996.
21. Scanlan, C.M. and Graham, D.L.: Characterization of a Gram-positive bacterium from the proventriculus of budgerigars (*Melopsittacus undulatus*). Avian Dis. 34: 779-786, 1990.
22. Davis, W., Kenzy, S. and Stauber, E.H.: A preliminary study of thin bird disease. Processing EMSA Meeting, p. 602-603, 1981.
23. Gerlach, H.: Going light in budgerigars. Association Avian Veterinary Annual Conference Main Conference Proceedings. Miami, p.247-249, 1986.
24. Hansson, I., Ederoth, M., Andersson, L., Vagsholm, I. and Olsson Engvall E.: Transmission of *Campylobacter* spp. to chickens during transport to slaughter. J. Appl. Microbiol. 99:1149-1157, 2005.
25. Warriss, P. D., Pagazaurtundua, A. and Brown. S. N.: Relationship between maximum daily temperature and mortality of broiler chickens during transport and lairage. Br. Poult. Sci. 46: 647-651, 2005.
26. Dorrestein, G.M., Zwart, P. and Buitelaar, M.N.: Problems arising from disease during the periods of breeding and rearing canaries and other aviary birds. Tijdschr. Diegenee. 105: 535-543, 1980.
27. Fillippich, L.J., Boyle, D.A., Webb, R. and Fuerst, J.A.: Megabacteria in birds in Australia. Aust. Vet. Pract. 23: 71-76, 1993.
28. Kheirandish, R. and Salehi, M.: Megabacteriosis in budgerigars: diagnosis and treatment. Comp. Clin. Pathol. 20: 501-505, 2011.
29. Van Herck, H.T., Duijser, P., Zwart, G.M., Dorrestein, G.M., Buitelaar, M. and Van Der Hage, M.H.: A bacterial proventriculitis in canaries (*Serinus canaria*). Avian Pathol. 13: 561-572, 1984.
30. Werther, K., Schocken-Iturrino, R.P., Verona, C.E.S. and Barros, L.S.S.: Megabacteriosis occurrence in budgerigars, canaries and lovebirds in Ribeirao Preto region - Sao Paulo state - Brazil. Rev. Bras. Cienc. Avicola 2: 183-187, 2000.