

A Study of the Morphological Structure of the Syrinx of the Sparrowhawk (*Accipiter nisus*)

Ozudogru, Z.,¹ Balkaya, H.,^{1*} Kara, A.² and Ozdemir, D.¹

¹ Ataturk University, Faculty of Veterinary Medicine, Department of Anatomy, Erzurum, Turkey.

² Ataturk University, Faculty of Veterinary Medicine, Department of Histology, Erzurum, Turkey.

* **Corresponding Author:** Dr. Hulya Balkaya, Ataturk University, Faculty of Veterinary Medicine, Department of Anatomy, Erzurum, Turkey.
Tel: +90-442-2315532. E-mail: balkayaibrahim@hotmail.com

ABSTRACT

Sparrowhawks are commonly used for quail hunting in northeastern Turkey. Despite its importance in Turkey, there is a dearth of information concerning the anatomy of the syrinx in the sparrowhawk. The objective of this study was to assess the structure and morphological differences of the sparrowhawk's syrinx from those of other avian species. The syrinx, which is the main source for vocalization for birds is located on the caudal end of the trachea. To the best knowledge of the authors this is the first study of the syrinx of the Sparrowhawk. The syrinx of the sparrowhawk was found to be of the tracheobronchial type and consists of four tracheosyringeal cartilages and five bronchosyringeal cartilages. For the histological specimens, syrinx tissues were stained with Crossman modified triple stain for histological evaluation, Verhoeff's elastic fibers stain for elastic fiber density, and Alcian blue (pH: 2.5) and periodic acid Schiff (PAS) stain for mucopolysaccharide and neutral mucins, respectively. The pessulus of hyaline cartilage was found to be covered with pseudo-stratified epithelium. The medial labia and medial tympaniform membrane consisted of double-ply layers of epithelium, which consisted of collagen and elastic fiber layers. In addition, the bronchosyringeal muscle consisted of extrinsic muscles only. In conclusion, the results of this study may contribute to knowledge of morphologic and histologic structure and variations between bird species.

Keywords: Sparrowhawk; *Accipiter nisus*; Syrinx; Morphology; Vocalization

INTRODUCTION

Bird vocalization has an important role in distinguishing bird species. Birds are classified as passerine and non-passerine, according to structural differences of their vocal organs (1). The syrinx, known as the caudal larynx, is found in passerine birds (2-4). The syrinx lies between the trachea and primary bronchi at the level of the second and third thoracic vertebrae (5) and consists of three types of cartilage: tracheal, bronchial and tracheobronchial, according to their origin (6-8). The syrinx is the sound-producing organ, and it shows histological and anatomical differences according to bird species (9, 10). The syrinx creates a myoelastic-aerodynamic sound-source for birds. Aerodynamic energy is converted into acoustic

energy with the help of active and passive components. The longitudinally located labia are held in a preliminary position by syringeal muscles and creates a vibration when air passes through, playing a crucial role in producing sounds (11-13).

The syrinx consists of tympanum and tracheosyringeales in the shape of a "C" and bronchosyringeales consisting of half-rings of cartilage. The pessulus in the cavum syringes consists of a double-layer mucous membrane extending dorso-ventrally from the primary bronchus' median wall. Syringeal muscles consist of two muscle structures: tracheolateral and sternotracheal (14). However, histologic differences in the syrinx mucosa's epithelium are present in avian species and this epithelium consists of double-layer,

squamous (15), columnar (16) and ciliated pseudostratified columnar epithelium (10).

Quail hunting with sparrowhawks is a traditional sport in northeastern Turkey and despite its importance, there is a dearth of information concerning the anatomy of the syrinx in the sparrowhawk. The current study was aimed to investigate macroanatomical and histological structure of the sparrowhawk's (*Accipiter nisus*) syrinx. Structures detected in this study included cartilage tissue and the distribution of collagen and elastic fibers in the syrinx in addition to the epithelial tissue covering its surface.

MATERIAL AND METHODS

Nine untreatable predatory sparrowhawks (*Accipiter nisus*) whose wings or legs were broken were received from the animal hospital at Ataturk University, Faculty of Veterinary Medicine, Erzurum-Turkey between the years of 2011–2013. Their weights ranged from 150 to 250 g. The sparrowhawks were euthanized under ether anesthesia and syrinx tissues were removed 3 mm cranial of tracheal bifurcation.

Syrinx tissues were fixed in neutral buffered 10% formalin fixative for 4 days. The fixed tissues were dehydrated in a graded series of ethanol and embedded in paraffin. Paraffin-embedded tissues were serially sectioned with 5 μ m thickness. The sections were stained with Crossman modified Mallory's triple stain for histological examination. In addition, Verhoeff's elastic fibers stain was used to determine elastic-fiber density, and Alcian blue (pH 2.5) and Periodic acid Schiff (PAS) stains were used to determine density of neutral and mucopolysaccharide goblet cells in the syrinx. Histological micrographs were taken by high-power light microscope (Nikon Eclipse i50, Japan).

RESULTS

The syrinx was observed to be situated at the level of the heart, at the level of the 14th cervical and 1st to 2nd thoracic vertebrae. It was formed as a result of modification of the

trachea's terminal section and the beginning of the primary bronchi (Figure 1A). In addition, the dorsal syrinx was connected to the medial bronchial lumen beginning at the pessulus, progressing ventrally and continuing to the medial labia (ML), the sides of which were covered with epithelium and the medial tympaniform membrane (MTM), both sides of which, in turn, were covered with epithelium. At the medial lumen, muscle fibers were connected to cartilagenous rings. Also, it was observed that these muscle fibers were connected to the ML and extending to the bronchial lumen on the ventral side of syrinx (Figure 1). No goblet cells were observed in MTM and ML epithelial tissue as judged by PAS and Alcian blue (pH: 2.5) staining.

The pessulus was observed as a hyaline cartilage dividing the bronchial lumen into two parts dorsally and covered with loose connective tissue (Figure 1B). The lamina propria consisted of loose thin connective tissue and its epithelial tissue had a ciliated pseudostratified columnar or respiratory epithelium. As a result of PAS and Alcian blue staining, PAS-positive goblet cells in small quantities were seen in the pseudostratified columnar epithelial (Figure 1C).

Medial labia and medial tympaniform membrane: While collagen fibers in the ML between two the epithelia and in the MTM were observed as being vertically placed, it was also observed that they formed a double-ply form [superficial layer (SL) and deep layer (DL)]. It was observed that collagen-fiber density increased throughout the bronchial lumen (Figure 2).

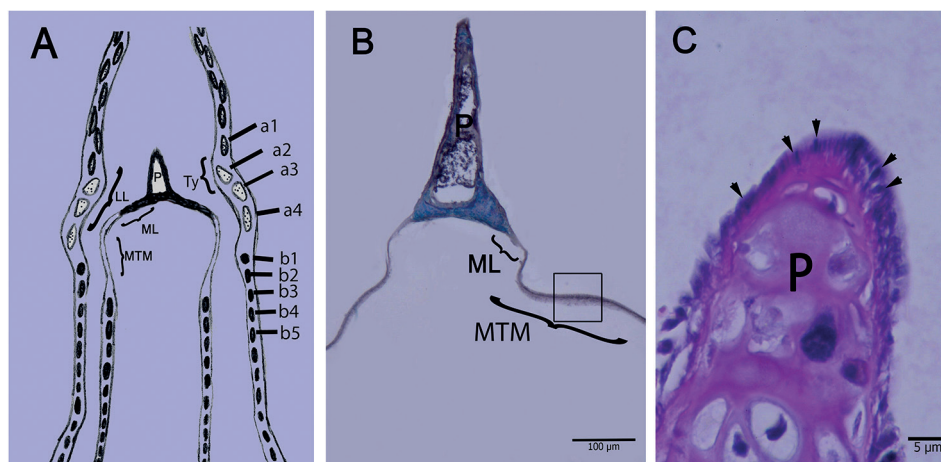


Figure 1: Micrographs of sparrowhawk syrinx, **A:** View of longitudinal drawing, **B:** Pessulus, medial labia and medial tympanium membrane, **C:** Epithelium of pessulus, PAS staining. **a1-a4:** Cartilages of tracheosyringeal rings, **a2-a4:** Tympanum rings, **b1-b5:** Cartilages of bronchosyringeal rings, **ML:** Medial labia, **MTM:** Medial tympanium membrane, **Ty:** Tympanum, **P:** Pessulus, **Arrow head:** Goblet cells in the epithelium of pessulus.

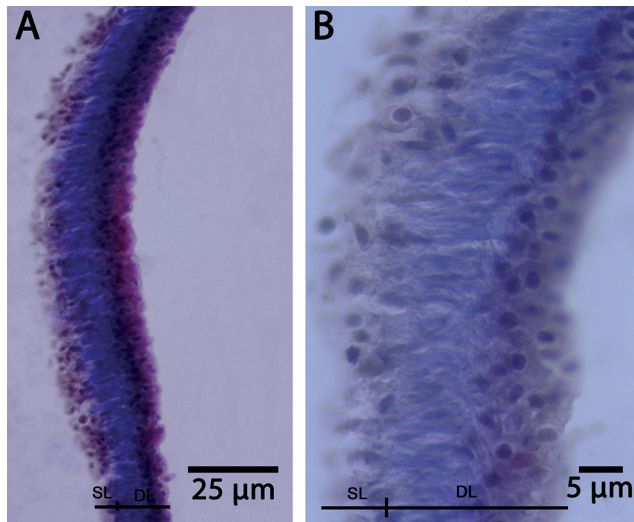


Figure 2: Micrograph of syrinx medial labia for collagen fibers, **A and B:** Collagen fiber of medial labia, **SL:** Superficial layer, **DL:** Deep layer, Crossman modified triple staining.

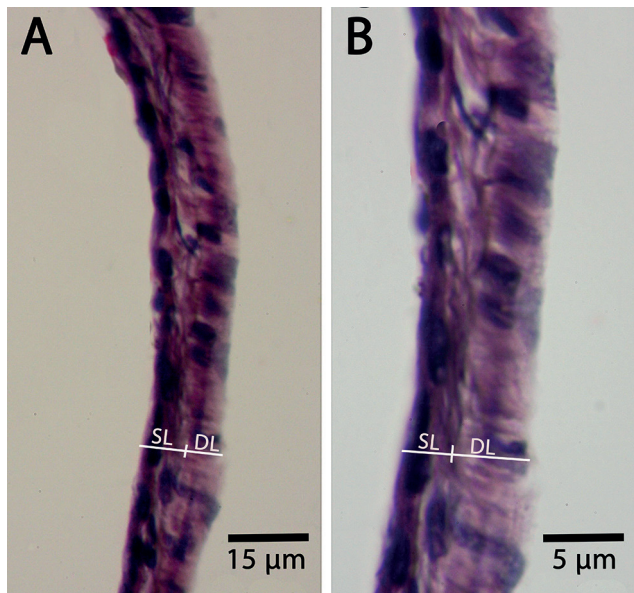


Figure 3: Micrograph of syrinx medial labia for elastic fibers, **A and B:** Elastic fiber of medial labia, **SL:** Superficial layer, **DL:** Deep layer, Verhoeff's elastic fibers staining.

While the dorso-ventrally placed collagen fibers were encountered in the superficial layer, both cranio-caudal and dorso-ventrally placed collagen fibers were encountered in the deeper layer. Elastic fibers were seen to be located the epithelial tissues of the ML and MTM sections. It was also observed that elastic fiber density increased toward the interclavicular air-sac section and that elastic fibers were situated between sub-epithelial tissues. While these fibers showed a cranio-caudal placement,

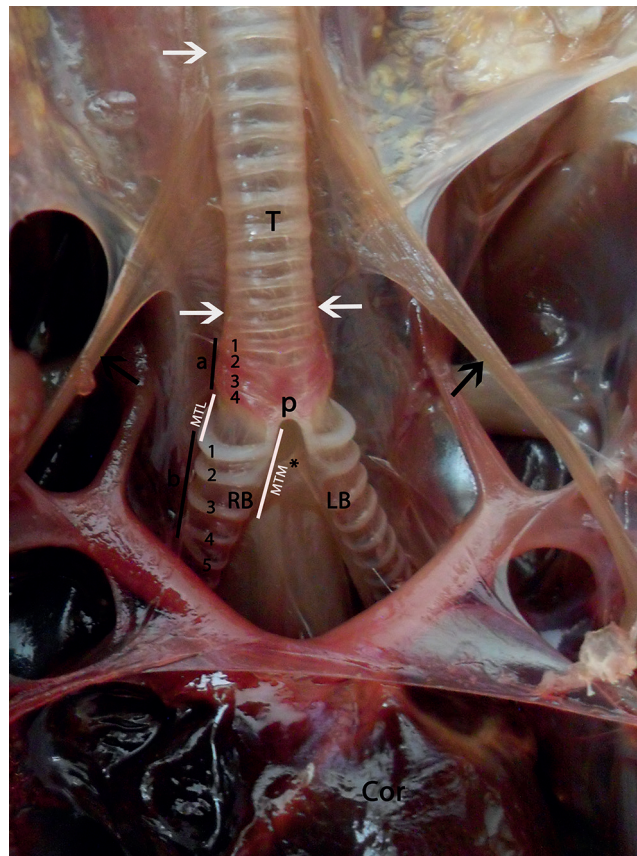


Figure 4: Dorsal view of syrinx, **a1-a4:** Cartilages of tracheosyringeal rings, **a2-a4:** Tympanum, **b:** Cartilages bronchosyringeal rings, **Black arrows:** Sternotracheal muscle, **White arrows:** Tracheolateral muscle, **MTM:** Membrana tympaniformis medialis, **MTL:** Membrana tympaniformis lateralis, **P:** Pessulus, **(*):** Ligamentum interbronchiale, **RB:** Right bronchiole, **LB:** Left bronchiole, **T:** Trachea.

it was observed that the fibers in the superficial layer were dorso-ventrally oriented (Figure 3).

Tracheal and bronchial (cartilagine bronchosyringeales) rings: Hyaline cartilage was observed to cover the syrinx externally. Tube-shaped tracheosyringeal cartilage commingled with each other and with three other types of cartilage, tracheal, bronchial and tracheobronchial, but not with the hyaline cartilage, which was ossified to create the tympanum. It was observed that cartilagine bronchosyringeales consisted of five cartilage rings in the shape a "C". It was also observed that the lateral tympaniform membrane was located between the last tympanum ring and the first cartilage bronchosyringeal ring (Figure 1 and Figure 4).

While extrinsic sternotracheal and tracheolateral muscles were found in the syrinx, it was also observed that tracheolateral muscles consisted of skeletal muscles with a circular

appearance. In addition, it was observed that these muscles were connected to bronchial cartilage rings playing a part in preventing deformation of the bronchial labia during movement (Figure 4).

DISCUSSION

In the current study, the anatomical and histological characteristics of the syrinx were studied for the first time in sparrowhawks. The morphologic structure of the syrinx has been investigated in many previous studies (8, 17-19), but this is the first study in the syrinx of Sparrowhawk.

As found in many studies of other avian species (7, 8, 18-21), the syrinx of sparrowhawks was the tracheobronchial type. The determination of the current study that the lateral tympaniform membrane was found between the last tympanum ring and the first cartilage bronchosyringeal ring agrees with data from other bird species such as long-legged buzzard, male mallard and ostriches (7, 8, 18), but conflicts with the data for sea gulls (22), which found that the lateral tympanum membrane was located between the first and second bronchosyringeal rings. It appears that these varieties arise from species difference.

It has been reported that the tympanum consists of five trachea rings in the chicken (14, 23), in the new world pigeon (17), the duck (10) and in the seagull (24) and consists of three trachea rings in the ostrich (18) and the long-legged buzzard (8). The current study determined that the sparrowhawk tympanum consisted of three trachea rings, like the ostrich and the long-legged buzzard.

Our anatomical and histological data determined that tracheolaryngeal cartilage was tube shaped and commingled with each other and the three other types of cartilages, tracheal, bronchial and tracheobronchial, but not with the hyaline cartilage, which was ossified to create the tympanum. In addition, cartilagine bronchosyringales consisted of five pieces of cartilage in the shape of a "C". Frank *et al.* (25) stated that cartilagine bronchosyringales consisted of bronchial and tracheal rings that ossified with age in male mallards (25) and pigeons (26). Warner *et al.* (27) and Morejohn (28) stated that the number of these cartilages varied from one to six in chickens. Getty *et al.* (21) stated this cartilage was in four pieces in the shape of a "C" and were connected to the pessulus of fowl, duct, lizard and chicken (21, 27, 28).

It has been reported that the pessulus consists of connec-

tive tissue in the new world pigeon (17) and ostrich (18) and consists of cartilage in chickens (29) and of an ossified form of cartilage in ducks (27) and passerines (30). In the current study, it was observed that the pessulus consists of hyaline cartilage resting on muscular mucosa. In addition, it was determined that the pessulus was covered with respiratory epithelium, and on histological analysis, PAS-positive (neutral) goblet cells were seen interspersed within the epithelium. It was also observed that this epithelium of the lateral pessulus's was in the columnar form. Although Savart (31) reported that different pessulus structures can be encountered in avian species and that this structure contributes to voice production, Warner (27) stated that the structure doesn't have vibratory ability, so it cannot be the source of sound.

Evaluation of data from the current study determined the existence of elastic and collagen fibers between the medial labia and medial tympaniform membrane tissues. It has been reported that this double-ply structure found in labium plays a part in tension of the labium (21). Previous studies have also reported that the double-ply structure increases the elasticity of dense elastic fibers, especially those found in deep layers of labium, and in this way it may ease frequency control (30). The current study concluded that density differences in double-ply elastic and collagen layers, situated between two epithelial layers plays a role in creating the extracellular matrixes of the visco-elastic structure.

From the present study it was determined that syrinx muscles of the sparrowhawk consisted of extrinsically circular skeletal muscles. It was observed that while these muscles were connected to bronchial cartilage rings in the medial lumen, they were also connected to ML extending up to the bronchial lumen on the ventral side. Yildiz *et al.* (19) reported that the syrinx muscles were extrinsic and intrinsic. While it has been reported that intrinsic muscles were found in passerines and parrots (32), it also has been reported that extrinsic muscles were found in domestic fowls (33), which agrees with our findings about the sparrowhawk syrinx.

It can be understood that these differences in muscle structure contribute to the creation of different sounds among bird species, since these muscle-structure differences determine the characteristics of the vibrations that play a part in sound creation. The current study presents the characteristic and morphologic features of the sparrowhawk's syrinx, thus differentiating it from other bird species. Although the tissues of the sparrowhawk's syrinx showed some similarities with

some other passerine bird species, it was clear that distinct histological and anatomic differences do exist.

REFERENCES

1. Fitch, W.T.: Acoustic exaggeration of size in birds via tracheal elongation: comparative and theoretical analyses. *J. Zool.* 248: 31-48, 1999.
2. Nickel, R., Schummer, A. and Seifirle, E.: *Anatomy of the Domestic Birds.* Verlag Paul Parey Berlin, Hamburg. p. 62-69, 1977.
3. Sisson, S. and Grossman, J.: *The Anatomy of the Domestic Animals,* WB Saunders: Philadelphia. p. 508-548, 1947.
4. Warner, R.W.: The anatomy of the syrinx in passerine birds. *J. Zool. Lond.* 168: 381-393, 1972.
5. Dursun, N.: Evcil Kusların Anatomisi. Ankara: Medisan Yayinevi. p. 91-96, 2002.
6. Baumel, J. and Club, N.: *Handbook of Avian Anatomy (Nomina Anatomica Avium).* 2nd ed. Nuttall Ornithological Club Cambridge. p. 261-297, 1993.
7. Frank, T., Probst, A., König, H.E. and Walter, I.: The syrinx of the male mallard (*Anas platyrhynchos*). *Anat. Histol. Embryol.* 36: 121-126, 2007.
8. Kabak, M., Orhan, I.O. and Haziroglu, R.M.: The gross anatomy of larynx, trachea and syrinx in the long-legged buzzard (*Buteo rufinus*). *Anat. Histol. Embryol.* 36: 27-32, 2007.
9. Scala, G., and Colella, G.: Sulla muscolatura intrinseca della syrinx dell'anatra. *Acta Med. Vet.* 34: 69-75, 1988.
10. Scala, G., Corona, M. and Petagalli, G.: Sur la structure de la syrinx chez le Canard (*Anas platyrhynchos*). *Anat. Histol. Embryol.* 19: 135-142, 1990.
11. Goller, F. and Larsen, O.N.: In situ biomechanics of the syrinx and sound generation in pigeons. *J. Exp. Biol.* 200: 2165-2176, 1997.
12. Goller, F. and Larsen, O.N.: A new mechanism of sound generation in songbirds. *Proc Natl. Acad. Sci.* 94: 14787-14791, 1997.
13. Larsen, O.N. and Goller, F.: Role of syringeal vibrations in bird vocalizations. *Proc. R. Soc. Lond. B.* 266: 1609-1615, 1999.
14. King, A.: *Functional Anatomy of the Syrinx.* London: Academic Press. pp. 105-182, 1989.
15. Bacha, W.J. and Bacha, L.M.: *Color Atlas of Veterinary Histology.* 2nd ed. Wiley Blackwell. pp. 187, 2000.
16. Campbell, T.W.: *Avian Hematology and Cytology.* Iowa State University Press. p. 55, 1995.
17. Mahler, B. and Tubaro, P.L.: Relationship between song characters and morphology in New World pigeons. *Biol. J. Linnean Soc.* 74: 533-539, 2001.
18. Yildiz, H., Bahadır, A. and Akkoc, A.: A study on the morphological structure of the syrinx in ostriches (*Struthio camelus*). *Anat. Histol. Embryol.* 32: 187-191, 2003.
19. Yildiz, H., Yilmaz, B. and Arican, I.: Morphological structure of the syrinx in the Bursa Roller Pigeon (*Columba livia*). *Bull. Vet. Inst. Pulawy.* 49: 323-327, 2005.
20. Cevik-Demirkan, A., Haziroglu, R.M. and Kurtul, I.: Gross morphological and histological features of larynx, trachea and syrinx in Japanese quail. *Anat. Histol. Embryol.* 36: 215-219, 2007.
21. Getty, R., Rosenbaum, C.E., Ghoshal, N. and Hillmann, D.: Sisson and Grossman's the Anatomy of the Domestic Animals. WB Saunders: Philadelphia. p. 508-548, 1975.
22. Gezer-Ince, N., Pazvant, G. and Alpak, H.: Anatomical features of the syrinx in sea gulls. *Ank. Univ. Vet. Fak. Derg.* 59: 1-3, 2012.
23. Freeman, B.: *Physiology and Biochemistry of the Domestic Fowl:* Academic Press. pp. 234-256, 1983.
24. Gezer-Ince, N. and Pazvant, G.: Martılarda larynx ve trachea uzerinde makro-anatomik calisma. *Ist. Uni Vet. Fak. Derg.* 36: 1-6, 2010.
25. Frank, T., Walter, I., Probst, A. and König, H.E.: Histological aspects of the syrinx of the male mallard (*Anas platyrhynchos*). *Anat. Histol. Embryol.* 35: 396-401, 2006.
26. Warner, R.W.: The syrinx in family Columbidae. *J. Zool. Lond.* 166: 385-390, 1972.
27. Warner, R.W.: The structural basis of the organ of voice in the genera *Anas* and *Aythya* (Aves). *J. Zool.* 164: 197-207, 1971.
28. Morejohn, G.V.: Variation of the syrinx of the fowl. *Poultry Sci.* 45: 33-39, 1966.
29. Gaunt, A.S., Gaunt, S.L.L. and Hector, D.H.: Mechanics of the Syrinx in *Gallus gallus*. I. A Comparison of Pressure Events in Chickens to Those in Oscines. *The Condor.* 78: 208-223, 1976.
30. Riede, T. and Goller, F.: Functional morphology of the sound-generating labia in the syrinx of two songbird species. *J. Anat.* 216: 23-36, 2010.
31. Savart, F.: Mémoire sur la voix des oiseaux. *Ann. de Phys. et de Chim. Bd.* 32: 5-113, 1826.
32. Seller, T.J.: *Bird Respiration.* Florida: Vol I, CRC Press. pp. 39-69, 1987.
33. Brackenbury, J.: Control of sound production in the syrinx of the fowl *Gallus gallus*. *J. Exp. Biol.* 85: 239-251, 1980.