

PESTE DES PETITS RUMINANTS IN SUCKLING LAMBS CASE REPORT

Aktas, M.S.,¹ Ozkanlar, Y.,¹ Simsek, N.,² Temur, A.³ and Kalkan, Y.³

¹ Department of Internal Medicine, Faculty of Veterinary Medicine, Ataturk University, Erzurum, Turkey

² Departments of Histology and Embryology, Faculty of Veterinary Medicine, Ataturk University, Erzurum, Turkey

³ Veterinary Control and Research Institute, Department of Pathology, Erzurum, Turkey

Corresponding author:

Assist Prof Mustafa Sinan Aktas

Ataturk University, Faculty of Veterinary Medicine

Department of Internal Medicine, Campus, Erzurum, Turkey

E-mail: sinanaktas74@yahoo.com or sinanaktas@atauni.edu.tr Tel: +904422315530

ABSTRACT

The aim of this study was to evaluate clinical presentation and mortality rates, post mortem findings, histopathological and immunohistochemical patterns, route of contamination and prophylaxis of peste des petits ruminants virus (PPRV) infection in a flock of 525 sheep. On clinical examination a high body temperature, coughing, lachrymal and nasal discharge, stomatitis aphthosa and diarrhea were present. Gross post mortem examination revealed ulcerative stomatitis, interstitial pneumonia and acute catarrhal enteritis. Inclusion bodies were observed in labial tissues on histopathological investigation. Cells of the lung, intestine and labial tissues containing PPR viral antigens were observed using immunohistochemical technique by the streptavidin-biotin-peroxidase method. Mortality rate in suckling lambs was much higher (100%) than in young (24%) and adult (5%) sheep.

Key words: Peste des petits ruminants; sheep; lambs; mortality rate

INTRODUCTION

Morbidity and mortality rates vary but can be as high as 100 and 90 percent. These highly contagious viruses include measles, canine distemper, rinderpest, peste des petits ruminants, phocid distemper and cetacean morbillivirus (2). Peste des petits ruminants virus (PPRV) primarily infects sheep and goats (3). The official French name Peste des petits ruminants (PPR) or ovine rinderpest is also known as kata, pseudorinderpest, pneumoenteritis complex and stomatitis-pneumoenteritis syndrome (4). The clinical manifestations of acute cases include high fever, depression, anorexia, ocular and nasal discharge, pneumonia, stomatitis and severe diarrhea (5). Morbidity and mortality rates vary but can be as high as 100 per cent, respectively (6). As seen in other morbillivirus infections, PPRV requires close contact between infected and susceptible animals for the spread of the disease where indirect contamination is hardly identified (4).

The disease, described firstly in West Africa in 1942 (7), was reported mostly in African countries (8, 9, 10, 11) and in Middle East (12, 13), South Asia (14, 15, 16), Central Asia (17) and in the Arabic peninsula (18). Its first presence was determined by Alcigir *et al.* (19) in Turkey. Following that PPR spread through Turkey in last decade at an alarming rate. The aim of this study was to evaluate clinical, histopathological, immunohistochemical findings, contamination, spread and prophylactic measures of PPR infection and the possible causes of the mortality rates for the different ages in a flock of 525 sheep in Erzurum, Turkey.

MATERIAL AND METHODS

Animals

Widespread mortality in a farm of 525 sheep was referred to the department of Veterinary Internal Medicine in Erzurum province, Turkey. The diseased animals were suspected of suffering from PPR due to the presentation with clinical symptoms of fever, stomatitis, pneumonia with lacrimal and nasal discharge, and diarrhea.

Pathological and immunohistochemical procedures

Five sheep were randomly selected to be necropsied. A detailed necropsy was carried out at the Veterinary Control and Research Institute in Erzurum, Turkey. Tissue samples of lung, liver, labial skin, buccal mucosa, and intestine were preserved in 10% buffered formalin, processed by routine histological methods (Shandon Citadel 1000 Autotechnicon) and embedded in paraffin blocks. Sections were cut at 5-6 μ m for staining and examination. Mallory's triple, hematoxylin eosin (HE) and immunohistochemical staining were performed.

PPR positive cells were detected by immunohistochemistry using the streptavidin-biotin-peroxidase method (Dako, REAL Detection System, Dako North America Inc., California, USA). For this method, tissue samples were deparaffinized in xylene and rehydrated through a decreasing series of ethanol concentrations. The sections were then incubated with 3% H₂O₂ in order to block endogenous peroxidase activity. Tissue

sections were digested with proteinase K (0.1%), and incubated with a rabbit anti-rinderpest antibody at a dilution of 1:100, and biotinylated secondary antibody (Dako-REAL EnVision HRP Rabbit/Mouse Kit-K5007). Subsequently, sections were incubated with streptavidin-HRP and binding sites of antibody were visualized with aminoethyl carbazole chromogen (AEC) or 3,3'-diaminobenzidine (DAB). Sections treated with AEC and DAB were covered by GVA mounting solution (Zymed® Laboratories; Catalog no: 00-8000) and entellan, respectively. Preparations were examined and photographed using a Leica DM 3000 research microscope equipped with a digital camera. The binding of antibody was evaluated under high-power examination.

RESULTS

Clinical findings

Most of the dead animals showed signs of diarrhea with perianal staining. Dehydration, high body temperature (greater than 40°C), weakness, recumbence, mucopurulent nasal and ocular discharges were observed in affected animals. Harsh vesiculo-bronchial sounds were detected during auscultation. Ulcerative necrotic lesions were observed around tongue, gum and labial regions. The most prominent findings were a high rate of mortality in the flock. It was determined that PPRV infection caused deaths in 86 of 525 sheep (16%) in the flock (Table 1). The office of animal health and control in Erzurum province was informed and preventive measures were immediately taken according to the law.

Table 1. Mortality rates in the flock

Age group	No. of animals	Mortality (%)
Adult (over one year)	355	18 (5)
Young (3-12 months)	134	32 (24)
Suckling (Below 3 months)	36	36 (100)
Total	525	86 (16)

Necropsy findings

On necropsy mucopurulent nasal discharge and crusts were present around the nostrils and the surface appeared ulcerative and hemorrhagic. Lesions of the oral cavity were localized to surfaces of the tongue, lips, and soft and hard palates and consisted of gray to yellow pseudomembraneous foci. The tonsillar surfaces were covered by fibrinous exudates and plaques. The lungs showed edema, hepatization and bronchial exudates. Lung lobes were consolidated and hemorrhagic. The intestinal mucosa was congested and covered with mucous. The Peyer's patches were hemorrhagic and necrotic. Hyperemia and ecchymosis of the abomasum and intestines were present.

Histopathology and Immunohistochemistry

Histopathologic changes were present in the buccal mucosa and tongue and tissues of intestine, lung, and liver. Prominent histological findings included necrosis of the buccal mucosa and crypts of small intestines. Intranuclear and intracytoplasmic inclusions were present in the epithelium of the stratum spinosum in labial skin (Figure 1a). Accompanying the necrosis of the epithelium and crypts there was an infiltration of plasma cells and mononuclear cells in the lamina propria. Hepatocyte degeneration and vacuolization accompanied by and lymphocyte and eosinophil granulocyte aggregation in portal spaces were in evidence. Additional findings included intense hyperemia and petechial hemorrhage in regions of the lung, degenerative changes in the alveoli, dilatation and eosinophil granulocyte infiltration into alveolar septum, lymphocyte accumulation about the lung arterioles, exudates in bronchi and bronchioles and eosinophils infiltration in the lymphoid tissue about the bronchi. Furthermore fibrocytic proliferation along with interstitial pneumonia was present.

Immunohistochemically, cells containing PPR viruses were seen as a brown color by DAB stain within the labial skin (Figure 1b) and as a red color by AEC stain within the intestine (Figure 2) and lung tissue (Figure 3a and 3b) by the streptavidin-biotin-peroxidase method. Positive control PPR skin, lung and intestinal tissues by RT-PCR were used along with negative controls from five healthy animals. The cells containing PPR viral antigens were determined as immunopositive in the stratum spinosum layer of the skin (Figure 1b), in the villi and crypts of the intestine (Figure 2), in mononuclear cells of the lamina propria and solitary or aggregate lymph follicles of intestines and in epithelia of bronchi and bronchioles and in the interalveolar septum of the lung (Figure 3a and 3b).

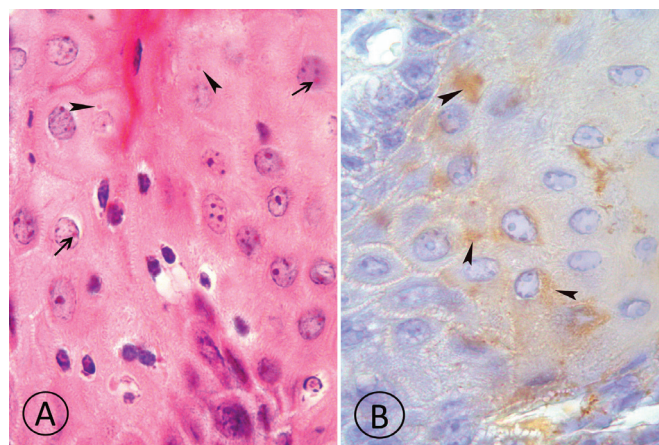
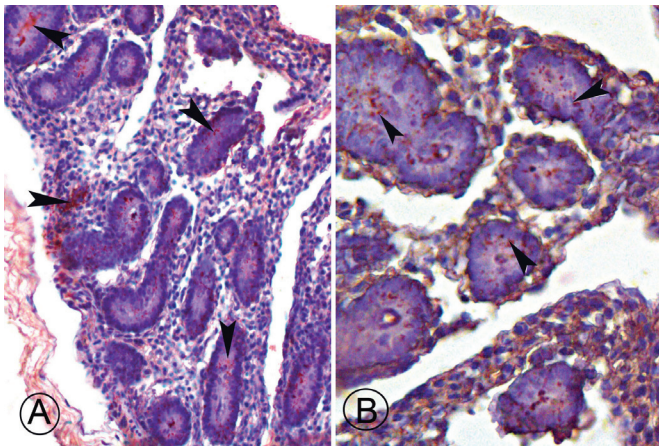
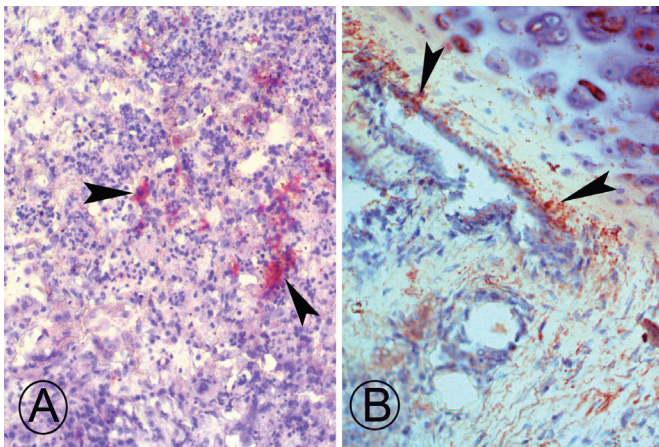


Figure 1. PPRV positive cells in stratum spinosum layer of labial skin. A) inclusion bodies both intranuclear (arrows) and intracytoplasmic (arrow heads). B) PPRV immunopositive cells (arrow heads). Streptavidin-biotin-peroxidase method + DAB chromogene. X625.



Figures 2 A and B. PPRV immunopositive reaction in villus and cripts of intestines (arrow heads). Streptavidin-biotin-peroxidase method + AEC chromogene. X275.



Figures 3 A and B. Positive reaction in lung tissue (arrow heads). Streptavidin-biotin-peroxidase method + AEC chromogene. X275.

DISCUSSION

PPR was thought to be confined to West Africa for 30 years (7). Subsequently, this devastating viral disease of sheep and goats was encountered as endemic in west and central Africa (8), in the north-east of the continent, Kenya and Uganda (9), Sudan (10) and Ethiopia (11). The disease has also been reported in Iran (12), Lebanon (13), Bangladesh (14), India (15), Pakistan (16), Tajikistan (17), Saudi Arabia (18), and Jordan (20) in the Middle East, Arabian Peninsula and South and Middle Asia. The disease was first described in Turkey in lambs by Alcigir *et al.* (19) and has further been reported in different parts of the country (21, 22, 23, 24, 25, 26, 27). Ozkul *et al.* carried out a survey showing that PPRV was present in 22.4% of sheep and goats in 18 different regions throughout Turkey (3). It is possible that this disease has been endemic for decades in certain regions of Turkey. Up to now, PPR cases

from the Erzurum province of Turkey are rare where one of the highest populations of farm animals exists and where many diseases are known to be encountered.

With lymphotropic and epitheliotropic feature, PPR virus induces the most severe lesions in organ systems rich in lymphoid and epithelial tissues. The entry of the virus is likely via the respiratory route. Replicating in lymph nodes, viremia develops in 2-3 days after infection and in 1-2 days before the first clinical sign appears. The spleen, bone marrow, gastrointestinal tract and the respiratory system are affected through the dissemination of the virus (8). Clinical symptoms of PPR infection have been reported by various investigators (5, 17, 28). In this report, all diseased animals suspected of PPR presented clinically with nasal and ocular discharge, necrotic lesions around tongue, gum and labial regions, pneumonia and enteritis. The clinical signs and high mortality rate in the flock directed the clinicians to a tentative diagnosis of PPR infection. To date the detection of PPRV by immunohistochemical methods has only been found from abattoir material (29). Up to this time no immunohistochemical positive confirmed clinical cases have been detected from the field.

In this study post mortem findings included ulceration and necrotic lesions in mouth, gingiva and labial mucosa were observed accompanied by hyperemia and ecchymosis in abomasum and intestinal epithelium. Roeder *et al.* (30) emphasized that the pathology caused by PPR is dominated by necrotizing and ulcerative lesions in the mouth and the gastrointestinal tract. Findings of pneumonia were also seen in lungs with bronchial exudates, edema and hepatization.

PPR is related to rinderpest (RP) virus of cattle (31). Small ruminants can be infected with RP virus and PPRV. Differential diagnosis is difficult due to the similar pathology of the two related diseases. However in clinical practice the post-mortem findings of pneumonia are important for the differential diagnosis of PPR. Lung lesions are not seen in RP (32) and animals rarely develop significant pneumonia (33).

Pathognomonic findings for PPR are reported as multinucleated syncytial cells in alveolar lumina with the presence of intracytoplasmic inclusion bodies in epithelial cells of the bronchi and bronchioles, together with mucosal lesions in the oral cavity (34). However in some animals with PPR, syncytial cells or inclusion bodies may not be observed in oral or pulmonary tissues while erosive-ulcerative stomatitis and bronchopneumonia are present (22). Yener *et al.* (23) observed the absence of inclusion bodies and explained this absence by the fact that animals had survived the acute phase of PPR and were in the recovery phase. Furthermore, alveolar syncytial cells are seen in some viral diseases such as parainfluenza-3 and respiratory syncytial virus (34, 35). It can be noted that, in such cases, the immunohistochemical detection of PPR viral antigen is of greater value. Scott (35) stresses that clinical and post mortem findings may be sufficient for the diagnosis of PPR in endemic areas, but histopathological examination and isolation of virus are essential in hitherto unaffected areas or areas in which outbreaks occur sporadically. In the present

cases, inclusion bodies both intranuclear and intracytoplasmic, and immunohistochemical confirmation was obtained from a wide variety of tissues thus confirming the diagnosis of PPRV.

PPR may be observed with an history of recent movement or gathering of sheep/goats for housing and feeding, introduction of recently purchased animals, contact in a flock that had been sent to market but returned unsold, contact with trade or nomadic animals through shared grazing, water and/or housing or changes in weather conditions such as the onset of the rainy season (6). Taking these factors into account, in the present case, a recent history of congregation of some sheep without following quarantine periods for housing and feeding had occurred on this farm and the fact that PPR had not been encountered on the farm until these events. Therefore, it is possible that the sheep may have been infected by sheep originating from another province. Therefore it needs to be stressed that animal movement needs to be strictly controlled.

PPR virus is rapidly inactivated by solar radiation and desiccation. Transmission of the infection is likely to occur by direct contact with the infected animals or their excretions or secretions (17). Close contact is the most important method of transmission where discharges from eyes, nose, mouth and feces contain large amounts of the virus (30). In this case presented here, the animals were rearing in half-open feedlots and all animals were kept in close contact with each other. Taylor *et al.* (36) found that the virus is thermally stable in degrees of -20, 4, 37 and 56°C in period of 24.2, 9.9, 3.3 and 2.2 days, respectively. Additionally, PPR has been mostly reported during rainy and winter seasons in subtropical areas (37). Consistent with the previous reports, the outbreak occurred in the month November during which rainy and cooler temperature predominate in Erzurum, Turkey.

Morbidity and mortality rates in infected regions can be as high as 100 per cent. In endemic areas these levels are typically lower (30). Levels of naturally or acquired immunity mostly influences the wide range of reported values as well as differences between species (sheep or goats) and production systems (28, 38). The susceptibility of young animals to the infection has been shown to be very high at 3 to 18 months of age with a more serious infection compared to adults or suckling animals (36). New born animals become susceptible to PPR infection at three to four months of age (39). Contrary to these reports, mortality rate in the present cases was 100% in suckling lambs, under 3 months of age. Furthermore there have been reports of different morbidity and mortality rates in outbreaks emphasizing higher mortality rates in suckling animals compared to young and adults animals (40). Control programs for PPR in endemic areas are mainly performed by vaccination (41). The vaccine is not dangerous at any stage of gestation and induces the production of colostral anti-PPR antibodies that have been found in sucklings for up to 3 months of age (38). The passive transfer of immunoglobulins is only possible in sheep/goat reared in endemic regions by through those animals which were vaccinated. Indeed, Das *et al.* (14) mentioned that mortality rate is higher in age group

of 5-8 weeks in Bengal goats. In the present study, adult animals without previous exposure to PPRV infection or vaccination did not have any colostral anti-PPR antibodies. Additionally, PPRV causes marked immunosuppression though lymphopenia thus reducing early antibody response to both specific and nonspecific antigen (42). Thus, the authors presume that the high mortality rate detected in the sucklings is mostly associated with immature immune defense system at that age and the lack of passive transfer of the antibodies. The high mortality may also be explained by such factors such as animal breed, age, season, and management, etc. The lower mortality rates seen in adults may be due to a decreasing susceptibility with age.

In conclusion, PPR infection is being encountered more frequently in recent years. The most important factors for infection are infrequent vaccinations and congregation of animals with observing quarantine periods. It is important to note that suckling animals under 3 months of age are more susceptible to PPR infection especially in a flock without prior exposure to PPRV or vaccination.

REFERENCES

1. Murphy, S.K. and Parks, G.D.: RNA replication for the paramyxovirus simian virus 5 requires an internal repeated (CGNNNN) sequence motif. *J. Virol.* 73: 805-809, 1999.
2. Barrett, T., Visser, I.K.G., Mamaev, L., Goatley, L., Bressemer, M.F. and Van Osterhaus, A.D.M.: Dolphin and porpoise morbilliviruses are genetically distinct from phocine distemper virus. *Virol.* 193: 1010-1012, 1993.
3. Ozkul, A., Akca, Y., Alkan, F., Barrett, T., Karaoglu, T., Dagalp, S.B., Anderson, J., Yesilbag, K., Cokcaliskan, C., Gencay, A. and Burgu, I.: Prevalence, distribution, and host range of peste des petits ruminants virus, Turkey. *Emer. Inf. Dis.* 8: 708-712, 2002.
4. Braide, V.B.: Peste des petites ruminants. *World Anim. Rev.* 39: 25-28, 1981.
5. Lefevre, P.C. and Diallo, A.: Peste des petits ruminants. *Revue Scientifique et Technique de l'Office International des Epizooties.* 9: 935-981, 1990.
6. Roeder, P.L., Obi, T.U., Taylor, W. and Diallo, A.: Recognizing peste des petit ruminants: a field manual. <http://www.fao.org/docrep/003/x1703e/x1703e00.htm>. Access date, 2010.
7. Gargadennec, L. and Lalanne, A.: La peste des petits ruminants. *Bulletin des Services Zootechniques et des Epizooties de l'Afrique Occidentale Francaise.* 5: 16-21, 1942.
8. Scott, G.R.: Rinderpest and peste des petits ruminants. In: Gibbs, E.P.J. (Ed.): *Virus Diseases of Food Animals*. 2nd ed, Disease Monographs, Academic Press, Newyork, pp. 401-425, 1981.
9. Barrett, T. and Anderson, J.: Peste des petits ruminants antibodies in East Africa. *Vet. Rec.* 136: 199-200, 1995.
10. Haroun, M., Hajer, I., Mukhtar, I. and Ali, B.E.: Detection of antibodies against peste des petits ruminants virus in

- sera of cattle, camels, sheep and goats in Sudan. *Vet. Res. Com.* 26: 537-541, 2002.
11. Abraham, G., Sintayehu, A., Libeau, G., Albina, E., Roger, F., Laekemariam, Y., Abayneh, D. and Awoke, K.M.: Antibody seroprevalences against peste des petits ruminants (PPR) virus in camels, cattle, goats and sheep in Ethiopia. *Prev. Vet. Med.* 70: 51-57, 2005.
 12. Abdollahpour, G., Raofi, A., Najafi, J., Sasani, F. and Sakhaie, E.: Clinical and para-clinical findings of a recent outbreaks of peste des petits ruminants in Iran. *J. Vet. Med. B.* 53: 14-16, 2006.
 13. Hilan, C., Daccache, L., Khazaal, K., Beaino, T., Massoud, E. and Louis, F.: Sero-surveillance of peste des petits ruminants ppr in Lebanon. *Lebanese Sci. J.* 1: 9-24, 2006.
 14. Das, K.K., Shil, N.K. and Islam, M.R.: Sero-epidemiological investigation on peste des petits ruminants in Black Bengal goats Bangladesh. *J. Microbiol.* 24: 143-145, 2007.
 15. Kataria, A.K., Kataria, N. and Gahlot, A.K.: Large scale outbreaks of peste des petits ruminants in sheep and goats in thar desert of India. *Slov. Vet. Res.* 4: 123-32, 2007.
 16. Abubakar, M., Jamal, S.M., Arshed, M.J., Hussain, M. and Ali, Q.: Peste des petits ruminants virus (PPRV) infection; Its association with species, seasonal variations and geography. *Trop. Anim. Health Prod.* Published online, 07 January, 2009.
 17. Kwiatek, O., Minet, C., Grillet, C., Hurardy, C., Carlssonz, E., Karimovz, B., Albina, E., Dialloy, A. and Libeau, G.: Peste des petits ruminants (PPR) outbreak in Tajikistan. *J. Comp. Path.* 136: 111-119, 2007.
 18. Al-Dubaib, M.A.: Prevalence of peste des petits ruminants infection in sheep and goat farms at the central region of the Saudi Arabia. *Res. J. Vet. Sci.* 1: 67-70, 2008.
 19. Alcigir, G., Atalay, V.S. and Toplu N.: Erste pathomorphologische und immunhistologische beschreibung der peste des petits ruminants bei den lämmern in der Türkei. *Vet. J. Ankara Univ.* 43: 181-189, 1996.
 20. Lefevre, P.C., Diallo, A., Schenkel, F., Hussein, S. and Staak, G.: Serological evidence of peste des petits ruminants in Jordan. *Vet. Rec.* 128: 110, 1991.
 21. Gül, Y., Dabak, M., Issi, M. and Başbug, O.: Peste des petitis ruminants (PPR) cases diagnosed in lambs and kids in Elazığ province in 1999. *Fırat Univ. Vet. J. Health Sci.* 1: 35-38, 2001.
 22. Toplu, N.: Characteristic and non-characteristic pathological findings in peste des petits ruminants (PPR) of sheep in the Ege District of Turkey. *J. Comp. Path.* 131: 135-141, 2004.
 23. Yener, Z., Saglam, Y.S., Temur, A. and Keles, H.: Immunohistochemical detection of peste des petits ruminants viral antigens in tissues from cases of naturally occurring pneumonia in goats. *Small Rum. Res.* 51: 273-277, 2004.
 24. Cam, Y., Gencay, A., Beyaz, L., Atalay, O., Atasever, A., Ozkul, A. and Kibar, M. Pesde des petits ruminants in a sheep and goat flock in Kayseri province, Turkey. *Vet. Rec.* 157: 523-524, 2005.
 25. Anderson, J. and Sammin, D.: Peste des petits ruminants in the thrace region of Turkey. *Empres Transboundary Anim. Dis. Bull.* 27: 12-15, 2005.
 26. Kul, O., Kabakci, N., Atmaca, H.T. and Ozkul, A.: Natural peste des petits ruminants virus infection: novel pathologic findings resembling other morbillivirus infections. *Vet. Pathol.* 44: 479-486, 2007.
 27. Albayrak, H. and Alkan, F.: PPR virus infection on sheep in blacksea region of Turkey: Epidemiology and diagnosis by RT-PCR and virus isolation. *Vet. Res. Com.* 33: 241-249, 2009.
 28. Wakwaya, K.: Epidemiological and serological investigations on ovine respiratory diseases and observation on vaccinated sheep on the highland of North Shoa/Sheno. In Doctor in Veterinary Medicine Thesis. Debre Zeit Faculty of Veterinary Medicine. 1997.
 29. Saglam, Y.S. and Temur, A.: Immunohistochemical detection of peste des petits ruminants (PPR) viral antigen from the cases of naturally occurring pneumonia in sheep. *Kafkas Univ. Vet. Fak. Derg.* 3: 325-330, 2009.
 30. Roeder, P.L., Abraham, G., Kenfe, G. and Barrett, T.: Peste des petits ruminants in Ethiopian goats. *Trop. Anim. Health and Product.* 26: 69-73, 1994.
 31. Diop, M., Sarr, J. and Libeau, G.: Evaluation of novel diagnostic tools for peste des petits ruminants virus in naturally infected goat flocks. *Epidemiol. Infect.* 133: 711-717, 2005.
 32. Barker, I.K., Dreumel, A.A.V. and Palmer, N.: The alimentary system. In: Jubb, K.V.F., Kennedy, P.C., Palmer, N. (Eds.): *Pathology of domestic animals*. 4 rd ed., Academic Pres, London. pp. 162-163, 1993
 33. Conference: In: Brown, C. (Coord.), *Proceedings of the Wednesday Slide Conference 2000-2001*, Department of Veterinary Pathology, The Armed Forces Institute of Pathology. 14-22 March 2001.
 34. Dungworth, D.L.: The respiratory system. In: Jubb, K.V.F., Kennedy, P.C., Palmer, N. (Eds.): *Pathology of Domestic Animals*. 4 rd ed., Academic Press, London, pp. 617-624, 1993.
 35. Scott, G.R.: Peste des petits ruminants. In: Dinter, Z., Morein, B., (Eds.): *Virus Infections of Ruminants*, 3 rd ed., Elseiver, Amsterdam. pp 355-361, 1990.
 36. Taylor, W.P., Abusaïdy, S. and Barrett, T.: The epidemiology of peste des petits ruminants in the Sultanate of Oman. *Vet. Microbiol.* 22: 341-352, 1990.
 37. Dhar, P., Sreenivasa, B.P., Barrett, T., Corteyn, M., Singh, R.P. and Bandyopadhyay, S.K.: Recent epidemiology of peste des petits ruminants virus (PPRV). *Vet. Microbiol.* 88: 153-159, 2002.
 38. Diallo, A. Peste des petits ruminants. In: Lefevre, P.C., Blancou, J., Chermette, R. (Eds.): *Principales maladies infectieuses et parasitaires du betail. Europe et regions chaudes. Tome 1 Generalites Maladies virales.* Lavoisier,

- Paris. pp. 307-322, 2003.
39. Srinivas, R.P. and Gopal, T.: Peste des petits ruminants (PPR): a new menace to sheep and goats. *Livestock Advisor*. 21: 22-26, 1996.
 40. Mirza, A.K., Hussain, S.N., Bahadar, S., Ali, A. and Shah, I.A.: An out break of peste des petits ruminants (ppr) in goats in district chitral, n.w.f.p., Pakistan. *Arpn J. Agric. and Biol. Sci.* 3: 9-22, 2008.
 41. Diallo, A.: Vaccination for the control of peste des petits ruminants. In: Schudel, A. and Lombard, M. (Eds.): *Control of infectious animal diseases by vaccination*. Buenos Aires, Argentina 13–16 April, 93-98, 2004.
 42. Rajak, K.K., Sreenivasa, B.P., Hosamani, M., Singh, R.P., Singh, S.K., Singh, R.K. and Bandyopadhyay, S.K.: Experimental studies on immunosuppressive effects of peste des petits ruminants (PPR) virus in goats. *Comp. Immunol. Microbiol. Infect. Dis.* 28: 287–296, 2005.