

A Rare Case of Bicuspid Aortic Valve in a German Shepherd Dog

Saini, N.,^{1*} Uppal, S.K.,² Tandon, R.,³ Dhaliwal, P.S.⁴ and Anand, A.⁵

¹Department of Veterinary Medicine, Guru Angad Dev Veterinary & Animal Sciences University (GADVASU), Ludhiana, 141004, Punjab, India.

²Department of Veterinary Medicine, Guru Angad Dev Veterinary & Animal Sciences University (GADVASU), Ludhiana, 141004, Punjab, India.

³Non-Invasive Cardiology, Hero Heart Institute, Unit of Dayan and Medical College (DMC), Ludhiana, Punjab, India.

⁴Guru Angad Dev Veterinary & Animal Sciences University (GADVASU), Ludhiana, 141004, Punjab, India.

⁵Department of Veterinary Surgery and Radiology, Guru Angad Dev. Veterinary & Animal Sciences University (GADVASU), Ludhiana, 141004, Punjab, India.

* **Corresponding author:** Present address of corresponding author: Dr. Neetu Saini, Assistant Professor, Dept. Of Veterinary Medicine, College of Veterinary Sciences, Guru Angad Dev Veterinary and Animal Sciences University (GADVASU), Ludhiana, 141004, Punjab, India. Email: sainin26@gmail.com

ABSTRACT

A bicuspid aortic valve (BAV) was diagnosed in a 9-year-old male German shepherd dog with the history of profound weakness, exercise intolerance and fever. Transthoracic echocardiography revealed aortic valve cusps an horizontal position indicating Type 2 bicuspid aortic valve morphology without median raphae, based upon the human classification. The ascending aorta and aortic root were dilated. Aortic regurgitation was also detected by continuous-wave and color-flow Doppler echocardiography. Moderate left ventricular hypertrophy with left ventricular dysfunction was also detected. Blood assays indicated septicemia which recovered after empirical antibiotic therapy. Enalapril was given for supporting the heart's ability to cope with left ventricular dysfunction, by decreasing both afterload and preload. The animal showed recovery with normalization of fever while aortic regurgitation still persisted after 8 months from the start of treatment. To the best of the authors' knowledge, BAV is a rarely reported cardiac anomaly in dogs.

Keywords: Bicuspid Aortic Valve; Echocardiography; Aortic Regurgitation; German Shepherd Dog.

INTRODUCTION

Bicuspid aortic valve (BAV) is one of the most common congenital cardiac abnormalities with the prevalence of 1-2 percent in humans (1). It is characterized by two cusps of unequal size with loss of inverted "Mercedes-Benz sign" or "Y" shape normally formed by the 3 aortic valve cusps during diastole on transthoracic echocardiography. This condition predisposes the patients to severe aortic regurgitation or stenosis especially in later age. It is 3 times more common in males as compared to females (2). In contrast, the existence of bicuspid aortic valve has been rarely reported in dogs (3). However, quadricuspid aortic valves has been extensively re-

ported in veterinary literature (4, 5). High incidence of bicuspid aortic valve in Syrian hamsters has also been reported (6). This case description describes the presentation of a bicuspid aortic valve, a relatively rare and poorly defined congenital heart anomaly in a 9 year old male German shepherd dog.

CASE HISTORY

A 9-year-old male German shepherd dog weighing 32 kg was referred to Teaching Veterinary hospital of Guru Angad Dev Veterinary & Animal Sciences University (GADVASU), Punjab in North India with the history of exercise intolerance, malaise and fever for one month. The problem started

with an untreated deep wound at the elbow joint and back. The dog was lethargic with profound weakness and depression. There was no history of coughing and dyspnea. There was no abdominal distension and no signs of ascites. The owner had not observed any weight loss.

On physical examination, the dog showed congested mucous membranes, generalized weakness and tachypnea (Respiration rate >50 breaths/min; reference range, 18-34 breaths/min). The heart rate was 80 beats per minute (reference range 70-120 beats per minute) with weak femoral pulse. The systolic blood pressure estimated by Doppler method (Vet-dop2, Model BF2, Vmed technology, USA) was 148 mm Hg. The jugular vein was normal. There was no lymphadenopathy. A systolic ejection click was heard on auscultation of the heart at the aortic area.

Blood investigations showed mild anemia (hemoglobin 10.9 g/dl; reference range, 12-19 g/dl), significant leukocytosis (total leukocyte count 34,390/ μ l; reference range, 5,000-14,100/ μ l) with neutrophilia (30,951/ μ l; reference

range, 5,000-14,100/ μ l). Peripheral blood smear indicated toxic changes in all immature neutrophils. Platelet count was adequate (3.04×10^5 / μ l; reference range, $2.1-6.2 \times 10^5$ / μ l) but was activated indicating septicemia. Biochemical analysis revealed normal liver function test (LFT) and normal renal function tests (RFT). The serum cardiac troponin I (cTnI) level was 1.41 μ g/dL (reference range, <0.200 μ g/dL). Aerobic blood culture revealed no growth.

Lateral view chest radiograph revealed prominence at level of the cranial waist of heart. In ventro-dorsal (VD) view, there was a bulge between 1 and 2 o'clock positions. This bulge was communicating with the passage of aorta (Figure 1a, b). A 6-lead ECG recording revealed wide QRS complexes indicating Left Bundle Branch Block (LBBB) (Figure 2).

A transthoracic two-dimensional (2D) echocardiographic study was carried out by using ultrasound equipment of GE Logiq P5 color Doppler (GE healthcare, Chicago, United States) equipped with a 5 S transducer. The right parasternal

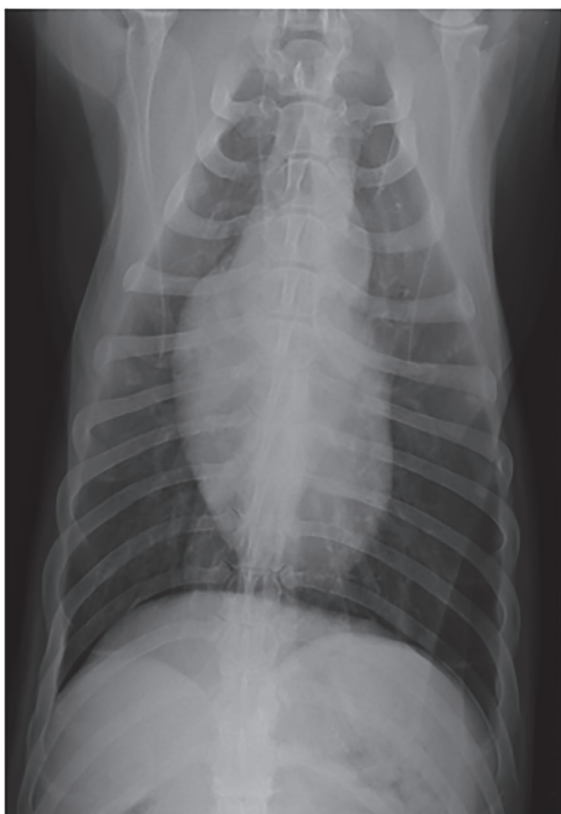


Figure 1a: Ventro-dorsal (VD) thoracic radiograph of the German shepherd dog showing a bulge between 1 and 2 O'clock position (arrow). This bulge is communicating with the passage of aorta

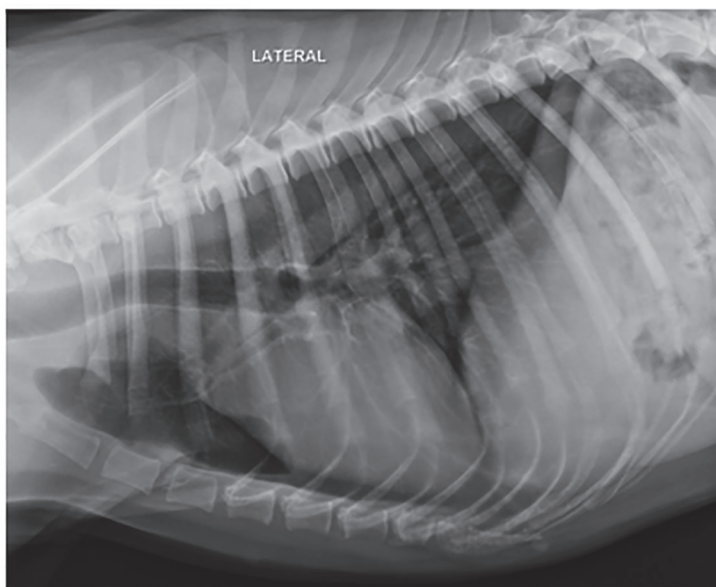


Figure 1b: Lateral chest radiograph revealed prominence at level of cranial waist of heart and trachea is lifted upwards

short axis view at the level of aorta revealed a bicuspid aortic valve with both aortic valve cusps in horizontal position indicating type 2 bicuspid aortic valve morphology without median raphe (3). The normal opening of aortic valve was lost as it became more to resemble “fish like mouth” in shape which was more pronounced in systole (Figure 3a). The aortic valve leaflets were approximately 0.54 cm thick with no calcification. Right parasternal long axis view indicated eccentric closure of the aortic valve. No vegetations or other evidence of bacterial infection were demonstrated on or near the aortic valve cusps. The aortic flow velocity, measured from left apical five-chamber view with continuous-wave Doppler was 2.58 m/sec (reference, 1.02 ± 0.143 m/s). According to Bernoulli's equation, calculated peak aortic pressure gradient was 26.62 mm of Hg (7).

Color flow Doppler at aortic valve revealed large eccentric jet of aortic regurgitation. There was apparently dilation of the ascending aorta without coarctation. The diameter of aortic root and ascending aorta were found to be 2.20 cm and 3.06 cm respectively on suprasternal view (Figure 3b). There was increased diastolic thickness of the septal wall (1.54 cm; reference range, 0.96 ± 0.09 cm) as well as left ventricular posterior wall (1.27 cm; reference, 0.88 ± 0.11 cm) as compared to normal reference range indicating concentric left ventricular hypertrophy. The mitral and tricuspid valves demonstrated trivial myxomatous mitral regurgitation. The

Transmitral E and A wave ratio was normal (0.98; reference range, 0.98-1.70). M mode left ventricular dimensions i.e., left ventricular internal dimensions during diastole (LVIDd) and systole (LVIDs) were 3.72 cm (reference range, 4.94 ± 0.46 cm) and 3.17 cm (reference range, 3.42 ± 0.33 cm) respectively. The fractional shortening (FS) was low (%FS; 14.63%; reference range, 28.63 ± 6.52 %) indicating left ventricular systolic dysfunction. The dimensions of aorta (Ao) and left atrium (LA) taken at right parasternal short axis view at the level of aorta were 2.28 cm (reference range, 2.52 ± 0.16 cm) and 3.03 cm (reference range, 2.43 ± 0.21 cm) respectively with LA: Ao ratio of 0.75 cm (reference range, 0.97 ± 0.09 cm). A bicuspid aortic valve with mild root involvement, severe aortic regurgitation and moderate systolic left ventricular dysfunction were diagnosed in the present case.

The patient was empirically treated with antibiotics, Amoxicillin and clavulanic acid (20 mg/kg PO every 12 hr; Augmentin 625mg/tablet; Glaxosmithkline Pharmaceuticals Ltd., Mumbai, India), amikacin (5 mg/kg IM every 12 h, Amikacin Sulphate 250 mg/mL; Cadila pharmaceuticals Ltd., India) for 3 weeks to treat septicemia. Enalapril (0.5mg/ kg PO every 12 hr, Envas 10 mg/tablet; Cadila Pharmaceuticals Ltd., India) was given for 1 month. The animal showed significant improvement in clinical examination after 3 weeks of treatment. The septicemia was treated successfully with a total leukocyte count ($13,870/\mu\text{l}$) and

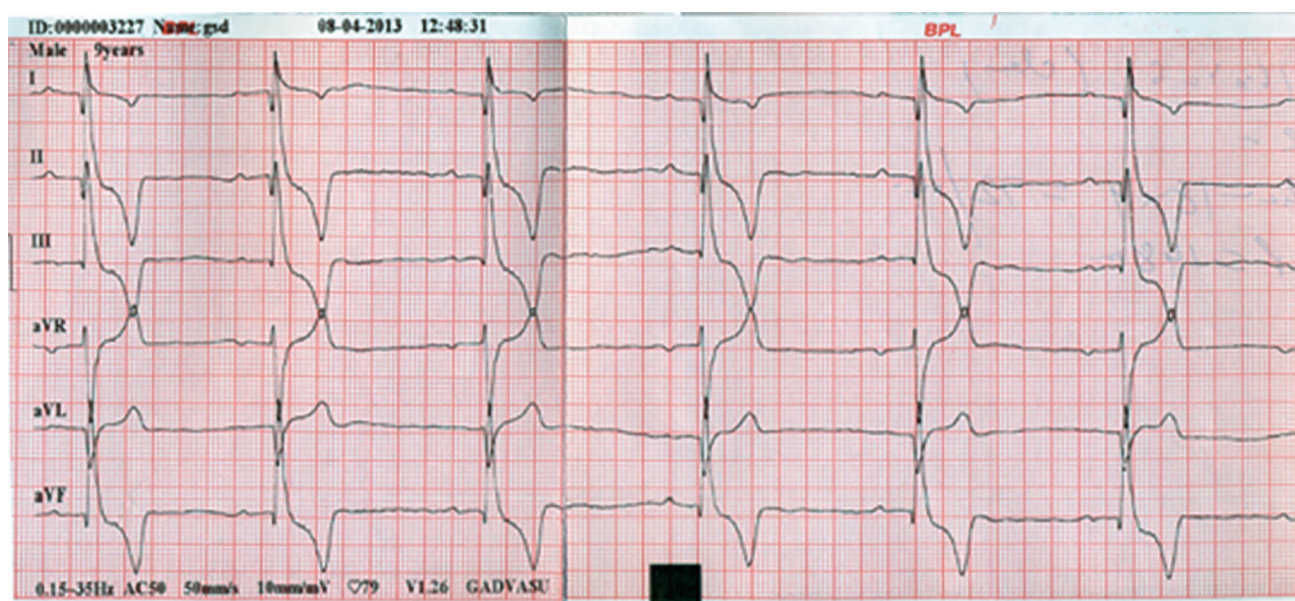


Figure 2: Left bundle branch block in a German shepherd dog with bicuspid aortic valve. Paper speed is 50 mm/sec. The QRS complex width is increased to 0.08 seconds (4 boxes). MEA = $+60^\circ$, Heart rate = 78 bpm, PR interval = 0.14 seconds, QT interval = 0.26 seconds.

neutrophil count (12,205/ μ l) in normal range. However, the owner was advised to continue enalapril for life to support the heart's ability to cope with left ventricular dysfunction, by decreasing both afterload and preload and also suggested serial rechecking every fortnight.

During the treatment period, clinical examination, blood pressure monitoring and echocardiographic examination was done every fortnight. At six months recheck up, the dog was very active and alert with less signs of weakness. The owner was advised to come for serial rechecking every 3 months to monitor the progression of cardiac changes. The aortic flow velocity remained high with a high pressure gradient at aortic valve with aortic regurgitation. However, the dog was apparently healthy at the time of writing this report, 8 months from start of treatment.

DISCUSSION

The bicuspid aortic valve is a common congenital cardiac malformations in humans. Contrary to humans, the descriptions of BAV in dogs is rare (3). BAV was found twice only in a study of congenital cardiac anomalies in group of 976 dogs (8). BAV is considered as a rare cause of aortic stenosis in dogs (9). Recently, BAV has been described in one year old male English bulldog (3).

The most common abnormality associated with bicuspid aortic valve is dilation of ascending aorta called aortopathy (10). This is not only due to altered blood flow in the aorta

but also due to cellular structural abnormalities including decreased fibrillin leading to smooth muscle cell detachment and cell death (10). Dilation of the ascending aorta as present in this case was in agreement with the similar findings in humans (11). Coarctation of aorta has been found to be other major abnormality associated with BAV in 85 percent of human cases (10, 12). But in the present study in this dog no coarctation of the aorta was detected.

Bicuspid aortic valve is common in middle aged patients and only 2 percent of children have clinically significant BAV (13). It can range from severe aortic stenosis in childhood to the asymptomatic disease until old age (13). Consistent with the findings in some humans, the dog in the present case was also asymptomatic for up to 9 years of age. The symptoms of BAV deteriorate with severity of stenosis which may be due to leaflet calcification which occurs mostly in human patients by 40 years of age (10). The aortic valve leaflets were also thickened in the present case. The size of the ascending aorta was increased in the current case which is consistent with the results of various workers who documented that the size of aorta is generally larger in patients with BAV as compared to the patients with normal valves (14, 15).

Previous workers observed severe left ventricular dilation and impairment in two human patients with bicuspid aortic valves (16), however moderate concentric left ventricular hypertrophy was present along with impaired left ventricular systolic functions in the present case. This was in agreement

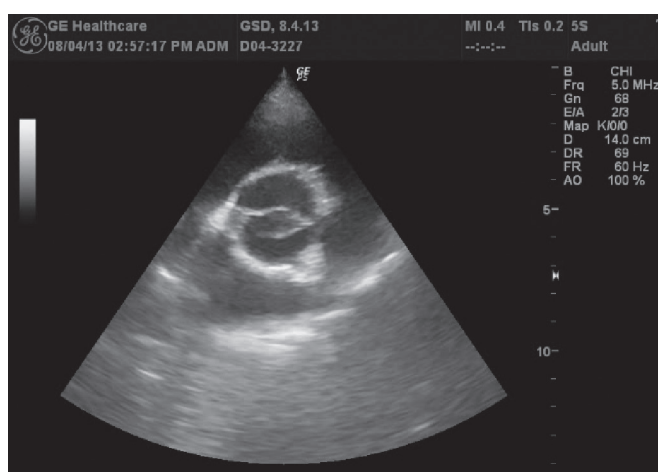


Figure 3a: Right parasternal short axis view of the heart base of 9 year old German shepherd dog showing two aortic valve cusps (arrow) of unequal size giving “fish mouth like” appearance which is more pronounced in systole.

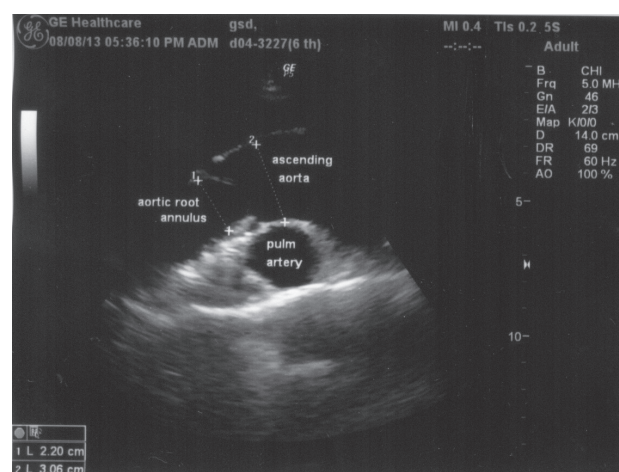


Figure 3b: Apparently dilated ascending aorta and aortic root in suprasternal view.

with findings of a few workers who documented that patients with aortic stenosis had concentric hypertrophy (17). The percentage FS is the most common indicator of LV systolic functions. Low value percentage of FS in the present case indicated systolic dysfunction. The peak aortic velocity in the current case was more than 2.5 m/sec which is consistent with mild aortic stenosis (18).

Left bundle branch block and left ventricular hypertrophy can occur together and are difficult to interpret, but when the QRS complexes are wider than 0.07 seconds, left bundle branch may be diagnosed (19). Left bundle branch block is associated with various pathological conditions like primary myocardial diseases (dilated cardiomyopathy) and endocarditis (20). LBBB has also been found to be associated with congenital subvalvular aortic stenosis in some dogs (21).

According to human classification scheme for BAV morphology, depending upon the orientation of aortic valve cusps obtained from right parasternal short axis view, three different types of BAV i.e. Type 1, 2 and 3 are identified in humans (22). The BAV of the present case was consistent with type 2 BAV (fusion of right and non-coronary cusps) with absent median raphe.

Human BAV is usually associated with other congenital malformations like patent ductus arteriosus, supravulvular aortic stenosis, ventricular septal defect, atrial septal defect and coronary artery anomalies (23). The clinical consequences in human patients with a bicuspid valve include significant valve regurgitation, endocarditis, aortic aneurysm and dissection and severe stenosis resulting from superimposed calcific changes (24).

Some clinicians recommend the use of beta-blockers, angiotensin-converting enzyme inhibitors (ACEI) and angiotensin II receptor blockers in humans with BAV associated with the Marfan syndrome, to slow down the progression of aortic dilatation (25). The benefits of using beta blockers to prevent aortic dilation are not clear (26) and may have actually been absent in the context of left ventricular systolic dysfunction such as in the present case; however some workers are of the opinion that ACEI might play an important role for patients with BAV (27).

The owner was informed about the long-term prognosis, emphasized dental hygiene, endocarditis prophylaxis (24) and advised to come for periodic echocardiography to evaluate the valve function.

This report describes BAV in a nine-year old German

shepherd dog. Similar to humans with BAV, both stenosis and regurgitation of the aortic valve were noted. The dog of this report appeared to have a type 2 BAV with fusion of the left coronary cusp and non-coronary cusp. The authors propose that awareness about this rare congenital anomaly by veterinary cardiologists performing echocardiographic studies in dogs may identify more dogs with BAV in the future.

ACKNOWLEDGEMENT

The authors wish to thank faculty, Department of Veterinary Medicine, Guru Angad Dev Veterinary & Animal Sciences University (GADVASU) for providing facilities to conduct this study.

CONFLICT OF INTEREST STATEMENT

We declare that we have no conflict of interest.

REFERENCES

1. Ward, C.: Clinical significance of the bicuspid aortic valve. *Heart*.83: 81-85, 2000.
2. Ercan, T., Ekici, F., Atalay, S. and Nacar, N.: The prevalence of bicuspid aortic valve in newborns by echocardiographic screening. *Am. Heart J.*150: 513-515, 2005.
3. Visser, L.C. and Scansen, B.A.: Congenital bicuspid aortic valve in an English bulldog. *J. Vet. Cardiol.*15: 87-92, 2013.
4. Sisson, D. and Riepe, R.: Congenital quadricuspid aortic valve anomaly in two dogs. *J. Vet. Cardiol.* 2: 23-26, 2000.
5. Serres, F., Chetboul, V., Sampedrano, C. C., Gouni, V. and Pouchelon, J.L.: Quadricuspid aortic valve and associated abnormalities in the dog: Report of six cases. *J. Vet. Cardiol.*10: 25-31, 2008.
6. Fernandez, M. C., Duran, A. C., Real, R., López, D., Fernández, B., de Andrés A.V., Arque, J.M., Gallego, A. and Sans-Coma, V.: Coronary artery anomalies and aortic valve morphology in the Syrian hamster. *Lab. Animals.* 34: 145-154, 2000.
7. Boon, J.A.: *Manual of Veterinary Echocardiography*. Boon, J.A. (Ed): Philadelphia, Lippincott Williams & Wilkins. 2011.
8. Oliveira, P., Domenech, O., Silva, J., Vannini, S., Bussadori, R. and Bussadori, C.: Retrospective review of congenital heart disease in 976 dogs. *J. Vet. Intern. Med.* 25: 477-483, 2011.
9. Oyama, M. A., Sisson, D. D., Thomas, W.P. and Bonagura, J.D.: Congenital Heart Disease. In: Ettinger, S.J. Feldman, E.C. (Eds): *Text book of Veterinary Internal Medicine*. 7th ed. St. Louis, Elsevier, pp. 1250-1298, 2010.
10. Mordi, I. and Tzemos, N.: Bicuspid aortic valve disease: A comprehensive review. *Cardiol. Res. Pract.* doi:10.1155/2012/196037, 2012.
11. Siu, S.C. and Silversides, C.K.: Bicuspid aortic valve disease. *J. Am. Coll. Cardiol.* 55: 2789-2800, 2010.
12. Presbitero, P., Demarie, D., Villani, M., Perinetti, E.A., Riva, G., Orzan, F., Bobbio, M., Morea, M. and Brusca, A.: Long term results (15-30 years) of surgical repair of aortic coarctation. *Br. Heart. J.* 57: 462-467, 1987.

13. Bonow, R.O., Carabello, B.A., Kanu, C., de Leon, A.C., Jr., Faxon, D.P., Freed, M.D., Gaasch, W.H., Lytle, B.W., Nishimura, R.A., O'Gara, P.T., O'Rourke, R.A., Otto, C.M., Shah, P.M., Shanewise, J.S., Smith, S.C., Jr. Jacobs, A.K., Adams, C.D., Anderson, J.L., Antman, E.M., Faxon, D.P., Fuster, V., Halperin, J.L., Hiratzka, L.F., Hunt, S.A., Lytle, B.W., Nishimura, R., Page, R.L. and Riegel, B.: ACC/AHA2006 guidelines for the management of patients with valvular heart disease: a report of the American College of Cardiology/American Heart Association Task Force on Practice Guidelines (Writing Committee to Revise the 1998 Guidelines for the Management of Patients with Valvular Heart Disease) *Circulation*. 114: 84-231, 2006.
14. Clair, M., Fernandes, S.M., Khairy, P., Graham, D.A., Krieger, E.V., Opatowsky, A.R., Singh, M.N., Colan, S.D., Meijboom, E.J. and Landzberg, M.J.: Aortic valve dysfunction and aortic dilation in adults with coarctation of the aorta. *Congenit. Heart. Dis.* 9:235-243, 2013. doi: 10.1111/chd.12109, 2013.
15. Morgan-Hughes, G.J., Roobottom, C.A., Owens, P.E. and Marshall, A.J.: Dilatation of the aorta in pure, severe, bicuspid aortic valve stenosis. *Am. Heart. J.* 147: 736-740, 2004.
16. Saha, S., Bastiaenen, R., Hayward, M. and McEwan, J.R.: An undiagnosed bicuspid aortic valve can result in severe left ventricular failure. *Br. Med. J.* 334: 420-422, 2007.
17. Kasner, M., Westermann, D., Steendijk, P., Gaub, R., Wilkeshoff, U., Weitmann, K., Hoffmann, W., Poller, W., Schultheiss, H.P., Pauschinger, M. and Tschope, C.: Utility of doppler echocardiography and tissue doppler imaging in the estimation of diastolic function in heart failure with normal ejection fraction: A comparative doppler-conductance catheterization study. *Circulation*. 116: 637-647, 2007.
18. Kienle, R.D., Thomas, W.P. and Pion, P.D.: The natural clinical history of canine congenital sub aortic stenosis. *J. Vet. Intern. Med.* 8: 423-431, 1994.
19. Bolten, G.R.: The arrhythmias. In: *Handbook of canine electrocardiography*. Saunders, Philadelphia, pp. 89-171, 1975.
20. Cote, E. and Ettinger, S.J.: Electrocardiography and cardiac arrhythmias. In: Ettinger, S.J. and Feldman, E.C. (Eds): *Textbook of Veterinary Internal Medicine*. Elsevier, Saunders, pp. 1044-1076, 2000.
21. Tilley, L.P.: Analysis of canine P-QRS-T deflections. In: Tilley, L.P. (Ed): *Essentials of canine and feline electrocardiography*. Philadelphia, Lea & Febiger, pp. 75-77, 1992.
22. Schaefer, B.M., Lewin, M.B., Stout, K.K., Gill, E., Prueitt, A., Byers, P.H. and Otto, C.M.: The bicuspid aortic valve: an integrated phenotypic classification of leaflet morphology and aortic root shape. *Heart*. 94: 1634-1638, 2008.
23. Braverman, A.C., Guven, H., Beardslee, M.A., Makan, M., Kates, A.M. and Moon, M.R.: The bicuspid aortic valve. *Curr. Probl. Cardiol.* 30: 470-522, 2005.
24. Lewin, M.B. and Otto, C.M.: The bicuspid aortic valve adverse outcomes from infancy to old age. *Circulation*. 111: 832-834, 2005.
25. Thakur, V., Rankin, K.N., Hartling, L. and Mackie, A.S.: A systematic review of the pharmacological management of aortic root dilation in Marfan syndrome. *Cardiol. Young.* 23: 568-581, 2013.
26. Fedak, P.W., Verma, S., David, T.E., Leask, R.L., Weisel, R.D. and Butany, J.: Clinical and pathophysiological implications of a bicuspid aortic valve. *Circulation*. 106: 900-904, 2002.
27. Ahimastos, A.A., Aggarwal, A., D'orsa, K.M., Formosa, M.F., White, A.J., Savarirayan, R., Dart, A.M. and Kingwell, B.A.: Effect of perindopril on large artery stiffness and aortic root diameter in patients with Marfan syndrome: a randomized controlled trial. *J. Am. Med. Assoc.* 298: 1539-1547, 2007.