

Excision Arthroplasty for Treatment of a Chronic Traumatic Medial Scapulohumeral Joint Luxation in a Dog

Hodik, V.,^{1*} Golovanov, A.² and Ranen E.³

¹ Private Small Animal Veterinary Practice; 17 Henrieta Szold St., Petach-Tikva, Israel.

² Private Small Animal Veterinary Practice; 15 Tirza St., Ramat-Gan, Israel.

³ Koret Veterinary School, Hebrew University, Jerusalem, Israel.

* **Corresponding author:** Dr. Vyacheslav Hodik, DVM, M.Sc., 17 Henrieta Szold St., Petach-Tikva, Israel, 49532. Telephone: +972-50-7968392. E-mail: hodikvet@netvision.net.il

ABSTRACT

A 12 year old intact male toy poodle was presented with an 18 month history of non-weight-bearing lameness of the right forelimb. The right shoulder joint was radiographed and found to be luxated with secondary degenerative changes of the periarticular structures. No signs of primary dysplasia of the glenoid cavity of the scapula or humeral head were detected. The shoulder joint was explored surgically and, based on the severe damage to the articular cartilage, it was concluded that open reduction and stabilization of the shoulder joint was contraindicated. Excision arthroplasty of the shoulder by ostectomy of the glenoid cavity and humeral head was performed. The dog began to bear weight on the operated leg two weeks after surgery. Two months later there was a significant improvement, and by 5 months postoperatively, he was fully functional. The dog remained sound for the following 6 months until it was euthanized for reasons unrelated to the surgery. To the best of our knowledge, this is the first description of successful implementation of excision shoulder arthroplasty for a such a prolonged shoulder luxation. The current case is the fourth reported case of a dog treated by excision arthroplasty, involving ostectomy of both glenoid cavity and humeral head, and the second case utilizing this technique for treatment of chronic medial shoulder luxation.

Key Words: Excision arthroplasty, shoulder, canine scapulohumeral joint, medial shoulder luxation, dog.

INTRODUCTION

Excision arthroplasty has been proposed as an alternative procedure for salvage of the canine scapulohumeral joint that cannot be effectively treated by conventional techniques (1, 2). Two techniques of excision shoulder arthroplasty have been described. In one technique, only an ostectomy of the glenoid cavity of the scapula was performed (1). In a report, 8 of 10 dogs treated with this technique suffered from medial shoulder luxation (1). One 8 month old dog suffered from degenerative joint disease (DJD) as a result of congenital joint surface incongruity, and one dog had a five-week-old comminuted glenoid fracture. Duration of lameness prior to treatment ranged from 3 weeks to 3.5 months. Follow-up pe-

riod ranged from 5 months to 6 years and results of surgery were good to excellent (1).

An alternative technique was described by Breuker and Piermattei (2). In this technique shoulder arthroplasty was performed by ostectomy of both the glenoid cavity of the scapula and the humeral head. Three dogs were treated using this technique (2). One of the dogs had a recent comminuted fracture of the glenoid cavity, and the second had DJD that resulted in a left forelimb lameness which progressed to a non-weight-bearing lameness over an 8 month period. The third dog suffered from bilateral medial shoulder luxation of 5 months duration. Follow-up period ranged from 12 to 62 months and all three dogs regained pain-free use of their

limbs. The authors concluded that excision arthroplasty was a very effective salvage procedure, but noted that the number of dogs treated was too small to draw any definitive conclusions about its indications, usefulness and complications (2).

In this report we describe excision arthroplasty, involving ostectomy of both glenoid cavity and humeral head, for treatment of medial shoulder luxation of 18 month duration. To the best of our knowledge, this is the first description of successful implementation of excision shoulder arthroplasty in such a chronic lesion.

CASE HISTORY

A 12 year old intact male toy poodle, weighing 4 kg, was referred to our clinic with an 18 month history of non-weight-bearing lameness of the right forelimb. The owners reported an acute onset of lameness and suspected a traumatic etiology. Medial shoulder luxation was diagnosed and unsuccessfully treated by closed reduction and immobilization at the time of onset of clinical signs. At presentation the dog carried his right forelimb flexed and only occasionally placed its foot on the floor. On physical examination there was severe atrophy of the supraspinatus and infraspinatus muscles, a decreased range of motion, particularly in extension, and pain on manipulation of the shoulder.

Radiographs were performed under general anesthesia. Morphine hydrochloride (Teva, Hungary) (0.5 mg/kg) and acepromazine maleate (PromAce, Fort Dodge Animal Health, Fort Dodge, Iowa, USA) (0.05 mg/kg) were given intramuscularly as premedication. Anesthetic induction was carried out with intravenous ketamine hydrochloride (Ketaset, Fort Dodge Animal Health, Fort Dodge, Iowa, USA) (3 mg/kg) and diazepam (Assival, Teva, Hungary) (0.3 mg/kg). After intubation anesthesia was maintained with isoflurane (Abbott Laboratories, Ltd., England) (1-2 vol% of oxygen). A diagnosis of medial luxation of right shoulder joint was made (Figure 1). Secondary degenerative changes, such as increased soft tissue opacity on the lateral aspect of the joint and periarticular soft tissue mineralization on its medial aspect were also visualized (Figure 1b). Mild osteophyte formation on the supraglenoid tuberosity was evident on the

lateral projection of the joint (Figure 1a). No signs of primary dysplasia of the glenoid cavity or humeral head were seen.

Attempts at closed reduction of the glenohumeral joint, under general anesthesia, were unsuccessful. Surgical exploration of the joint was performed via a craniolateral approach with osteotomy of the acromion process (3). The articular surfaces were rough white-gray color. The cartilages of both glenoid cavity and humeral head were found to be soft and easily detachable from the subchondral bone.

Based on the severe damage to the articular cartilage, it was concluded that open reduction and stabilization of the shoulder joint was contraindicated. Excision arthroplasty of the shoulder by ostectomy of the glenoid cavity and humeral head was performed (Figure 2), as previously described (2). The ostectomy was carried out using a Liston bone-cutting forceps and then smoothed with bone rongeur.

Post-surgical analgesia was carried out using morphine hydrochloride (0.5 mg/kg IM) given intramuscularly at the time of premedication; carprofen (Rimadyl, Pfizer, Vericore Ltd., England) (4 mg/kg SC) given subcutaneously at the time of surgical field preparation; tramadol hydrochloride (Grunenthal GmbH, Germany) (5 mg/kg IV) given intra-

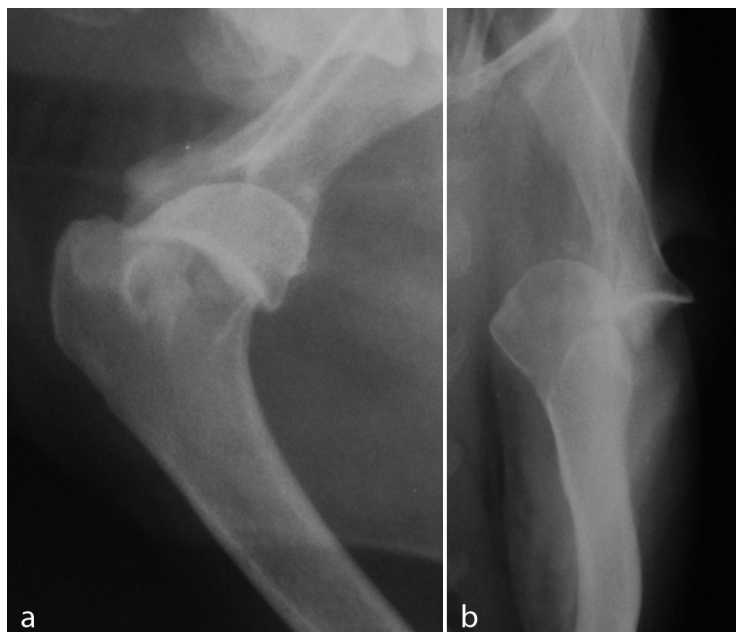


Figure 1. Lateral (a) and posteroanterior (b) view of right scapulohumeral joint. Medial luxation is present (b). Increased soft tissue opacity on the lateral aspect of the joint and periarticular soft tissue mineralization on its medial aspect are present (b). Mild osteophyte formation on the supraglenoid tuberosity is evident on the lateral projection of the joint (a).

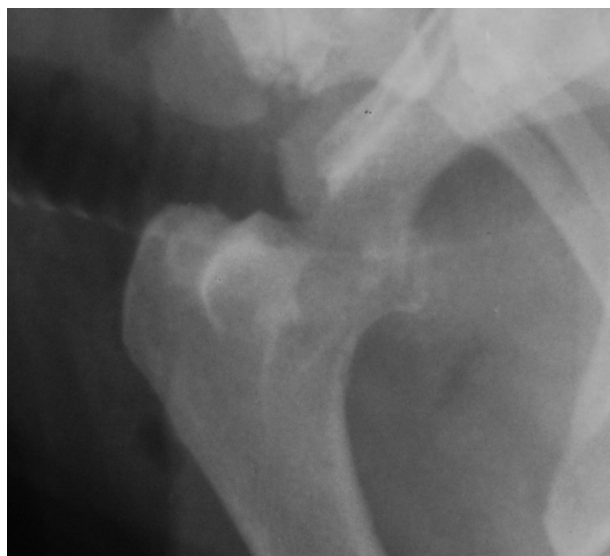


Figure 2. Lateral view of right scapulohumeral joint after osteotomy of the glenoid cavity of the scapula and humeral head taken immediately after surgery.

venously at the end of the surgical procedure. Recovery from the surgery was uneventful.

Carprofen (Norocarp, Norbrook Laboratories Ltd., Northern Island) (2.5mg/kg per PO BID) was administered for the first 7 days post-operatively. Use of the limb was encouraged by leash walking and physiotherapy by use of passive range of motion exercises starting on the third day post-operatively. The dog began to bear weight on the operated leg two weeks after surgery. Two months thereafter there was a significant improvement, and by 5 months post-operatively, the right forelimb was fully functional with an occasional shift in weight to the left forelimb when standing. On physical examination the shoulder was no longer painful when palpated and the range of motion was significantly increased differing from the healthy non-operated leg by only 20°. Atrophy of the supraspinatus and infraspinatus muscles, and muscles of the brachium was still evident and the operated limb was found to be 2 centimeters shorter on extension than the healthy contralateral leg. The dog remained sound for the following 6 months until it was euthanized for reasons unrelated to the surgery.

DISCUSSION

Medial luxation of the scapulohumeral joint is the most common form of shoulder luxation in small breeds of dogs (4, 5, 6). Treatment of medial shoulder luxation is dictated by

specific conditions such as severity of damage to soft tissues and joint surfaces. Cases of acute traumatic shoulder luxation in which the anatomy is normal and the joint is stable after closed reduction, may be successfully treated by immobilization with the velpeau sling (4, 5). If the joint remains unstable after reduction or relaxates, surgical treatment is indicated (4, 5). Many surgical procedures to stabilize shoulder joints have been described (7, 8, 9, 10), however, where the articular surfaces are deformed or damaged, surgical stabilization is contraindicated (1, 2, 4, 5, 11, 12).

The dog described in this report probably had normal preexisting anatomy of the shoulder joint, however, chronic luxation resulted in irreversible damage to the articular cartilage and soft tissue supportive structures (Figure 1). In light of these changes, arthrodesis or excision arthroplasty appeared to be the only viable surgical options in this case. Successfully accomplished shoulder arthrodesis usually results in remarkably minor functional disability in the majority of patients (5, 11, 12). However, in this case we chose excision arthroplasty for the following reasons: Excision arthroplasty is a less invasive procedure than arthrodesis, causing less tissue damage and requiring a shorter time to perform. We concluded that excision arthroplasty would cause less postoperative distress for this geriatric patient. Long periods of non-weight-bearing may weaken the bones and could predispose to early implant loosening with shoulder arthrodesis. To be successful, shoulder arthrodesis requires postoperative limb immobilization using a spica splint until radiographic signs of bone fusion are noted (5). This period could be quite prolonged in this patient. In contrast to arthrodesis, shoulder arthroplasty does not require any immobilization and enables early use of the operated limb. This, we believed, would significantly simplify and shorten the postoperative care period and contribute to a better quality of life for our patient. Finally, shoulder arthroplasty is technically less demanding than arthrodesis and requires no special instrumentation such as bone plating equipment making the procedure cheaper.

Two techniques for shoulder arthroplasty have been described. Both are reported to be effective in treatment of chronic medial shoulder luxation (1, 2). We opted to use the technique in which both the glenoid cavity and the humeral head were resected. We surmised that resection of the humeral head and interposition of joint capsule and teresminor muscle between the osteotomy surfaces as described

by Bruecker *et al.* (2) are more effective in creating a fibrous pseudo-arthritis and preventing bone on bone friction than resection of only the glenoid cavity (1).

The results of the surgery in this case were similar to those reported previously (1, 2). Pain-free use of leg was achieved in all dogs treated by shoulder arthroplasty regardless of technique. Decreased range of motion, muscle atrophy and occasional favoring of the operated leg were also observed in the treated dogs in both studies (1, 2).

It is well established that the early use of the limb together with physiotherapy are beneficial to a favorable outcome after excision arthroplasty of the coxofemoral joint (13, 14). Unfortunately no definitive research is available to establish the contribution of physiotherapy to outcome of shoulder arthroplasty however it appears from the recovery of this patient that physiotherapy may have a positive effect on the final outcome of shoulder arthroplasty and therefore should be initiated as early as possible. Analgesia during the post-operative period may minimize discomfort and in so doing enhance the effectiveness of physiotherapy.

Body weight of the dog has been found to be a most important factor influencing the functional outcome of femoral head and neck ostectomy (13, 14, 15). Dogs weighing less than 17 kg showed good to excellent results and large dogs demonstrated a less consistent outcome (15). Although most reported dogs treated by shoulder arthroplasty were of small breeds, good results were also achieved in a small number of large-breed dogs (1, 2). Further studies involving analysis of more cases are needed to determine influence of dogs' body weight on the outcome of the procedure.

It was established that results of excision arthroplasty of the coxofemoral joint would be better if extensive muscle atrophy was not present before surgery (14). There was severe muscle atrophy of the affected limb in our case. However, the outcome of excisional arthroplasty in this case was excellent. This suggests that muscle atrophy may not be a limiting factor in shoulder arthroplasty as it is in excision arthroplasty of the coxofemoral joint.

In conclusion, the current case demonstrated that excision arthroplasty of the shoulder can be effective in the treatment of chronic shoulder lesions associated with severe degenerative and atrophic changes and, in certain circumstances, may be preferable to arthrodesis.

ACKNOWLEDGMENTS

Thanks Dr. Itzhak Aizenberg (Department of Radiology, Koret School of Veterinary Medicine, Hebrew University of Jerusalem, Israel) for his assistance in preparation of the figures

REFERENCES

1. Franczusi, D. and Parks, L.J.: Glenoid excision as a treatment in chronic shoulder disabilities: Surgical technique and clinical results. *J. Am. Anim. Hosp. Assoc.* 24:637-643, 1988.
2. Bruecker, K.A. and Piermattei, D.L.: Excision arthroplasty of the canine scapulohumeral joint: report of three cases. *Vet. Comp. Orthop. Trauma.* 3:134-140, 1988.
3. Piermattei, D.L. and Johnson, K.A.: Approach to the Craniolateral Region of the Shoulder Joint. In: *An atlas of approaches to the bones and joints of the dog and cat.* 4th ed., Saunders-Elsevier, Philadelphia, pp. 112-118, 2004.
4. Talcott, K.W. and Vasseur, P.B.: Luxation of the scapulohumeral joint. In: Slatter, D. (Ed.): *Textbook of small animal surgery.* 3rd ed., Saunders-Elsevier, Philadelphia, pp. 1897-1904, 2003.
5. Piermattei, D.L., Flo, G.L. and DeCamp, C.E.: The shoulder joint. In: *Handbook of small animal orthopedics and fracture repair.* 4th ed., Saunders-Elsevier, St. Louis, pp. 262-297, 2006.
6. Vasseur, P.B.: Clinical results of surgical correction of shoulder luxation in dogs. *J. Am. Vet. Med. Assoc.* 182:503-505, 1983.
7. Ball, D.C.: A case of medial luxation of the canine shoulder joint and its surgical correction. *Vet. Rec.* 83:195-196, 1968.
8. Hohn, R.B., Rosen, H., Bohning, R.H. and Brown, S.G.: Surgical stabilization of recurrent shoulder luxations. *Vet. Clin. North. Am.* 1:537-548, 1971.
9. Craig, E., Hohn, R.B. and Anderson, W.D.: Surgical stabilization of traumatic medial shoulder dislocation. *J. Am. Anim. Hosp. Assoc.* 16:93-102, 1980.
10. Prostedny, J.M., Toombs, J.P. and Jakovljevic, S.: Use of polybutester suture to repair medial scapulohumeral luxation in the dog: Three cases. *J. Am. Anim. Hosp. Assoc.* 29:180-183, 1993.
11. Fowler, D.J., Presnell K.R. and Holmberg, D.L.: Scapulohumeral arthrodesis: results in seven dogs. *J. Am. Anim. Hosp. Assoc.* 24:667-672, 1987.
12. Vasseur, P.B.: Arthrodesis for congenital luxation of the shoulder in a dog. *J. Am. Vet. Med. Assoc.* 197:501-503, 1990.
13. Piermattei, D.L., Flo, G.L. and DeCamp, C.E.: The hip joint. In: *Handbook of small animal orthopedics and fracture repair.* 4th ed., Saunders-Elsevier, St. Louis, pp. 501-506, 2006.
14. Roush, J.K.: Surgical therapy of canine hip dysplasia. In: Tobias, K.M. and Johnston, S.A. (Eds.): *Veterinary surgery: small animal.* Elsevier-Saunders, St. Louis, pp. 856-857, 2012.
15. Schulz, K.S. and DeJardin, L.M.: Surgical treatment of canine hip dysplasia. In: Slatter, D. (Ed.): *Textbook of small animal surgery.* 3rd ed., Saunders-Elsevier, Philadelphia, pp. 1897-1904, 2003.