

Clinical Technique: Imaging of the Collateral Caudal Vena Cava Circulation Using Fluoroscopy Guided Non-Selective Contrast Angiography in Ferrets (*Mustela putorius furo*) with Adrenocortical Gland Disorder for a Pre-Surgical Evaluation

Summa, N.,^{1,2} Eshar, D.,^{1,3*} Lee-Chow, B.^{1,4} and Nykamp, S.¹

¹The Ontario Veterinary College Health Sciences Centre, University of Guelph, Guelph, ON N1G 2W1, Canada.

²Departments of Medicine and Epidemiology, School of Veterinary Medicine, University of California, Davis, Davis, CA 95616, USA.

³The Department of Clinical Sciences, College of Veterinary Medicine, Kansas State University, Manhattan, Kansas 66506, USA.

⁴Barbados Primate Research Center, Farley Hill, St. Peter, Barbados.

* **Corresponding Author:** Dr. David Eshar, The Department of Clinical Sciences, College of Veterinary Medicine, Kansas State University, Manhattan, Kansas 66506 United States of America. Tel: 785-532-5690, Fax: 785-532-4309. E-mail: deshar@vet.k-state.edu

ABSTRACT

Angiography is a well-recognized diagnostic tool in human and companion animal medicine and it is beginning to find its application in exotic companion mammals as well. In ferrets with the species' adrenocortical disorder, contrast angiography can be a useful pre-surgical test for right adrenalectomy, by demonstrating the collateral venous flow. Using this technique, fluoroscopy-guided non-selective angiography via the saphenous vein may offer better preoperative evaluation of the patient and allow for a better surgical plan and outcome.

Keywords: Ferret; *Mustela putorius furo*; Adrenocortical Disorder; Fluoroscopy; Non-Selective Angiography

INTRODUCTION

Adrenal Gland Disease ("Ferret Adrenocortical Disorder"), in which excess androgens are produced by an adrenal gland pathology (hyperplasia, adenoma and adenocarcinoma), is one of the most common disorders in neutered ferrets with prevalence up to 70% in the United States (1). Medical management may decrease clinical signs but is not curative and adrenalectomy is considered as the treatment of choice (1-5). Removal of right adrenal gland masses is more challenging than left adrenal gland masses because of the intimate anatomical association between the adrenal gland and the caudal vena cava and frequent invasion of the mass into the vena cava wall and lumen (3-8).

Described surgical techniques include partial ligation of the vena cava and removal of the mass with a portion of the caval wall, resection and anastomosis of the affected segment of the vena cava, or *en bloc* resection of the mass and caudal vena cava with complete ligation (3-8). In humans and dogs, caval ligation between the right renal vein and the liver is associated with a mortality rate of approximately 25% (3, 9). Although renal failure secondary to acute venous hypertension has been described in 30% of ferrets (1, 3), successful caval ligation has also been reported (7). It is hypothesized that those ferrets surviving the caval ligation had some collateral circulation that gradually developed secondary to the increase in venous backflow pressure from the partial occlu-

sion of the vena cava by the neoplastic gland, as described in dogs (10). In one study (10), artificial complete caval occlusion was performed under fluoroscopy in 8 healthy ferrets. The results showed that all ferrets had naturally occurring collateral circulation. However, 2/8 ferrets had developed a profound post-ligation increase in caval pressure (10).

Detailed pre-surgical evaluation of the cranial abdominal collateral venous flow might aid in determining the patients at risk for post-surgical complications. Identification of the collateral venous circulation is often not possible intra-operatively and pre-operative imaging is recommended. B-mode abdominal ultrasonography can demonstrate an adrenal mass and invasion into the caudal vena cava (Figure 1). The use of color flow Doppler (Figure 2) can increase the sensitivity of detection of the collateral blood vessels that are often not evident on B-mode ultrasonography but the overall sensitiv-

ity is still low (11, 12). Angiography of the caudal vena cava has been described in dogs with pheochromocytoma to assess the presence of collateral venous circulation as well as the presence of non-neoplastic thrombi secondary to abnormal flow associated with caval wall invasion by the adrenal gland (13-16).

Angiography can be performed by selective catheterization of a vessel or via a non-selective peripheral injection (16, 17). Selective angiography is preferred for arteriograms as the high concentration of positive contrast medium can be delivered to the vessels of interest and there is no opacification of overlying structures of vessels due to recirculation of contrast medium. However, this is a more invasive procedure than non-selective angiography (16). For venography, non-selective angiography can produce diagnostic images if the images are acquired quickly, before further opacification of the arteries. Fluoroscopy is preferred when performing angiography as the bolus of contrast medium can be observed in real time and rapid frame images can be obtained in the process. Digital subtraction can be used to improve image contrast (18). In this technique, the result is of an image of the opacified vessels with only a ghost image of the rest of the patient (Figure 4 and 5). This technique is highly susceptible to motion artifact so the patient must be sufficiently immobilized (18). Although fluoroscopy is preferred, it is possible to obtain diagnostic angiography images with radiography but multiple injections and subsequent images must be required in order to obtain the image at the correct timing (17, 19).

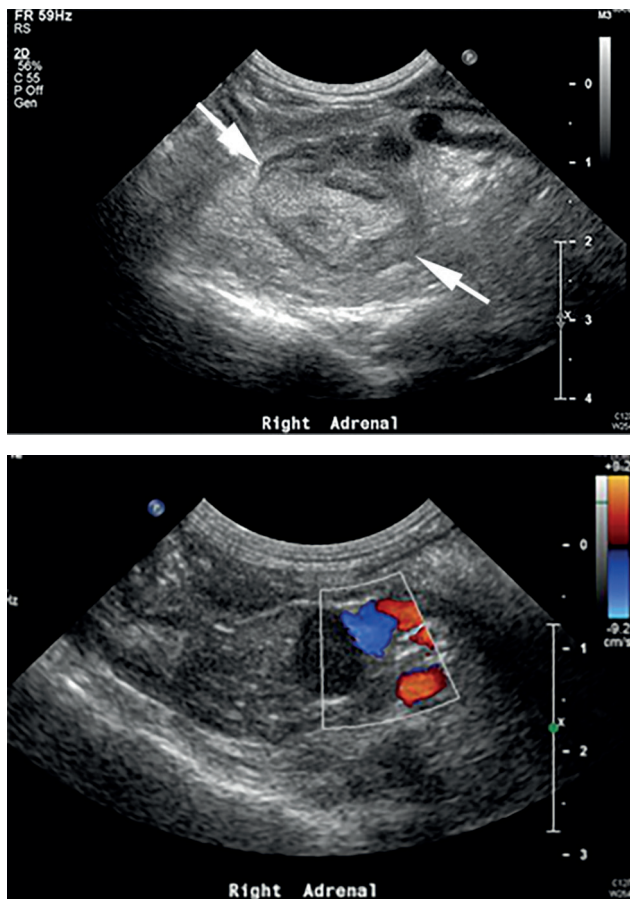


Figure 1 and 2: Ventrolateral sagittal sonogram of the right adrenal gland in a male ferret without (Figure 1) and with color Doppler (Figure 2). The right adrenal gland is increased in size (white arrows) with multi hyperechoic foci and invades the vena cava (Figure 2).

ANATOMICAL FEATURES

Knowledge of the ferret's abdominal vascular anatomy is imperative for proper image evaluation. Variations in blood supply of the right adrenal gland has been reported in ferrets (20). In some ferrets, it was found to be supplied by 3 to 5 blood vessels including branches arising from the right renal artery, the right phrenicoabdominal artery or directly from the aorta (20). The phrenicoabdominal veins drain the adrenal gland into the caudal vena cava (20). The left phrenicoabdominal vein courses ventral and from medial to lateral to its ipsilateral adrenal gland (3, 4, 6). The right adrenolumbar vein courses ventral to the cranial pole of the right adrenal gland (3). Direct vascular connection from the right adrenal gland to the caudal vena cava may be present (5).

Vessels draining into the caudal vena cava from caudal to cranial include the common iliac veins, lumbar veins, deep circumflex iliac veins, right testicular or right ovarian vein, renal veins, phrenicoabdominal veins, hepatic veins and phrenic veins (10, 20). Naturally occurring collateral veins in ferrets have been described branching from the caudal vena cava before the right adrenal gland through the vertebral venous sinus to the azygous vein and back to the cranial vena cava (10). In dogs, after 3 weeks of occlusion of the caudal vena cava, multiple and tortuous collateral veins were found arising from the renal capsules, vena cava and iliac veins to the lumbar veins, vertebral veins and azygous vein (9).

This report describes in detail the technique to illustrate collateral venous flow using fluoroscopy-guided non-selective angiography using a saphenous vein as a pre-surgical imaging test for right adrenalectomy in ferrets with adrenocortical disorder.

STEP-BY-STEP GUIDE TO PERFORM CONTRAST ANGIOGRAPHY USING FLUOROSCOPY IN A FERRET

1. Immobilize the patient using standard sedation or anesthesia techniques. For example, midazolam (0.25mg/kg SQ, IM or IV) and butorphanol (0.25 mg/kg SQ, IM) can be used for proper and safe sedation.
2. Clip the hair over the lateral saphenous vein and prepare the site aseptically. Place an intravenous catheter in the lateral saphenous vein. Use the largest gauge catheter that can be placed to facilitate rapid bolus injection. Ensure that the catheter is patent by administering a small volume of heparinized saline. Attach a PRN adapter to the catheter.
3. Calculate the maximum volume of iodinated contrast medium that can be administered (1200 mg iodine/kg).
4. Prepare a syringe of iodinated contrast medium with 150 mg iodine in a total volume of 1-2 ml (this will facilitate repeating the injection several times without exceeding the maximum recommended dose of iodine). The iodinated contrast medium can be diluted with normal saline.
5. Place the patient in lateral recumbency (Figure 3). Inject a 1-2 ml bolus of diluted iodinated contrast medium via the preplaced catheter and obtain images at 3-4 frames per second (fluoroscopy, Figure 4) or while being injected the

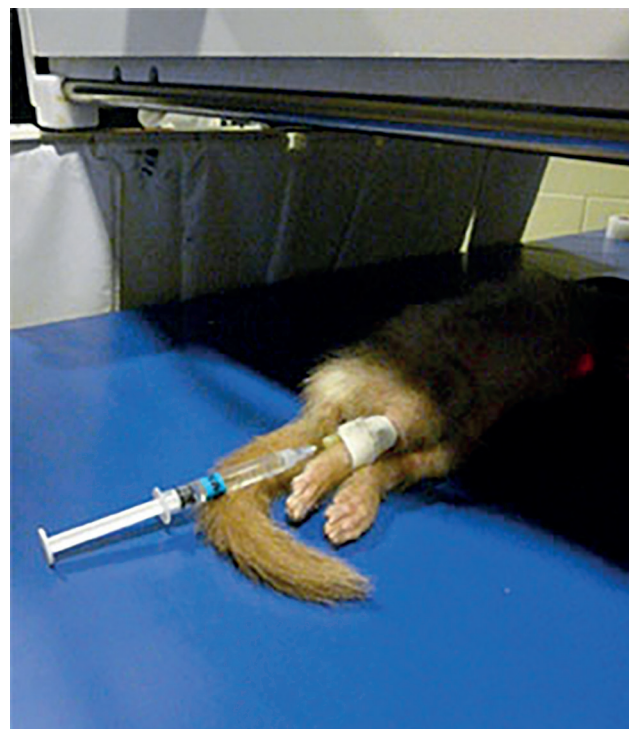

Figure 3: Injection of a bolus of diluted iodinated contrast medium via an intravenous catheter in the lateral saphenous vein in a male ferret in lateral recumbency prior to fluoroscopy.

- last ½ ml of the contrast medium. Repeat this procedure with the patient in dorsal recumbency (Figure 5).
6. Allow the ferret to recover while providing intravenous fluid support.

USEFUL TIPS

Placing an intravenous catheter can be challenging, as ferrets' skin can be relatively thick. A helpful practice is to puncture the skin with a 20- or 22-gauge needle, avoiding the vein and then introducing the catheter using the preformed opening in the skin.

For the injection of the diluted contrast solution, a 23-gauge butterfly catheter or a T-port extension set can be useful to prevent any displacement of the ferret's body.

SUMMARY

Contrast angiography in ferrets may provide useful details of the vasculature of the right adrenal gland and the caudal vena cava in ferrets with right adrenal gland pathology and

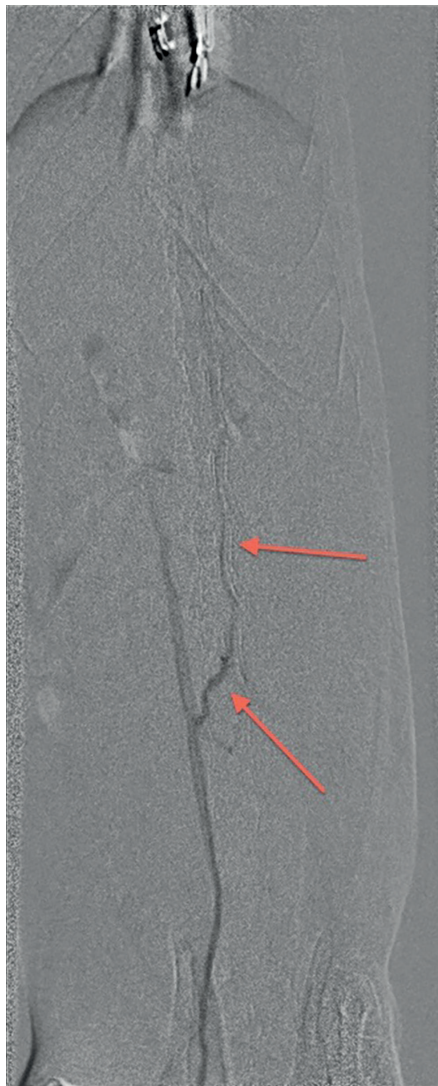
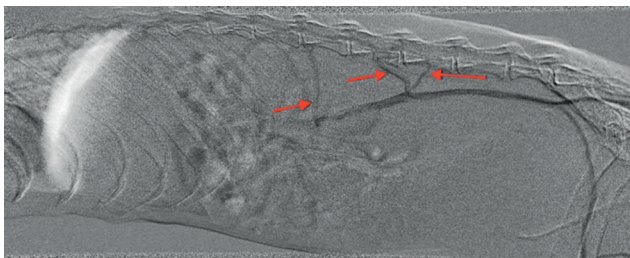


Figure 4 and 5: Lateral (Figure 4) and ventrodorsal (Figure 5) views of a non-selective venography in a male ferret with right adrenal gland disease. Iopamidol (300 mgI/ml, Isovue-M® 200, Bracco Diagnostics Inc., Princeton, NJ, USA) diluted 1:1 with saline was injected into the right saphenous vein via a peripheral catheter. Images were obtained using digital subtraction. The images revealed an opacification of the iliac veins and caudal vena cava to the level of the renal veins. There is no opacification of the caudal vena cava cranial to the renal veins. There is an opacification of three intervertebral veins and ventral internal vertebral plexus (red arrows point to the collateral vessels).

caval involvement. Regarding the potential risks associated with right adrenalectomy, this imaging technique allows for a better preoperative evaluation and a better adaptive surgical plan, thus increasing the likelihood of obtaining a more favorable outcome for this procedure.

REFERENCES

- Rosenthal, K.L. and Wyre, N.R.: Endocrine diseases. In: Quesenberry, K.E. and Carpenter, J.W. (Eds): *Ferrets, Rabbits, and Rodents. Clinical Medicine and Surgery* (ed 3). Elsevier Saunders, St. Louis, Missouri, pp. 86-102, 2012.
- Lewington, J.H.: Endocrine diseases. In: Lewington, J.H. (Ed.): *Ferret husbandry, medicine and surgery* (ed 2). Saunders Elsevier, Philadelphia, Pennsylvania, pp. 346-379, 2007.
- Beeber, N.L.: Surgical Management of Adrenal Tumors and Insulinomas in Ferrets. *J. Exot. Pet Med.* 20: 206-216, 2011.
- Bennett, A. and Pye, G.W.: General surgery. In: Lewington J.H. (Ed.): *Ferret Husbandry, Medicine and Surgery* (ed 2). Saunders Elsevier, Philadelphia, Pennsylvania, pp. 430-439, 2007.
- Capello, V.: Ferrets: common surgical procedures. In: Keeble E. and Meredith A. (Eds.): *BSAVA Manual of Rodents and Ferrets*. BSAVA British Small Animal Veterinary Association, Gloucester, UK, pp. 254-258, 2009.
- Lightfoot, T., Rubinstein, J., Aiken, S. and Ludwig, L.: Soft tissue surgery. In: Quesenberry, K.E. and Carpenter, J.W. (Eds.): *Ferrets, Rabbits, and Rodents. Clinical Medicine and Surgery* (ed 3). Elsevier Saunders, St. Louis, Missouri, pp. 141-156, 2012.
- Driggers, T.: A novel surgery for right-sided adrenalectomies in ferrets (*Mustela putorius furo*). Proceedings of the 29th annual meeting of the Association of Avian Veterinarians and the Association of Exotic Mammal Veterinarians, Savannah, GA, USA, pp. 107-109, 2008.
- Weiss, C.A., Williams, B.H., Scott, J.B. and Scott, M.W.: Surgical treatment and long-term outcome of ferrets with bilateral adrenal tumors or adrenal hyperplasia: 56 cases (1994-1997). *J. Am. Vet. Med. Assoc.* 215: 820-823, 1999.
- Peacock, J.T., Fossum T.W., Bahr, A.M., Miller, M.W. and Edwards, J.F.: Evaluation of gradual occlusion of the caudal vena cava in clinically normal dogs. *Am. J. Vet. Res.* 64: 1347-1353, 2003.
- Bennett, R.A., Laraio, L., Weisse C., Zingerberger, A., Rosenthal, K.L., Johnston, M. and Campbell, V.: Collateral circulation during caval occlusion in ferrets. Proceedings of the 29th annual meeting of the Association of Avian Veterinarians and the Association of Exotic Mammal Veterinarians, Savannah, GA, p 105, 2008.
- Kuijten, A.M., Schoemaker, N.J. and Voorhout G.: Ultrasonographic visualization of the adrenal glands of healthy ferrets and ferrets with hyperadrenocorticism. *J. Am. Anim. Hosp. Assoc.* 43: 78-84, 2007.
- Neuwirth, L., Collins, B., Calderwood-Mays, M. and Tran, T.: Adrenal ultrasonography correlated with histopathology in ferrets. *Vet. Radiol. Ultrasound.* 38: 69-74, 1997.
- Gilson, S.D., Withrow S.J. and Orton E.C.: Surgical treatment of

- pheochromocytoma: technique, complications, and results in six dogs. *Vet. Surg.* 23: 195-200, 1994.
14. Gilson, S.D., Withrow S.J., Wheeler S.L. Twsdt, D.C.: Pheochromocytoma in 50 dogs. *J. Vet. Intern. Med.* 8: 228-232, 1994.
 15. Rosenstein, D.S.: Diagnostic imaging in canine pheochromocytoma. *Vet. Radiol. Ultrasound.* 41: 499-506, 2000.
 16. Farrow, C.S.: Angiography and Angiocardiography. In: Farrow, C.S. (Ed.): *Veterinary Diagnostic Imaging : the Dog and Cat*, Vol. 1. Mosby, St. Louis, Missouri, pp. 496-498, 2003.
 17. Wallack, S.T.: Angiography - Dog and Cat. In: Wallack, S.T. (Ed.): *The Handbook of Veterinary Contrast Radiography*. San Diego Veterinary Imaging, Solana Beach, California, pp. 31-35, 2003.
 18. Meaney, T.F., Weinstein, M.A., Buonocore, E., Pavlicek, W., Borkowski, G.P., Gallagher, J.H., Sufka, B. and MacIntyre, W.J.: Digital Subtraction Angiography of the Human Cardiovascular-System. *Am. J. Roentgenol.* 135: 1153-1160, 1980.
 19. Fox, P.R. and Bond B.R.: Nonselective and selective angiocardiography. *Vet. Clin. North Am. Small Anim. Pract.* 13: 259-272, 1983.
 20. Holmes, R.L.: The adrenal glands of the ferret, *Mustela putorius*. *J. Anat.* 95: 325-336, 1961.