

Clinical Toxoplasmosis in Two Meerkats (*Suricata suricatta*) in Israel

Margalit Levi, M.,^{1,2} Bueller-Rosenzweig, A.,³ Horowitz, I.,³ Bouznach, A.,⁴ Edery, N.,⁴ Savitsky, I.,¹ Fleiderovitz, L.,¹ Baneth, G.² and Mazuz, M.L.^{1*}

¹Division of Parasitology, Kimron Veterinary Institute, P.O.B. 12, Bet Dagan 50250, Israel.

²Koret School of Veterinary Medicine, The Robert H. Smith Faculty of Agriculture, Food and Environment, The Hebrew University of Jerusalem, P.O.B. 12, Rehovot 76100, Israel.

³Zoological Center Tel Aviv – Ramat Gan-Safari, 1 Sderot Hatzvi, Ramat Gan, Israel.

⁴Division of Pathology, Kimron Veterinary Institute, P.O.B. 12, Bet Dagan 50250, Israel.

* **Corresponding author:** Dr. Monica L. Mazuz, Division of Parasitology, Kimron Veterinary Institute, 50250 Bet Dagan, Israel. Tel.: +972 3 2690; Fax: +972 3 2642. Email: monica@int.gov.il

ABSTRACT

This case study describes the diagnosis of clinical toxoplasmosis in two meerkats (*Suricata suricatta*) from the Safari-zoological center, Tel Aviv-Ramat Gan. The meerkats showed neurological signs such as incoordination, lethargia, anorexia and one of them died. Gross pathology revealed diffuse congestion and hyperemia of all lung lobes and diffuse bright coloration of the liver parenchyma. On histopathology, the myocardium, cerebrum, cerebral meninges and lungs contained multiple intralesional parasitic cysts consistent with *Toxoplasma gondii*. The diagnosis was confirmed by PCR and sequence analysis. The second meerkat was diagnosed early with *Toxoplasma gondii* by serology, was treated and was fully recovered. This is the first report of toxoplasmosis in Meerkats in Israel. Possible sources of infection would include ingestion of tissues from infected intermediate hosts, hunting of feral infected animals, contamination of the zoo environment with oocysts and recrudescence of a chronic infection by unknown causes. It appears that meerkats are highly susceptible to *T. gondii* infection, however early diagnosis of meerkat presenting with neurological signs and efficient treatment can result in full recovery.

Keywords: Meerkats; *Suricata suricatta*; *Toxoplasma gondii*; PCR; Treatment.

INTRODUCTION

Toxoplasma gondii is an obligate intracellular protozoan parasite which belongs to the phylum Apicomplexa, family Sarcocystidae (1,2). *Toxoplasma* can infect and replicate in nucleated mammalian or avian cells, thus having a broad range of intermediate hosts. The life cycle of *T. gondii* includes three main stages - oocysts excreted in the feces of the definitive host, tachyzoites characterized by rapid multiplication, and bradyzoites with slow multiplication. Both latter forms are found in the intermediary host and all these life stages are infectious. The definitive hosts of *T. gondii* include members from the Felidae family such as the domestic cat (*Felis catus*), Iriomate cat (*Prionailurus*

bengalensis iriomotensis), lion (*Panthera leo*) and Ocelot (*Felis pardalis*) (3). Almost any warm-blooded animal can act as an intermediate host (1). Infection occurs orally by ingestion of either sporulated oocysts or infected raw meat containing bradyzoites or tachyzoites. Clinical signs in the intermediate host are frequently absent but the disease can be severe and even fatal in immunosuppressed individuals, such as human HIV patients, or some animal species such as meerkats (4, 5).

Meerkats (*Suricata suricatta*) are small carnivores that belong to the family Viverridae, subfamily Herpestinae. Meerkats naturally live in the hot, dry plains of South Africa and are highly social, living in colonies of about 25 or more animals (6, 7). The main natural food of meerkats consists

of insects and other small invertebrates which are dug up with the animal's long claws of the forefeet. Larger prey such as mice, small birds, lizards or snakes can also be hunted if the opportunity occurs (6). In captivity, meerkats become omnivorous and are frequently fed on raw meat (3). Raw meat may contain pathogens such as viruses, bacteria and parasites like *T. gondii*. In the Safari Zoological Center of Tel Aviv - Ramat Gan, the meerkats are fed with frozen meat of laboratory mice, fruits and meal worms, *Tenebrio molitor*.

Severe, disseminated toxoplasmosis in meerkats had been reported previously. At an outbreak in 2007 in Argentina, six meerkats showed clinical signs of depression, hypothermia and dyspnea and one animal also had ataxia. All meerkats died within five days (4). In 1994, in Barcelona, Spain, five meerkats died showing clinical signs of respiratory insufficiency and incoordination (3). Necropsy in both outbreaks revealed interstitial pneumonia and focal necrosis in the liver, spleen and mesenteric lymph nodes (3, 4). These reports suggest that meerkats might be highly susceptible to toxoplasmosis.

In this report we describe a case of clinical toxoplasmosis in two meerkats from the Safari park in Ramat-Gan, Israel. Clinical signs included anorexia, incoordination, polyuria and polydipsia, and lethargy. One of the meerkats died and was submitted to the Kimron Veterinary Institute (KVI) for necropsy the other one was diagnosed, treated, survived and returned to the zoo. Diagnosis was based on the observation of Apicomplexa-like cysts in histological examination and confirmation of infection by *T. gondii* by serology and PCR.

MATERIALS AND METHODS

Case description

Case number 1:

On January 14th 2016, a 2 years old female meerkat from the Zoological Center Tel Aviv - Ramat Gan-Safari, Israel, was found lying on its back and lethargic. On physical examination at the zoo clinic, the meerkat was bright, alert and responsive (BAR) and showed neurological signs such as incoordination. The meerkat was sedated with 0.2 mg/kg Butorphanol (Butomidol, Richter Pharma, wels, Austria) and 0.2 mg/kg Midazolam (Rafa Laboratories Ltd., Jerusalem, Israel) and treated with supportive treatment which included 0.2 mg/kg of the non-steroidal anti-inflammatory drug meloxicam (Norbrook Laboratories, LTD., North Ireland, UK) SC, 25 mg/kg BID of the antibiotic cephalosporin

(Labesfal Laboratorios Almiro S.A. Fresenius Kabi Group, Portugal) and intravenous fluids (lactated ringer's, Teva medical Ltd., Ashdod, Israel) with 5% dextrose for five days. The meerkat seemed to start recovering following this treatment. However, on January 19th, the meerkat was quite, alert and responsive (QAR), with general deterioration as it developed polyuria and polydipsia and anorexia. The meerkat was treated with antibiotics: 15 mg/kg metronidazole (B. Braun, Melsungen, Germany) SIV BID and 20 mg/kg ampicillin (penibrin, Sandoz GmbH, Austria) (10%) BID, and 0.2 mg/kg meloxicam SC.

Blood tests taken showed normal cell counts with polychromasia and mild toxicity with the presence of Döhle bodies in neutrophils. The serum biochemistry results (Table 1) showed hypocholesterolemia, hypoalbuminemia, hypoproteinemia, hyponatremia, hypokalemia, hypocalcemia, uremia and an increase in bile and liver enzyme activities. On January 21th, the meerkat severely deteriorated, it was hypothermic, having a body temperature of 34.8°C (normal meerkats body temperature 36.3 +/- 0.6°C at night and 38.3 +/- 0.5°C during the day), lethargic and it died on January 22th. The dead animal was sent to the Kimron Veterinary Institute for necropsy.

Table 1: The meerkat's (case no. 1) serum biochemistry results:

	Result	Normal range minimum	Normal range maximum
Cholesterol (mg/dL)	119	159	939
Albumin (g/dL)	2	2.5	4.3
Total protein (g/dL)	4.3	5.6	8.5
Na ⁺ (mmol/L)	131	140	160
K ⁺ (mmol/L)	3.3	3.5	5.2
Ca ²⁺ (mg/dL)	6.4	8	11.1
Urea (mg/dL)	167	25.7	124.1
ALP (u/L)	143	6	78
AST (u/L)	275	32	169
LDH (u/L)	4055	280	904

Reference values were taken from Physiological data reference values, 2009. International species inventory system.

Case number 2:

On April 9th 2016, another 4 months old female meerkat was found lethargic and unresponsive. According to her caretaker, two hours prior to that, it was normal. On physical examination there was nystagmus with slow phase to the right, head tilt to the right, weak pupillary light response (PLR) in both eyes and proprioceptive deficit in left hind foot with no obvi-

ous signs of trauma. The meerkat was given supportive treatment, including intravenous fluids (Lactated Ringer's, Teva medical Ltd., Ashdod, Israel), 1 gr/kg mannitol SIV (Baxter Healthcare Ltd., Caxton Way, Thetford, Norfolk, UK) 0.6 ml complex B vitamins (Farto, Bologna, Italy) SC, 0.05 ml Sel-E vitamin (V.M.D. nv/sa Hoge Mauw 900, B-2370 Arendonk, Belgium) SC, 0.2 mg/kg meloxicam (Norbrook Laboratories, LTD., North Ireland, UK.) and oxygen. The supportive treatment did not improve its general condition. A suspicion of toxoplasmosis arose and treatment with 0.6 ml sulfamethoxazole and trimethoprim (TMS, Norbrook Laboratories. Ltd., North Ireland, UK.) SC SID and 12.5 mg/kg clindamycin (Vetmarket, Shoham, Israel) BID were administered and within six days the meerkat recovered and was returned to the zoo a week after its initial deterioration. Serum and blood with EDTA were sent to the KVI for *T. gondii* serology and PCR.

Necropsy and histopathological analysis

The dead female meerkat that was submitted for necropsy at the KVI (case no. 1) weighed 0.5kg. Tissue samples from the lungs, heart, intestine, liver, spleen, pancreas, kidney, thyroid, brain and several lymph nodes were taken in 10% formaldehyde, embedded in paraffin wax, sectioned at 3µm and stained with hematoxylin-eosin.

DNA extraction and PCR

DNA was extracted from a fresh brain sample of case number 1 with a commercial DNA extraction kit-DNeasy® Tissue Kit Qiagen, Hildenberg, Germany, according to the manufacturer's instructions.

PCR amplification targeting *T. gondii* was performed according to Homan *et al.*, 2000 (8) with primers Tox4 (CGCTGCAGGGAGGAAGACGAAAGTTG) and Tox5 (CGCTGCAGACACAGTGCATCTGG AT T). These primers amplify a 529 base pairs fragment of the *B1* gene (GenBank accession no. AF146527). The PCR was performed in a mixture containing 5 µl of DNA extracted plus 20 µl of mixture of 1.0 mM of each primer, 200 mM dNTP manufactured by Invitrogen, Life Technologies, 5791 Van Allen Way, California, USA, 2.5 µl buffer, 13.25 µl pure water, 0.25 µl Taq DNA polymerase manufactured by Invitrogen, Life Technologies, USA. The amplification was done over 35 cycles in thermocycler, using the following conditions:

3 min at 95°C for denaturation, followed by 34 cycles of 10 seconds at 98°C for denaturation, 1 minute at 60°C for annealing, and 1 minute at 72°C for extension, cycle 35 was followed by a final extension of 5 minutes at 72°C. A second, nested PCR targeting *Neospora caninum* was performed according to Fish *et al.*, 2007 (9). In brief the primers were based on published sequences of the *Nc5* gene of the NC1 isolate (GenBank accession no. X84238). Positive and negative controls were included. In all PCR test performed. The amplified products were visualized in a 2% agarose gel stained with EtBr.

Serological tests

Serological examination for antibodies against *T. gondii* and *N. caninum* was performed on serum from case number 2 by the indirect fluorescent antibody test (IFAT) according to Shkap *et al.*, 2002 (10). *T. gondii* and *N. caninum* were collected from Vero cells at about 80% infection. The free released parasites were centrifuged at 1000 × g for 20 min at 4°C, and the pellet washed twice with phosphate-buffered saline (PBS), pH 7.2. To separate parasites from the host cells, the pellet was resuspended in PBS and subjected to a Whatman CF-11 column purification. The cell-free parasites were washed twice by centrifugation with PBS and fixed in 0.2% formaldehyde on ice for 30 min. After three additional washes in PBS, the parasites were suspended in PBS at a concentration of 2 × 10⁶ ml⁻¹. Drops of the suspension were dispersed onto slides, dried and fixed in cold acetone. The antigen slides were stored at -70°C (10). Serial dilutions starting from 1:64 for *T. gondii* and 1:200 for *N. caninum* were performed.

In the absence of specific secondary labeled anti-meerkat serum, anti-mouse, anti-dog and anti-cat conjugates (Sigma, Israel) were used to detect antibodies in serum. The endpoint titer was taken as the highest serum dilution at which the whole parasites showed bright fluorescence (10).

RESULTS

Gross pathology and histopathology (case number 1)

Post mortem findings included serosanguinous fluids (5- 10 ml) in the thoracic cavity, diffuse congestion and hyperemia of all lung lobes, and diffuse bright coloration of the liver parenchyma. No gross pathological signs were observed in the brain and other organs. By histopathology, the myocar-

dium and lungs contained multiple intralésional parasitic cysts measuring approximately 30µm in diameter, and free bradyzoites of apicomplexan protozoa spp. consistent with *T. gondii* (Figures 1-2). Multifocal, mild perivascular lymphocytic infiltration and gliosis were found in the cerebrum and cerebral meninges, associated with intralésional protozoal parasites consistent with *T. gondii* (Figures 3-4).

PCR of tissues from case number 1

Amplification of the expected 529 bp target fragment by the *T. gondii* specific primer pair tox4 and tox5 was demonstrated

in fresh brain samples from the meerkat. The nPCR targeting *N. caninum* was negative. Sequencing of the amplified DNA fragment and BLAST search (NCBI) showed query cover of 100% with identity of 99% (397/402) with a *T. gondii* repetitive DNA sequence (GenBank accession gb|KF872166) (Fig. 5).

Serology of case number 2

Positive reaction with *T. Gondii* antigen was observed by IFAT with an end-point titer of 1:256 with the dog, mice and cat secondary antibodies. The IFAT results are summarized in table 2.

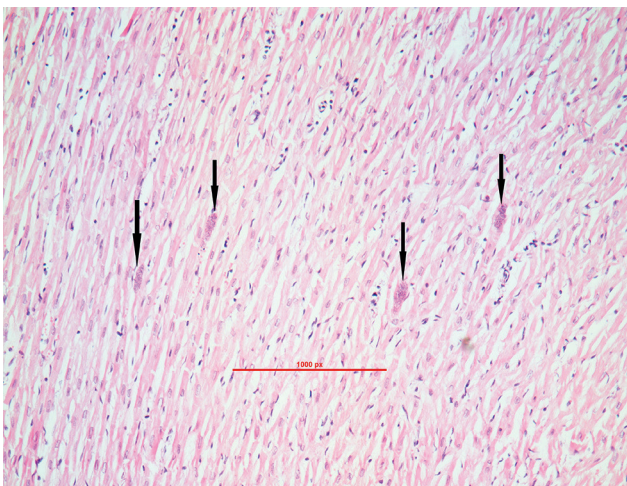


Figure 1: Histopathology of the myocardium from the meerkat. Four tissue cysts containing bradyzoites are shown within the muscle fibers (arrows). X100. HE.

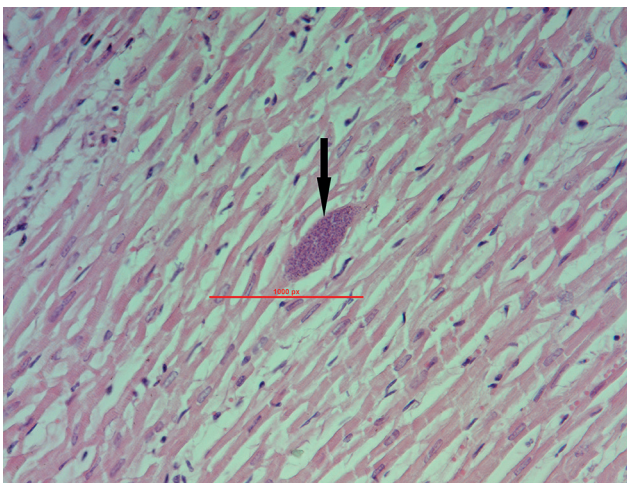


Figure 2: Histopathology of the myocardium from the meerkat. A tissue cyst containing bradyzoites is shown within the muscle fibers (arrow). X200. HE.

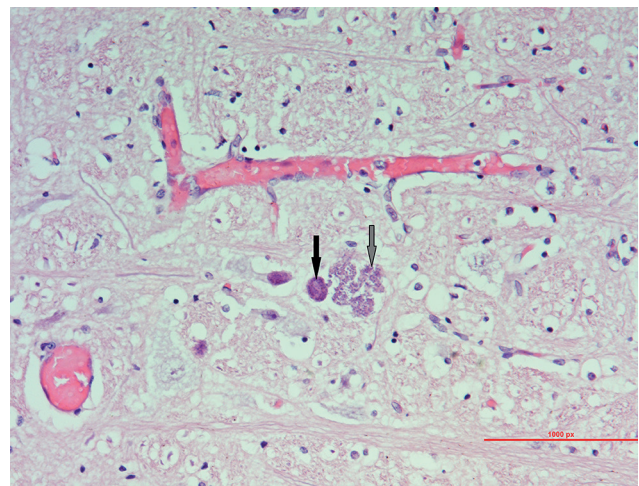


Figure 3: Histopathology of the brain stem from the meerkat. Two tissue cysts can be seen in the parenchyma. One cyst is intact (arrow), and the other broke down with bradyzoites spreading through the tissue (gray arrow). X200. HE.

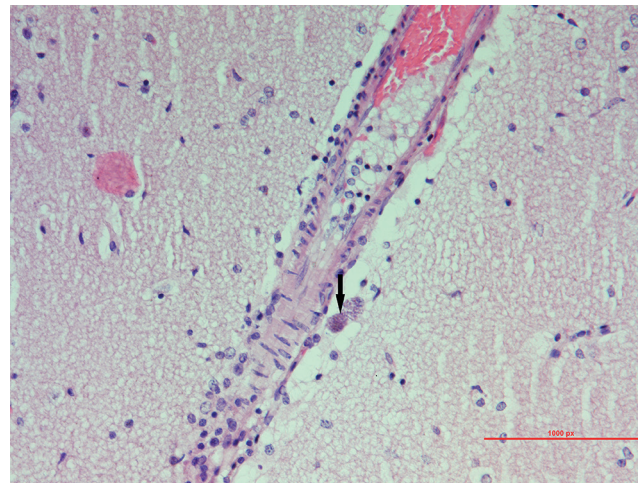


Figure 4: Histopathology of the cerebrum from the meerkat. A tissue cyst can be seen in the Virchow-Robin space (arrow). X200. HE.

Meerkats 1	ACGAGGAAAGCGTCTCATCTAGATCGCATTCCGGTGTCTCTTTCCACCTCCTGGA	60
KF872166 35	ACGAGGAAAGCGTCTCATCTAGATCGCATTCCGGTGTCTCTTTCCACCTCAGGA	94
Meerkats 61	AAAGCAACCTAGCCGAAACATCTTCTCCCTCTCCGACTCTCGTCGCTTCCAACCACGC	120
KF872166 95	AAAGCAGCCAAGCCGAAACATCTTCTCCCTCTCCGACTCTCGTCGCTTCCAACCACGC	154
Meerkats 121	CACCCCTCATCTCACCCTCGCCTTTCATCTACAGTCTGATATCTCTCTCCAAGACGG	180
KF872166 155	CACCCCTCATCTCACCCTCGCCTTTCATCTACAGTCTGATATCTCTCTCCAAGACGG	214
Meerkats 181	CTGGAGGAGCGGCATCGCGTCTGTAGTCCCCTTCGACTTCTGTCCCTTCTGTGGCTCAA	240
KF872166 215	CTGGAGGAGCGGCATCGCGTCTGTAGTCCCCTTCGACTTCTGTCCCTTCTGTGGCTCAA	274
Meerkats 241	GCACAGGCGAGCTCGCCTGTGaaaaacaaaaaaaaaatcaaaaaaaaaaaCGCCCTTCG	300
KF872166 275	GCACAGGCGAGCTCGCCTGTGAAAAAACAAAAAAATCAAAAAAAACCGCCCTTCG	334
Meerkats 301	GCTCCGGGGTCTCTTCCCACAAAGGCAGCTGGGCCGGAGTcaaaaaaaaaaaaaatcaa	360
KF872166 335	GCTCCGGGGTCTCTTCCCACAAAGGCAGCTGGGCCGGAGTCAAAAAAACAAAAATCAA	394
Meerkats 361	aaaaaaaaaaaaaaaaaaaaaaaaaaaaaaaaCATTTTTGTCTT	402
KF872166 395	AAAAACAAAAAAACAAAAAAACATTTTTCTTCTT	436

Figure 5: Sequence alignment of the meerkat sample with a previously published *T. gondii* sequencegb|KF872166.

Table 2: IFAT results to *Toxoplasma gondii* and *Neospora caninum* from the serum of case number 2.

	Antibody Titer according to secondary antibody used (end point)		
	Anti dog	Anti mice	Anti cat
<i>Toxoplasma gondii</i>	1:256	1:256	1:256
<i>Neospora caninum</i>	Negative	Negative	Negative

DISCUSSION

In this report, to the best knowledge of the authors, *T. gondii* is reported here for the first time in meerkats in Israel. The cases reported present fatal disease in a captive meerkat in the central area of Israel associated with *T. gondii* infection and a second case of serologically-confirmed infection where early treatment led to full recovery. *T. gondii* infection in meerkats causing fatal disease had been previously reported in captive animals in Spain and Argentina (3, 4).

In case number 1, which died after presenting neurological signs, blood tests revealed neutrophil toxicity probably associated with the inflammatory response to *T. gondii* infection, and liver enzyme abnormalities possibly related to infection of the liver by *T. gondii* as found by necropsy. The necropsy and histopathology findings confirmed the

suspicion of a parasitic disease. Multiple parasitic cysts were seen in the lungs, heart and brain, and histopathology revealed protozoan-like forms. Molecular investigation by PCR showed a positive and specific PCR result for *T. gondii* confirmed by sequence analysis.

N. caninum, a related apicomplexan parasite was also tested by PCR which found negative, excluding the possibility of this infection. Serum collected from case number 2 was positive for *T. gondii* by IFAT. As no specific secondary antibodies to meerkats are commercially available, serological tests were performed using secondary antibodies for cats, dogs, and mice. A positive result was found using all three conjugates. The negative IFAT for *N. caninum* performed in the same way confirmed the specificity of the results obtained for *T. gondii*, showing that there was no cross-reaction between the two parasites even when a non-species specific secondary antibody was used. A confirmatory diagnosis of *T. gondii* in a meerkat using non-meerkat anti-serum was previously reported; the results presented specific reactivity to *T. gondii* without cross-reaction to *N. caninum* by immunohistochemistry (3).

Toxoplasmosis can cause an acute clinical disease, usually associated with ingestion of infected material. Clinical

disease in chronically-infected animals can occur by reactivation of latent tissue cysts. The reactivation of chronic infection can occur due to immunodeficiency or concurrent infection with an additional disease agent (5) such as murine leukemia virus in mice (3). Recrudescence of the disease in chronically-infected animals is usually characterized by encephalitis.

Several species of viverrines to which meerkats belong, have been identified as being susceptible to Canine Distemper Virus (CDV) (11, 12). Therefore CDV can be considered as a differential diagnosis in sick meerkats presenting neurological signs (3). It was suggested that CDV infection might act as a trigger for clinical toxoplasmosis in meerkats (3). In the case reported here, the meerkats were neither vaccinated nor tested for CDV, however it appears that a viral disease was not related to this case as no inclusion bodies were observed in histopathology of case number 1 and case number 2 recovered which is not expected in CDV infection.

The possible sources of *T. gondii* infection for the meerkats in the current cases could not be traced. Possible sources of infection would include ingestion of tissues from infected intermediate hosts. Feeding with raw meat from infected animals or contaminated with oocysts. Another possibility is hunting of feral infected mammals such as rodents or infected birds. The latter is reasonable since it would cause a sporadic infection as documented here, rather than an epidemic that would be expected if all the meerkats housed together were fed on *T. gondii* infected or contaminated food. Contamination of the zoo environment or water supply with oocysts could also not be excluded as the meerkat's cage is not completely sealed and stray or feral cats could enter it.

Another possibility not previously described in meerkats, could be that the acute clinical disease resulting from the recrudescence of a chronic infection by some stress or other unknown cause.

The report presented here describes clinical toxoplasmosis in two meerkats in Israel. Due to the severe clinical signs

observed in these cases and in others reports, it appears that meerkats are highly susceptible to *T. gondii* infection. However as observed here, the awareness of possible toxoplasmosis and early diagnosis of the sick meerkats presenting neurological signs permit efficient treatment which led to full recovery of one of the cases.

REFERENCES

1. Black, M.W. and Boothroyd, J.: Lytic Cycle of *Toxoplasma gondii*. Mol. Biol. Rev. 64: 607–623, 2000.
2. <https://msu.edu/course/zol/316/tgontax.htm>
3. Juan-Sallés, C., Prats, N., López, S., Domingo, M., Marco, A.J. and Morán, J.F.: Epizootic Disseminated Toxoplasmosis in Captive Slender-tailed Meerkats (*Suricata suricatta*). Vet. Pathol. 34: 1–7, 1997.
4. Basso, W., Moré, G., Quiroga, M.A., Pardini, L., Bacigalupe, D., Venturini, L., Valenzuela, M.C., Balducci, D., Maksimov, P., Schares, G. and Venturini, M.C.: Isolation and molecular characterization of *Toxoplasma gondii* from captive slender-tailed meerkats (*Suricata suricatta*) with fatal toxoplasmosis in Argentina. Vet. Parasitol. 161: 201–206, 2009.
5. Grant, I.H., Gold, J.W.M., Rosenblum, M., Niedzwiecki, D. and Armstrong, D.: *Toxoplasma gondii* serology in HIV-infected patients: the development of central nervous system toxoplasmosis in AIDS. Aids. 4.6: 519–522, 1990.
6. Ewer, R. F.: The behaviour of the meerkat, *Suricata suricatta* (Schreber). Zeitschrift für Tierpsychologie. 20.5:570–607, 1963.
7. Wemmer, C. and Fleming, M.J.: Ontogeny of playful contact in a social mongoose, the meerkat, *Suricata suricatta*. Amer. Zool. 14.1: 415–426, 1974.
8. Homan, W.L., Vercammen, M., De Braekeleer, J. and Verschuere, H.: Identification of a 200- to 300-fold repetitive 529 bp DNA fragment in *Toxoplasma gondii*, and its use for diagnostic and quantitative PCR. Int. J. Parasitol. 30: 69–75, 2000.
9. Fish, L., Mazuz, M., Molad T., Savitsky, I. and Shkap, V.: Isolation of *Neospora caninum* from dairy zero grazing cattle in Israel. Vet. Parasitol. 149: 167–171, 2007.
10. Shkap, V., Reske, A., Pipano, E., Fish, L., and Baszler, T.: Immunological relationship between *Neospora caninum* and *Besnoitia besnoiti*. Vet. Parasitol. 106.1: 35–43, 2002.
11. Machilda, N., Izumisawa, N., Nakamura, T. and Kiryu, K.: Canine distemper virus infection in a masked palm civet (*Paguma larvata*). J. Comp. Pathol. 107: 439–443, 1992.
12. Appel, M. J. and Summers, B. A.: Pathogenicity of morbilliviruses for terrestrial carnivores. Vet. Microbiol. 44.2: 187–191, 1995.