

A Case Report of a Spontaneous Feline Metastasizing Uterine Fibrosarcoma in a Himalayan Cat

Waner, T.,^{1*} Tal, S.,^{2#} Edery, N.³ and Perl, S.³

¹ Rehovot Veterinary Clinic, 9 Meginay Hagalil Street, Rehovot, 76200 Israel

² Arlozorov Animal Hospital, 52 Arlozorov Street, Ramat Gan, 52481 Israel

³ Division of Pathology, Kimron Veterinary Institute Bet Dagan, Israel.

* **Corresponding author:** Dr. Trevor Waner, B.V.Sc., Ph.D., Dipl ECLAM. Rehovot Veterinary Clinic, 9 Meginay Hagalil Street, Rehovot, 76200, Israel.
Email: wanertnt@gmail.com

Both authors contributed equally.

ABSTRACT

The case report describes a highly malignant fibrosarcoma in a 15 year old Himalayan female cat presented to the clinic with a history of uterine hemorrhage and body weight loss. Physical examination revealed a large round mass of about 2-3 cm in the regions of the posterior abdomen. Radiographic examination confirmed the presence of a round mass which appeared to be associated with the uterus. At necropsy an irregular relatively firm single intramural mass of 2 to 3 cm diameter was detected in the mid-portion of the left horn of the uterus. Metastases were present in the lungs, thoracic pleura, diaphragm and mesenterium. The diagnosis of uterine fibrosarcoma was based on the histological mesenchymal spindle cell appearance of the tumor cells and the results of the immunohistochemical findings. Based on the negative results of Smooth Muscle Actin (SMA) antigen for the tumor cells, a final diagnosis of fibrosarcoma was made. To the best knowledge of the authors this is the first diagnosis of a spontaneous uterine fibrosarcoma in a cat without signs of uterine inflammation or pyometra and with widespread metastases.

Keywords: Feline, uterus, neoplasm, fibrosarcoma, immunohistochemistry.

INTRODUCTION

Feline uterine neoplasms are rare accounting for 0.29% of feline neoplasms (1). Adenocarcinomas and leiomyomas being the most commonly reported feline uterine neoplasms (1-3). The reported mean age of cats with uterine neoplasia is 9.4 years with a range of 5 to 12 years of age (3). The present report describes the clinical, pathological, histopathological and immunohistochemical findings of a uterine fibrosarcoma in a 15 year old Himalayan cat.

CASE REPORT

A 15 year old Himalayan female cat was presented to the clinic with a history of uterine hemorrhage and body weight

loss. She was an indoor cat, fed dry cat food and was adequately vaccinated. No details were available regarding her estrus cycles although exogenous progesterones had not been administered.

On physical examination a large round mass of about 2-3 cm was palpated in the region of the posterior abdomen. Radiographic examination revealed a round mass which appeared to be associated with the uterus (Figure 1).

A tentative diagnosis of uterine neoplasia was made based on the history of uterine bloody discharge, abdominal palpation of a mass, loss of weight and the radiographic examination. Due to the age of the cat and the poor prognosis the owner requested euthanasia.

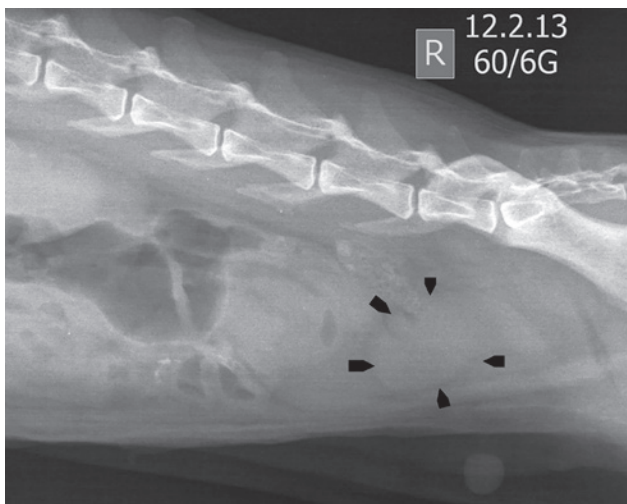


Figure 1: Radiograph. Lateral radiograph. Note the large pelvic irregular well-defined soft tissue opacity in the pelvic cavity as indicated by the black arrow heads.

Gross pathology

At necropsy an irregular firm single intramural mass of 2 to 3 cm diameter was detected in the proximal portion of the left horn of the uterus (Figure 2). On cut surface the tumor was firm and white in color. The left horn of the uterus distal to the tumor was wider in diameter compared to the right horn (Figure 3). Two smaller tumors were present in the body of the uterus. Small round white multiple tumor masses were present on the uterine ligament both on both sides of the uterus. Multifocal 0.5 to 1 cm diameter coalescing firm masses were present throughout the omentum (Figure 4).

Multiple similarly sized protruding nodules of about 1 cm were present bilaterally throughout the pulmonary parenchyma (Figure 5). The diaphragm and the pleura showed the presence of multiple transpleural disseminated tumors of similar appearance to those present in the lungs.

Samples of all organs were taken for histopathology. Following fixation in 10% neutral buffered formalin tissues were embedded in paraffin, sectioned at 3 μ m and stained with hematoxylin and eosin (H&E).

Histological examination

The neoplastic cells of uterine origin were of a mesenchymal appearance. The cellularity of the tumor masses ranged from densely packed spindle cell arrangements in interwoven short fascicles to loosely spaced spindle cells separated by variable amounts of eosinophilic matrix (Figures 6 and 7).

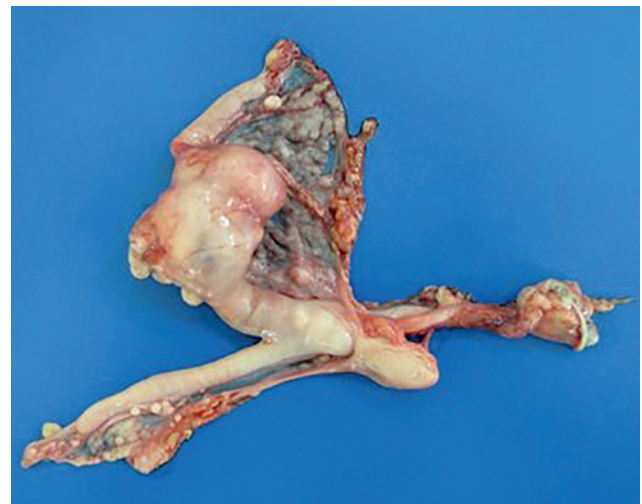

Figure 2: Uterus; cat. An irregular intramural mass in the mid-portion of the left horn which is wider in diameter. Small round white multiple tumor masses are present on the uterine ligaments.

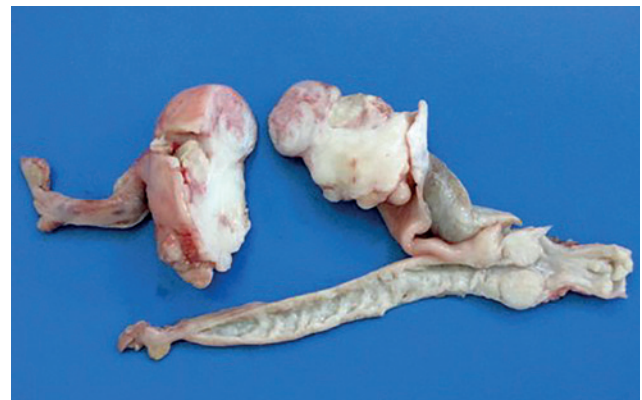

Figure 3: Uterus: cat. Cut surface of the tumor reveals that the mass is almost completely obstructing the uterine lumen.

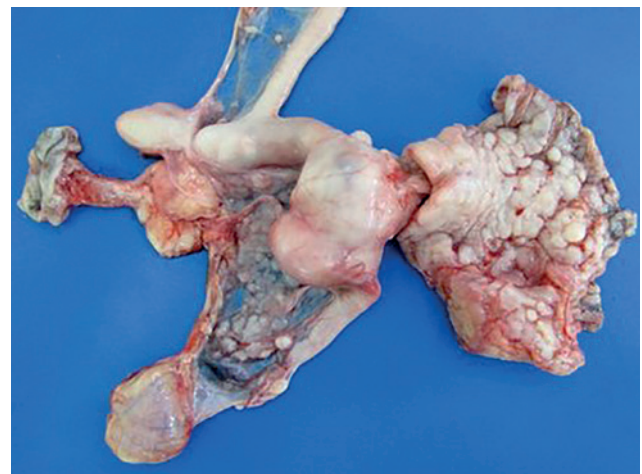


Figure 4: Uterus: cat. Multifocal coalescing tumor masses in the mesenterium and uterine ligaments.

Unencapsulated poorly demarcated masses in the myometrium were seen infiltrating and invading the endometrium and myometrium. In the region of the tumor most of the endometrial glands were compressed or replaced by tumour cells and some were dilated resulting in cysts (Figure 6). Cells had scant amounts of eosinophilic cytoplasm with occasional small clear cytoplasmic vacuoles and a large central cigar-shaped nucleus. There was a marked nuclear atypia with karyomegaly and some multinuclear giant cells. The mitotic index ranges from 1 to 5 per high power field.

Neoplastic cells similar to those present in the uterus invaded the diaphragm displacing muscle fibers (Figure 9).

Tumor masses of cells similar in appearance to the neo-

plastic cells present in the uterus were present throughout the lung parenchyma replacing alveoli and compressing others in their proximity (Figure 8).

The liver exhibited normal architecture without any evidence of tumor metastases.

Immunohistochemistry

Immunohistochemistry for smooth muscle actin (SMA) was carried out by the Diagnostic Center for Population and Animal Health, Michigan State University, USA. The uterine neoplastic tissue was found negative for SMA although bundles of adjacent normal smooth muscle cells had cytoplasmic diffuse immune labeling.

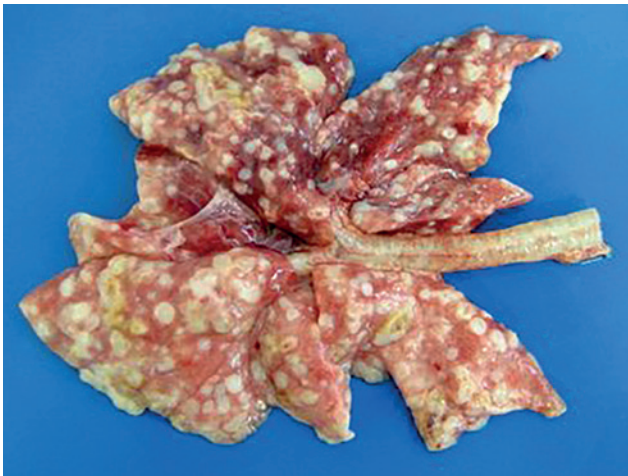

Figure 5: Lung: cat. Multifocal similarly sized metastasized nodules of about 0.3 to 1 cm are present throughout all the lung lobes of the pulmonary parenchyma.

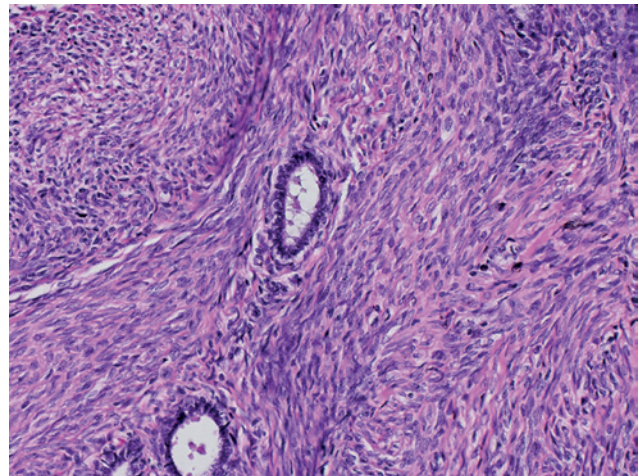


Figure 7: Uterus: cat. Fibrosarcoma. Note nuclear atypia and karyomegaly ($\times 20$, H&E).

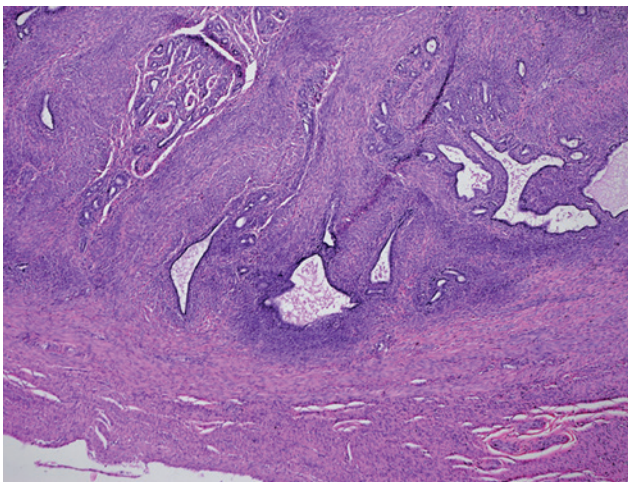


Figure 6: Uterus: cat. Fibrosarcoma. Proliferating mesenchymal cells are seen infiltrating and invading the endometrium with most glands compress and some dilated ($\times 4$, H&E).

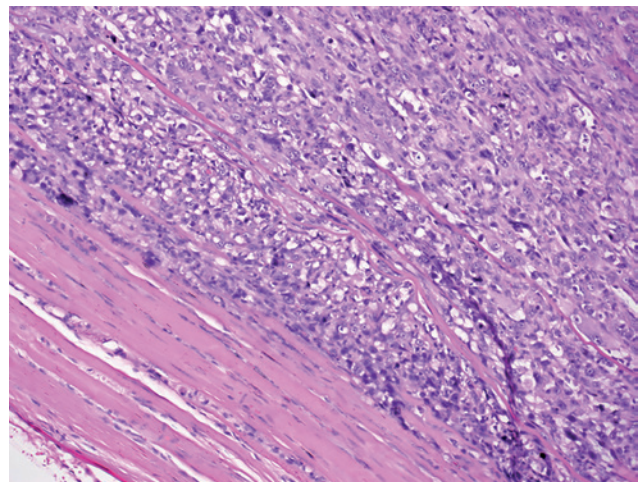


Figure 8: Diaphragm: cat. Neoplastic cells infiltrating the diaphragm displacing muscle fibers ($\times 10$, H&E).

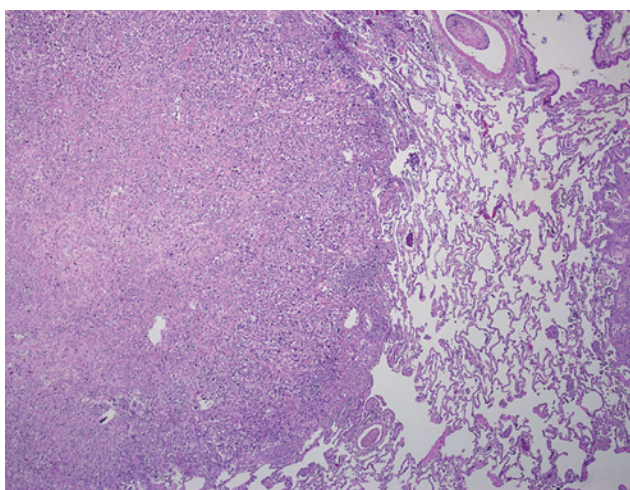


Figure 9: Lung: cat. Metastatic tumor mass composed of densely packed spindle cells replacing the normal lung parenchyma and compressing the alveoli. in their proximity ($\times 4$, H&E).

A diagnosis of a uterine fibrosarcoma was made based on the histological spindle cell appearance of the tumor cells and the results of the immunohistochemical findings. The tumor cells had a mesenchymal appearance which was judged to be either a leiomyosarcoma or a fibrosarcoma. Based on the negative results of Smooth Muscle Actin antigen for the tumor cells, a final diagnosis of fibrosarcoma was made.

DISCUSSION

The choice of immunohistochemical testing with SMA was based on the need for a specific marker for smooth muscle cells. It was decided that based on the histological appearance of the cells a lack of smooth muscle antigen would be strongly indicative of a fibrosarcoma. Evidence of the specificity of SMA for feline smooth muscle was found in a number of studies: A study on an endometrial stromal sarcoma in a feline uterus has shown that smooth muscle cells in the myometrium of cats reacted to desmin, SMA and caldeson antibodies (4). A study on a uterine myxoid leiomyosarcoma in a cat demonstrated that both caldesmona and SMA were expressed by this tumor (2). Furthermore, bundles of adjacent normal smooth muscle cells showed cytoplasmic diffuse immune labeling further strengthening the specificity of this immunohistochemical biolabel.

Uterine tumors in domestic animals are uncommon, leiomyoma in cows and bitches and uterine carcinomas in cows being more frequent (5). Among cats endometrial adenocarcinoma was reported as the most common tumor in one study (1) while leiomyoma was a common feline uterine tumor in other reports (6, 7). The low in-

cidence of uterine tumors of cats may also be attributed to common practice of spaying cats at an early age (1, 8). Other uterine tumors reported in the literature include squamous cell carcinoma, mixed Mullerian tumor, leiomyosarcoma, endothelioma, hemangioma, fibroadenoma, cystadenoma and submucosal fibroma (1).

Fibrosarcoma is a rare tumor both in humans (Bodner-Adler) and domestic animals (5, 9). The uterine form of the tumor has been described in a warm blooded mare (10), in a donkey mare, and in cows and dogs (5).

In the case of the warmblood 18 year old mare, it was presented with vaginal hemorrhagic discharge since her previous foaling with blood fluid accumulation in the uterus. At necropsy, multiple exophytic to pedunculated masses were present scattered on the mucosal surface of both horns. The tumor had metastasized to the liver, spleen and lungs. On immunohistochemistry a diffuse vimentin expression was demonstrated in the tumor cells.

The factors leading to the development of uterine neoplasia in all species and in cats are unknown. Cats are induced ovulators and may be subjected to long periods of estrogen stimulation which has been suggested to play a role in the development of endometrial adenocarcinoma (11). In a study of 9 cases of feline adenocarcinomas about half of them had cells positive for estrogen receptors by immunohistochemistry. However, tumors cells with marked nuclear atypia and those which metastasized usually did not express estrogen receptors. The authors suggested that the loss of expression of the estrogen receptors in these tumors may indicate a worse prognosis (12). The risk factors for other forms of uterine tumors are unknown (3).

Other possible etiological factors considered included feline leukemia virus: Although antibodies to feline leukemia virus were not investigated, the advanced age of the cat and the solitary nature of the tumor tended to exclude this possibility (13). The location of the tumor also precluded the possibility of postvaccinal sarcoma which could not have possibly been at the site of vaccination and which has a low metastatic potential compared to the present tumor which metastasized aggressively to the lungs and serosal surfaces (14).

Spontaneous feline fibrosarcomas are considered as rare and have not been associated with a vaccination site (15-18). Two studies have documented chromosomal alterations in feline fibrosarcomas which have been proposed to play a role in the etiology of the tumor (19, 20). No conclusions can be drawn regarding the present case of uterine fibrosarcoma

as no chromosomal studies were carried out, although this should be recognized as a potential etiology for this type of tumor.

The widespread metastases of this tumor are indicative of its degree of severe malignancy. Histologically the relatively high mitotic index along with the nuclear atypia and kariomegaly of the neoplastic cells substantiates the malignant nature of the tumor. The presence of multinucleate giant cells also been documented in the case of a spontaneous fibrosarcoma in an 8 year old female cat with a long-standing pyometra (21). Whether this is a characteristic of uterine fibrosarcomas in cat is not clear and will require the documentation of more cases of this rare tumor.

Feline postvaccinal sarcoma is a malignant tumor of fibrous connective tissue with a low metastatic rate, but a high rate of local reoccurrence (22). In general with the exception of lymphosarcoma, secondary neoplasia for the tubular genitalia is considered to be rare (23). In this case in addition to the metastatic tumors seen, serosal implantation was also very prominent, a further indication of the tumor's malignant potential.

To the best knowledge of the authors this is the first diagnosis of a spontaneous uterine fibrosarcoma in a cat without signs of uterine inflammation or pyometra and with widespread metastases. One case of a spontaneous fibrosarcoma in an 8 year old female cat with a long-standing pyometra has been described (21). In this case the tumor tissue consisted of polymorphous cells of mesenchymal character arranged in nodular formation or mutually crossing bands arranged in cartwheel or storiform structures. Multinuclear cells were present. No mention of the breed of the cat or the presence of any metastasizes was mentioned in the report. Another report of a uterine sarcoma describes a rare endometrial stromal sarcoma in a 12 year old domestic queen in which featured smooth muscle and glandular differentiation (4). These features differentiate the endometrial stromal sarcoma from the fibrosarcoma seen in the case reported here.

REFERENCES

1. Miller, M.A., Ramos-Vara, J.A., Dickerson, M.F., Johnson, G.C., Pace, L.W., Kreeger, J.M., Turnquist, S.E. and Turk, J.R.: Uterine neoplasia in 13 cats. *J. Vet. Diagn. Invest.* 15: 515-522, 2003.
2. Cooper, T.K., Ronnett, B.M., Ruben, D.S. and Zink, M.C.: Uterine myxoid leiomyosarcoma with widespread metastases in a cat. *Vet. Pathol.* 43: 552-556, 2006.
3. Sontas, B.H., Erdogan, O., Apaydin Enginler, S.O., Yilmaz, O.T., Sennazli, G. and Ekici, H.: Endometrial adenocarcinoma in two young queens. *J. Small Anim. Pract.* 54: 156-159, 2013.
4. Sato, T., Maeda, H., Suzuki, A., Shibuya, H., Sakata, A. and Shirai, W.: Endometrial stromal sarcoma with smooth muscle and glandular differentiation of the feline uterus. *Vet. Pathol.* 44: 379-382, 2007.
5. Baba, A.I. and Catoi, C.: Female genital tract tumors, in *Comparative Oncology 2007*, The Publishing House of the Romanian Academy: Bucharest.
6. Carpenter, J.L., Andrews, L.K. and Holzworth, J.: Tumors and tumor-like lesions, in *Diseases of the cat: medicine and surgery*, J. Holzworth, Editor 1987, WB Saunders: Philadelphia. pp. 406-596.
7. Gilmore, C.E.: Tumors of the female reproductive tract. *Calif. Vet.* 19: 12-15, 1965.
8. Nicotina, P.A., Zanghi, A. and Catone, G.: Uterine malignant mixed Mullerian tumor (Metaplastic carcinoma) in the cat: clinicopathologic features and proliferation indices. *Vet. Pathol.* 39: 158-160, 2002.
9. McEntee, K. and Nielsen, S.W.: Tumours of the female genital tract. *Bull. World Health Organ.* 53: 217-226, 1976.
10. Govaere, J., Maes, S., Saey, V., Blancke, W., Hoogwijs, M., Deschawwer, C., Smits, K., Roels, K., Vercauteren, G. and de Kruijf, A.: Uterine fibrosarcoma in a warmblood mare. *Reprod. Dom. Anim.* 46: 546-566, 2011.
11. Cho, S.J., Lee, H.A., Hong, S. and Kim, O.: Uterine adenocarcinoma with feline leukemia virus infection. *Lab. Anim. Res.* 27: 347-351, 2011.
12. Clement, P.B., Zubovits, J.T., Young, R.H. and Scully, R.E.: Malignant mullerian mixed tumors of the uterine cervix: a report of nine cases of a neoplasm with morphology often different from its counterpart in the corpus. *Int. J. Gynecol. Pathol.* 17: 211-222, 1998.
13. Harasen, G.L.G.: Multicentric fibrosarcoma in a cat and a review of the literature. *Can. Vet. J.* 25: 207-210, 1984.
14. Wilcock, B., Wilcock, A. and Bottoms, K.: Feline postvaccinal sarcoma: 20 years later. *Can. Vet. J.* 53: 430-434, 2012.
15. Gruffydd-Jones, T.J. and Sparkes, A.H.: Vaccination and fibrosarcomas in cats. *Vet. Rec.* 134: 310, 1994.
16. Gemmill, L.T., Jr.: Injection-site sarcomas in cats. *J. Am. Vet. Med. Assoc.* 213: 955, 1998.
17. Gemmill, L.T.: The issue of injection site sarcomas. *J. Am. Vet. Med. Assoc.* 210: 889-890, 1997.
18. Esplin, D.G., McGill, L.D., Meininger, A.C. and Wilson, S.R.: Postvaccination sarcomas in cats. *J. Am. Vet. Med. Assoc.* 202: 1245-1247, 1993.
19. Nande, R., Di Benedetto, A., Aimola, P., De Carlo, F., Carper, M., Claudio, C.D., Denvir, J., Valluri, J., Duncan, G.C. and Claudio, P.P.: Targeting a newly established spontaneous feline fibrosarcoma cell line by gene transfer. *PLoS One.* 7: e37743, 2012.
20. Santos, S., Chaves, R., Atega, F., Bastos, E. and Guedes-Pinto, H.: Amplification of the major satellite DNA family (FA-SAT) in a cat fibrosarcoma might be related to chromosomal instability. *J. Hered.* 97: 114-118, 2006.
21. Jelinek, F.: Postinflammatory sarcoma in cats. *Exp. Toxicol. Pathol.* 55: 167-172, 2003.
22. Basinger, R.R.: Feline squamous cell carcinoma and feline sarcoma. in *Atlantic Coast Veterinary Conference*. 2004.
23. Schlafer, D.H. and Miller, R.B.: Female Genital System, in *Jubb, Kennedy and Palmer's Pathology of Domestic Animals*, Maxi, M.G., Ed., Saunders Elsevier, Edinburgh, 2007.