

OPHTHALMIC AND CUTANEOUS HABRONEMIASIS IN A HORSE: CASE REPORT AND REVIEW OF THE LITERATURE

Yarmut Y., Brommer H., Weisler S., Shelah M., Komarovsky O., and Steinman A*.

^a Koret School of Veterinary Medicine, Faculty of Agricultural, Food and Environmental Quality Sciences, The Hebrew University of Jerusalem, P.O. Box 12, Rehovot 76100, Israel.

^b Department of Equine Sciences, Faculty of Veterinary Medicine, Utrecht University, Yalelaan 114, NL-3584 CM, Utrecht, The Netherlands.

^c Kfar Shmuel 13, 99788, Israel.

* Corresponding author. A. Steinman Tel.: +972-54-8820-516; Fax: +972-3-9604-079. E-mail address: Steinman@agri.huji.huji.ac.il

INTRODUCTION

Habronemiasis is a parasitic disease of equids (horses, donkeys, mules and zebras) caused by the nematodes *Habronema musca*, *H. majus* and *Draschia microstoma* (1, 2). The adult worms live on the wall of the stomach of the host without internal migration. Embryonated eggs are excreted in the feces to the environment where they are ingested by the larvae of intermediate hosts, such as houseflies and stable flies. Most cases of gastric habronemiasis do not show clinical signs (3), however heavy worm infestation can result in gastric perforation (4). Development of the parasite is synchronous with the development of the intermediate host, and infectious larvae (L3) are deposited on the host when the flies are feeding. When a fly lands near the horse's lips, the L3 is liberated and is swallowed by the horse, resulting in completion of its life cycle (5). Larvae which are deposited on mucous membranes or on injured tissue will not complete their life cycle but will induce a local inflammatory reaction causing cutaneous ("summer sores") and/or ophthalmic habronemiasis (2).

The cutaneous type of habronemiasis, "summer sore", is often seen in areas of the world with a tropical or temperate climate (1, 3). However, little is known about the prevalence of the disease mainly because of diagnostic limitations (1, 2). Clinical diagnosis is unreliable as there is a range of equine skin diseases that should be considered as differential diagnoses. These include proliferative granulation tissue, sarcoids, squamous cell carcinoma, fungal granulomas, pyogranulomas and foreign body granulomas. Differential diagnoses for ophthalmic habronemiasis include ocular neoplasia, foreign body granuloma, ocular onchocerciasis and phycomycosis (5, 6). Confirmation of the clinical diagnosis should be performed by histopathology to identify the larvae.

In this report a case of ophthalmic and cutaneous habronemiasis in a horse in Israel is described with special attention to confirmation of the clinical diagnosis, surgical treatment and aftercare.

Clinical details

History:

A 4 year old 600 kg warm-blood, cross gelding was referred to the Koret School of Veterinary Medicine, Veterinary Teaching

Hospital (KSVM-VTH). The horse presented skin lesions around the medial canthus of the right eye and on the lateral bulb of the heel of the right front leg. The lesions were first noticed 3 weeks previously and the referring veterinarian had suspected habronemiasis. The horse was treated with ivermectin 1.87 % *per os* (Eqvalan Veterinary® 200 µg/kg, Merial B.V., Haarlem, Netherlands), and dexamethasone intramuscularly (Dexacort Forte®, 20 mg/ml Teva Pharmaceut. Works Private Ltd. Co, Hungary), twice every second day. This treatment was repeated 3 times with a seven days interval between treatments. A dose of 30 ml penicillin-streptomycin (Pen-Strep 20/25 Veterinary®, 200/250 mg/ml respectively, Eurovet Animal Health B.V., Netherlands) was given intramuscularly 2 days before the horse was referred to the KSVM-VTH. In addition, the referring veterinarian performed two minor surgical procedures under sedation for debridement of the lesions. Following these procedures, the lesion around the eye continued to expand, and it was decided to refer the horse for further diagnosis and treatment.

The horse was routinely vaccinated against tetanus and rabies and the last deworming before the current treatment, was performed one year previously.

Clinical examination

An ulcerative lesion was present around the medial canthus and around the puncta lacrimalia of the right eye (Fig 1). The lesion had a bloody and purulent discharge and contained numerous caseous granules. The ventral eyelid was swollen and painful. Ophthalmic examination revealed no pathological changes of the eyeball itself, but there was an evident purulent discharge. A few minor skin granulomatous lesions were noted above the dorsal eyelid, and an ulcerative lesion was visible on the lateral bulb of the heel of the right front leg above the coronary band with bloody and purulent discharge and evident edema. The horse showed some pain at palpation and was 1/5 lame (defined as mild lameness observed while the horse is trotted in a straight line. Also, when the lame forelimb strikes a subtle head nod was observed, which may be inconsistent at times) (7). A small granulomatous lesion was also noted on the skin on the right hind leg at the region of the M. semitendinosus. No further abnormalities were found on physical examination.

Clinical pathology

Cytologic examination of a direct smear taken from the lesion around the medial canthus of the eye showed eosinophilia. A complete blood count (CBC) and biochemical analysis were not performed. Packed cell volume (PCV) was 26% (reference range 32-52%), total solids (TS) was 7 g/dl (reference range 5.7-7.9 g/dl), and serum urea was 42 mg/dl (reference 10-40 mg/dl).

Case management

The presence of eosinophils in the direct smear and the location of the lesion supported the suspicion of habronemiasis. Due to the risk of deterioration and damage to the eye it was decided to perform an extensive debridement under general anesthesia rather than treating it medically.

Surgery

Preoperatively, the horse was given intravenously 10 m.u. penicillin sodium (Penicillin G sodium 10 m.u.®, 10 m.u./vial, Sandoz GmbH, Austria), 4 gr gentamycin (Gentaveto-5 Veterinary® 50 mg/ml, V.M.D. N.V., Belgium) and 600 mg flunixin meglumine (Flunixin Veterinary®, 50 mg/ml, Norbrook Laboratories Ltd, Ireland). Following these pre-operative medications, the horse was sedated intravenously with 1000 mg xylazine (Chanazine®, 100 mg/ml, Chanelle Pharm. Manufacturing Ltd., Ireland) and subsequently induced with 2000 mg ketamine (Ketaset®, 100 mg/ml, Fort Dodge laboratories, USA) and 20 mg diazepam (Assival®, 10 ml/2 ml, Teva Pharmaceut. Works Private Ltd. Co, Hungary). The horse was positioned in left lateral recumbency, anaesthesia was maintained with isoflurane (100%, Nicolas Piramal (I) Ltd., UK) and 10 ml/kg/h of intravenous lactated Ringer's solution was given. A catheter was inserted into the orifice of the nasolacrimal duct in the right nostril in order to flush the duct daily after surgery with the aim to keep the puncta lacrimalia patent during wound healing. An extensive debridement of the lesion around the medial canthus of the right eye was performed. Electrocautery was used to stop haemorrhage and after debridement, a stent was sutured over the debrided lesion using nylon 0 (Monosof®, Nylon (Polyamide), Tyco Healthcare Group LP, USA) in a Lembert pattern to control and prevent bleeding. One skin lesion on the ventral eyelid, two skin lesions on the dorsal eyelid, and the lesion in the area of the M. semitendinosus were excised. The wounds were closed with nylon 2/0 (Monosof®) to achieve primary intention wound healing. Debridement was also performed on the lesion on the bulb of heel of the right front hoof, proximal to the coronary band. The hoof was bandaged to control and prevent the bleeding. Samples from the lesion of the eye, hoof and hind leg were sent for histopathology.

Anesthesia was uneventful and the horse recovered well.

Post-operative process

Benzylpenicillin sodium at a dose of 10 m.u. four-times a day and gentamycin at a dose of 4 gr once a day were administered intravenously for 3 days, and 300 mg flunixin meglumine was administered intravenously twice a day for 2 days. The horse was also treated with hydrocortisone acetate 1.5% and neomycin sulphate 0.5% ophthalmic ointment (Hycocine®, Rekah Pharm.

Ind. Ltd., Holon, Israel) for 10 days. After the cessation of the intravenous administration of flunixin meglumine the horse was treated orally twice a day with 1gr phenylbutazone (Vetmarket Marketing Ltd.) for 2 weeks. The nasolacrimal catheter was flushed daily with sterile isotonic saline. The stent bandage was removed after three days and the hoof bandage was changed every three days.

The horse was discharged 12 days post-operatively. The skin sutures were removed and the wounds were healed by primary intention. The lesions around the medial canthus of the eye and at the lateral heel bulb of the hoof showed progress of healing by secondary intention with a normal aspect of the granulation tissue. The horse did not show any lameness at the time of discharge from the hospital.

Histopathology and confirmation of the clinical diagnosis

The lesion adjacent to the eye revealed extensive epidermal erosion and focal ulceration with dermal necrosis and evident bacterial colonies. There was diffuse and heavy dermal infiltration of numerous eosinophils and fewer neutrophils. A small cross-section of a degenerating larva was also seen (Fig 2). The lesion on the hind leg revealed similar findings, except that larvae were not seen.

The lesion on the front leg revealed epidermal hyperplasia with hyperkeratosis and extensive ulceration, moderate to marked fibrosis and diffuse eosinophilic infiltration.

The lesion above the eye revealed irregular, epidermal hyperplasia and mild perivascular eosinophilic infiltration.

The lesions near the eye and on the hind leg were compatible with *Habronema* infestation. Severe eosinophilic dermatitis was seen in the sample collected from the right front leg, which might be the result of larval infection. The lesion above the eye may represent a hypersensitivity reaction against an unidentified agent, but which is probably also *Habronema* considering the histopathology of the other lesions.

Follow up

One month after discharge from the hospital, the wound around the eye had healed but there was some degree of ectropion due to contraction of the scar (Fig 3). The lesion in the hoof had resolved.

DISCUSSION

In this report, a confirmed case of ophthalmic and cutaneous habronemiasis in a horse has been described. Previously, a number of similar cases were suspected and treated accordingly by veterinarians clinicians (Haik R. personal communication), but most cases were not confirmed by histopathology.

Common sites for infestation by *Habronema* larvae are limbs, ventral aspect of the abdomen, prepuce, external genitalia in males (penis, urethral process), ocular and peri-ocular areas (conjunctiva, medial canthus, nasolacrimal duct) and commissure of the lips (3,5). In a study conducted in 18 horse farms in Israel 20 years ago, the prevalence of gastric habronemiasis was 5.6% (8). The prevalence of habronemiasis justifies the need to include it in the differential diagnosis of lesions on these body parts.

A retrospective study was performed at Davis Veterinary Teaching Hospital on 63 horses diagnosed with ocular or cutaneous habronemiasis to identify epidemiological features of the disease (5). According to this study Arabians were overrepresented, Thoroughbreds were underrepresented, no sex predisposition was noticed, the median age was 7.3 years, and none of the horses was less than 1 year old. Of the 63 horses, only 8 had recurrent infections in the following years.

In Western Europe, cutaneous habronemiasis has not been reported so far (3). However, the occurrence of gastric habronemiasis has been reported in a number of surveys. In Sweden 1.2% of 461 horses were found positive (9), in France 8.5% of 410 horses were found positive (10) and in Belgium 55% of 11 ponies were reportedly positive (11).

The exact pathogenesis of habronemiasis is unknown but it is highly probable that the disease involves a hypersensitive reaction to dead or dying larvae because of the eosinophilia seen in direct smears and in histopathological sections. The lesions usually appear during spring and summer, probably related to a high fly activity, and regress in wintertime. Although it is a rather sporadic disease, certain horses show an annual recurrence (2, 5). Diagnosis is challenging, but based on the history, clinical signs and location of the lesions, habronemiasis should be diagnosed. Histopathological examination of a biopsy, although less sensitive, is currently the method of choice for confirming the diagnosis. Characteristic histological lesions consist of eosinophilic dermatitis and coagulative necrosis with or without degeneration of nematode larvae in the centre, as was seen in this case, and as reported previously (2,5). Molecular diagnosis is being developed, but is not commercially available yet. A PCR assay has been reported for the diagnosis of gastric habronemiasis (1, 12), cutaneous habronemiasis (2), and in epidemiological studies (13).

Many treatments for habronemiasis have been reported, including corticosteroids for reducing the inflammatory hypersensitivity reactions (5). Ivermectin has been used to kill the larvae and the adult worms in the stomach (5, 14). Topical combinations of anti-inflammatory, larvicidal, and antimicrobial ingredients are also recommended (5). In cases of lesions refractory to medical treatment, surgical intervention is indicated, as has been described for the horse in this report. Once surgery is indicated, extensive debridement should be performed since superficial debridement will usually be insufficient, leading to progression of the condition which is probably related to persistence of degenerated larvae in the lesion. Fly control, proper removal and disposal of manure and protecting existing wounds are essential for reduction of incidence and prevention of recurrence of habronemiasis (3, 5, 6).

This case report confirms the presence of the cutaneous and ophthalmic forms of habronemiasis in Israel. Thus habronemiasis should be included in the differential diagnosis when encountering typical lesions. The clinical diagnosis should be then confirmed and treated accordingly as described here. Studies to assess the current prevalence of *Habronema* spp are required in Israel to evaluate its significance.

REFERENCES:

1. Giangaspero, A., Traversa, D. and Otranto, D.: A new tool for the diagnosis in vivo of habronemiasis in horses. *Equine vet. J.* 37: 263-264, 2005.
2. Traversa, D., Iorio, R., Petrizzi, L., De Amicis, I., Brandt, S., Meana, A., Giangaspero, A. and Otranto, D.: Molecular diagnosis of equid summer sores. *Vet. Parasitol.* 150: 116-121, 2007.
3. Gasthuys, F. M. R., Van Heerden, M. and Vercruysse, J.: Conjunctival habronemiasis in a horse in Belgium. *Vet. Rec.* 154: 757-758, 2004.
4. Nadalian, M. Gh., Hosseini, S. H., Tavassoli, A. and Raoufi, A.: Gastritis and gastric perforation due to *habronema* spp. in the horse. *J. Equine Vet. Sci.* 17: 385-386, 1997.
5. Pusterla, N., Watson, J. L., Wilson, W. D., Affolter, V. K. and Spier, S. J.: Cutaneous and ocular habronemiasis in horses: 63 cases (1988-2002). *J. Am. Vet. Med. Assoc.* 222, 978-982, 2003.
6. Rebhun, W. C., Mirro, E. J., Georgi, M. E. and Kern, T. J.: Habronemic Blepharconjunctivitis in horses. *J. Am. Vet. Med. Assoc.* 179: 469-472, 1981
7. Ross, M. W.: Movement. In: Ross, M. W. and Dyson, S. J. (Eds.): *Diagnosis and management of lameness in the horse.* Saunders, Philadelphia, pp. 60-73, 2003.
8. Sharir, B., Pipano, E., Markovics, A. and Danieli, Y.: Field studies on gastro-intestinal infestation in Israeli horses. *Isr. J. Vet. Med.* 43: 223-227, 1987.
9. Hoglund J., Ljungstrom, B. L., Nilsson, O., Lundquist, H., Osterman, E. and Uggla, A.: Occurrence of *Gasterophilus intestinalis* and some parasitic nematodes of horses in Sweden. *Acta. Vet. Scand.* 38: 157-165, 1997.
10. Collobert-Laugier, C., Lamidey, C., Brisseau, N., Moussu, C. and Hamet, N.: Prevalence of stomach nematodes (*Habronema* spp, *Draschia megastoma* and *Trichostrongylus axei*) in horses examined post mortem in Normandy, *Revue de Medecine Veterinaire*, 151: 151-156, 2000.
11. Dorny, P., Eysker, M., Demeulenaere, D., Smets, K. and Vercruysse, J.: Study on the gastrointestinal metazoan parasite fauna of ponies in Belgium, *Vlaams Diergeneeskundig Tijdschrift*, 68:173-178, 1999.
12. Traversa, D., Giangaspero, A., Iorio, R., Otranto, D., Paoletti, B. and Gasser, R. B.: Semi-nested PCR for the specific detection of *Habronema microstoma* or *Habronema muscae* DNA in horse faeces. *Parasitology.* 129: 733-739, 2004.
13. Traversa, D., Iorio, R., Capelli, G., Paoletti, B., Bartolini, R., Otranto, D. and Giangaspero, A.: Molecular cross-sectional survey of gastric habronemiasis in horses. *Vet. Parasitol.* 141: 285-290, 2006.
14. Herd, R. P. and Donham, J. C.: Efficacy of Ivermectin against cutaneous *Draschia* and *Habronema* infection (summer sores) in horses. *Am. J. Vet. Res.* 42: 1953-1955, 1981.

Figure 1: Cutaneous and ophthalmic habronemiasis adjacent to the right eye of the horse on referral to the hospital. There is an ulcerated lesion along the nasolacrimal duct – from the medial canthus of the eye. It has progressed to a cutaneous lesion inferior to the ventral eyelid. In addition there are a few small ulcerated lesions dorsal and medial to the eye.

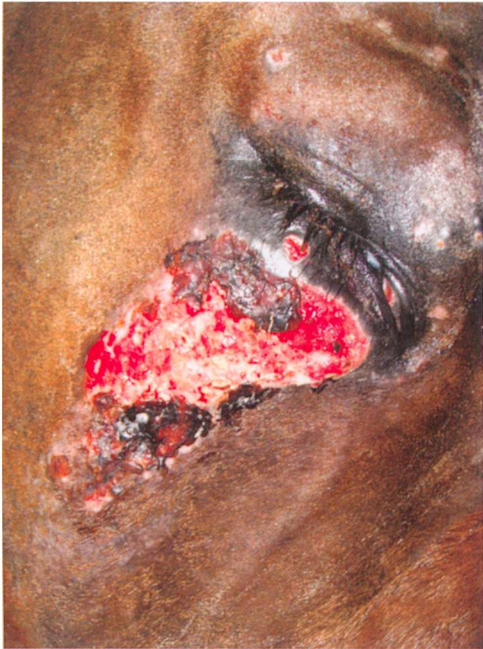

Figure 2: Histopathology of the lesion adjacent to the eye. There is dermal necrosis and diffuse and heavy dermal infiltration of numerous eosinophils and fewer neutrophils. A small cross-section through a degenerated larva of Habronema can be seen.

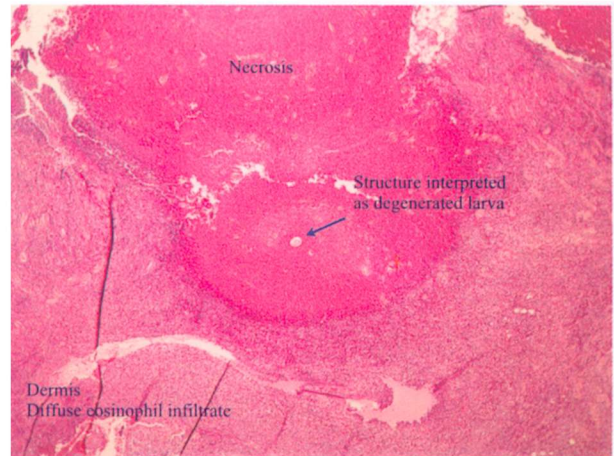


Figure 3: The right eye of the horse one month after discharge.

The lesion around the eye has healed and a small scar remains. There is some degree of ectropion due to contraction of the scar.

